

NON-SYNDROMIC MULTIPLE ODONTOGENIC KERATOCYSTS: report of case

Keratocistos múltiplos não-sindrômicos: relato de caso

Amar A. Sholapurkar¹, Reddy MallelaVarun², Keerthilatha M. Pai³, Geetha V⁴

¹ Assistant Professor, Department of Oral Medicine & Radiology, Manipal College of Dental Sciences, Manipal, Karnataka, India, e-mail: dr.amar1979@yahoo.co.in

² BDS, Manipal, Karnataka, India.

³ Professor and Head, Department of Oral Medicine and Radiology, Manipal College of Dental Sciences, Manipal, Karnataka, India.

⁴ Associate Professor, Department of General Pathology, Kasturba Medical College, Manipal, Karnataka, India.

Abstract

Odontogenic keratocysts (OKCs) are epithelial developmental cysts which were first described by Phillipsen in 1956. Lesions are frequently multiple and a component of Nevoid Basal Cell Carcinoma Syndrome (NBCCS) (Gorlin Goltz syndrome/Bifid rib syndrome). We hereby report a case of multiple OKCs in a non – syndromic patient and highlight the general practitioner the importance of diagnosing the disease and enforcing a strict long-term follow-up whenever such a case is identified.

Keywords: Multiple odontogenic keratocysts; Oral pathology; Gorlin Goltz syndrome.

Resumo

Os keratocistos odontogênicos são cistos de desenvolvimento que foram descritos primeiramente por Phillipsen, em 1956. As lesões são frequentemente múltiplas, sendo componentes da síndrome do carcinoma nevoide de células basais (síndrome de Gorlin, síndrome das costelas bífidas). Descreve-se um caso de keratocistos múltiplos em paciente não-sindrômico, enfatizando-se a importância do clínico geral no diagnóstico da doença e reforçando a necessidade de uma preservação a longo prazo tão logo a doença seja diagnosticada.

Palavras-chave: *Keratocistos odontogênicos múltiplos; Patologia bucal; síndrome de Gorlin-Gotz.*

INTRODUCTION

The maxillofacial region is more prone to cystic lesions than any other part of the body and OKCs are the most common form of cystic lesions affecting the maxillofacial region (1). They are clinically aggressive lesions which are thought to arise from the dental lamina or its remnants (2). OKCs constitute about 3% - 21.5% of odontogenic cysts. (3-7). The peak incidence is during the second to fourth decades of life (7-10). Several studies indicate a male predilection (4-5, 10-12), some studies do not correlate with this (1, 8, 9).

Majority of lesions occur in the mandible; mainly in the posterior body and ascending ramus. (5, 7-8). The angle (8) and symphyseal area is also frequently a locus for this lesion (13). The OKC can be very aggressive owing to its relatively high recurrence rate and its tendency to invade adjacent tissue (5).

Therapeutic approaches vary from marsupialization and enucleation, combined with adjuvant cryotherapy or chemical cautery or Carnoy's solution to marginal or radical resection (9, 10, 14-17). The recurrence rate has been reported to vary from 2.5% to 62.5% (5-8, 10, 14, 18,19). Malignant transformation of OKCs has also been reported (20). The high recurrence rate and aggressive behavior of the OKC have caused several investigators to regard it as a benign neoplasm rather than a cyst (7, 21).

We discuss the possibility that the current case is a non-syndromic presentation of multiple OKCs.

CASE REPORT

A 24 year old male patient was referred to our department with a chief complaint of swelling in the lower right side of the face since 3 years (Figure 1). The swelling was small initially which gradually increased to the present dimension which was progressive and was associated with pus discharge since 15 days. Patient initially consulted a local dentist, where drainage of pus was done and antibiotics prescribed, followed by partial regression of the swelling. The swelling was associated with pain with gradual onset, intermittent, pricking type, radiating to head on same side, aggravated when swelling appeared and relieved on medication. There was no history of fever. Nothing relevant was reported from medical history.

General examination revealed a swollen face (Figure 1) with depressed nasal bridge, hypertelorism, peripheral edema, sweating and non pitting pedal oedema of the left foot. Extra oral examination revealed a diffuse swelling on the lower right side of the face. There was no evidence of any abnormality of overlying skin (no evidence of sinus/fistula). Inspectory findings were confirmed on palpation and the swelling was tender and there was a slight rise in local temperature. Lymph node examination revealed an enlarged (measuring approximately about 2x2 cm in size) right submandibular lymph node which was mobile and non-tender.

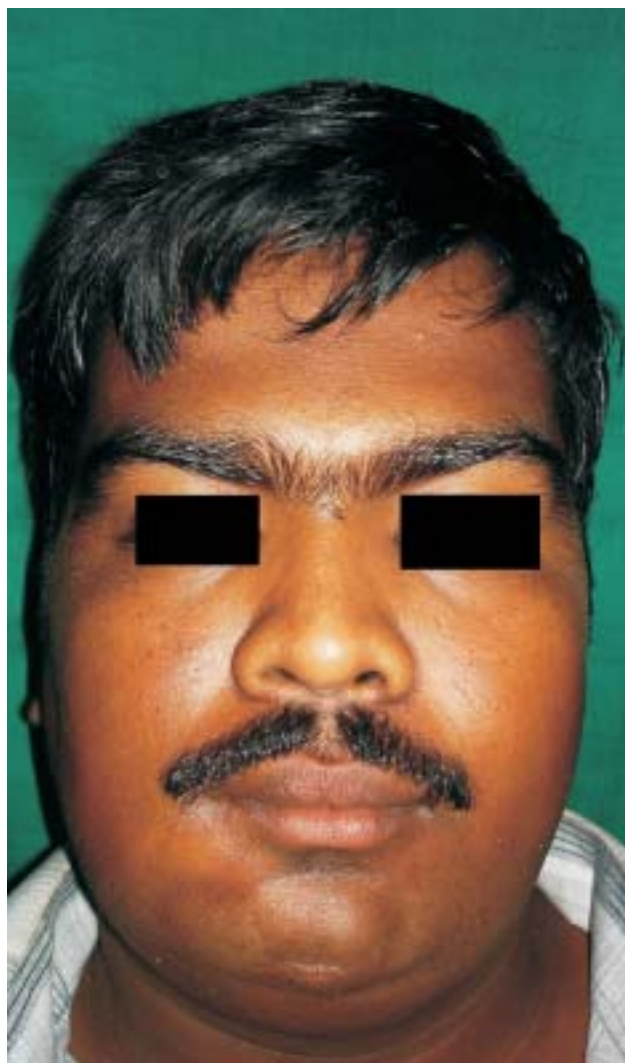


FIGURE 1 - Diffuse swelling on the lower right side of the face

Intraoral examination revealed a diffuse tender swelling in the right labial and buccal sulcus (Figure 2) extending approximately from 42 to 46 and obliterating the labial and buccal sulcus with obvious pus discharge observed in relation to the gingival sulcus related to 44. 18, 28 and 43 were not visible in the oral cavity.

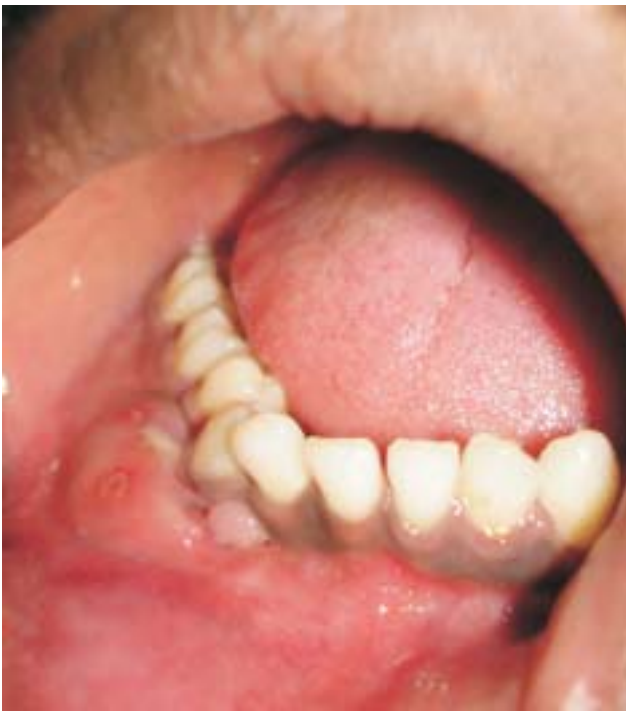

FIGURE 2 - Diffuse swelling in the right labial and buccal sulcus

Periapical radiograph of the region of the 43 (Figure 3) revealed a well defined radiolucency with well corticated margin in relation to the crown of impacted 43.

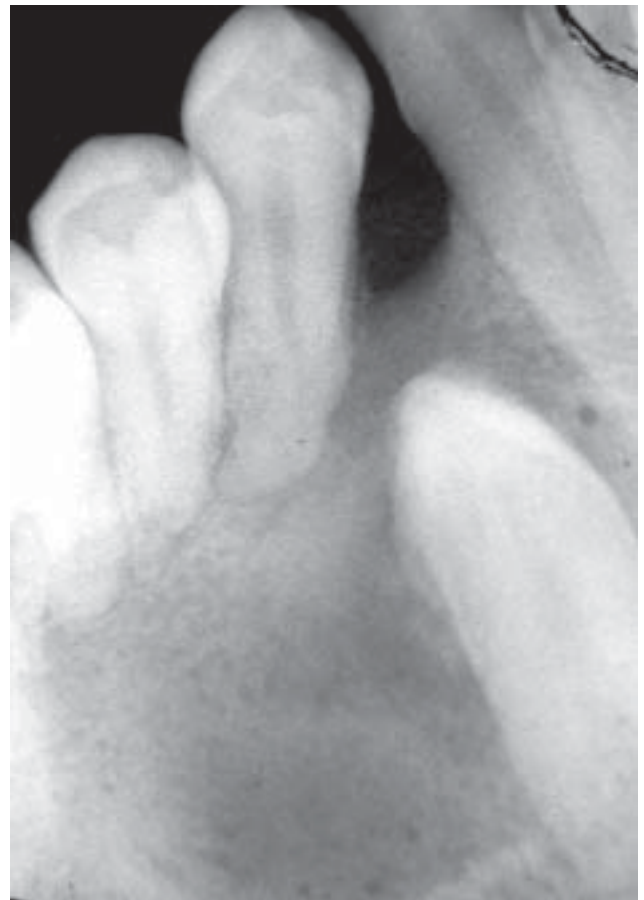

FIGURE 3 - Periapical radiograph revealing a well defined radiolucency in relation to the crown of the 43

Panoramic radiograph (Figure 4) revealed four cyst-like radiolucencies in upper and lower jaws.

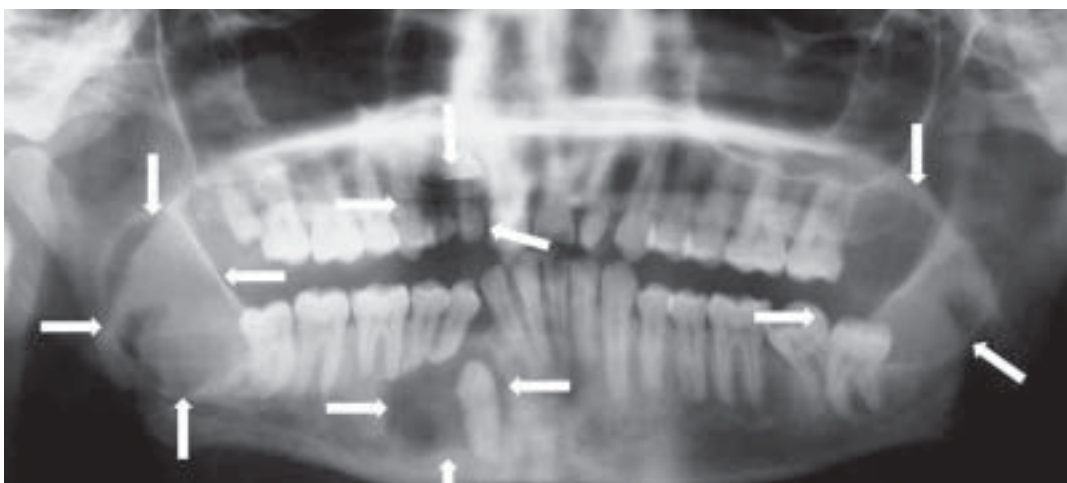

FIGURE 4 - Panoramic image showing four cyst-like radiolucencies in upper and lower jaws

Hence based on the history, clinical examination and imaging, a provisional diagnosis of infected dentigerous cyst in relation to 43 was made.

Unicystic ameloblastoma, adenomatoid odontogenic tumor and central giant cell granuloma were considered under differential diagnosis. Table 1 shows the differentiating features for those entities which were considered in our differential diagnosis.

TABLE 1 - Differentiating features for those entities which were considered in our differential diagnosis

	Gender	Peak age	Jaw involved	Area of jaw involved	Associated tooth	Signs or symptoms
Dentigerous cyst	M=F	Over 18 years	mandible	posterior	Mandibular 3rd molar	Delayed eruption of tooth, asymmetry, swelling
Unicystic Ameloblastoma	M=F 21 years	(average)	mandible	posterior	Mandibular 3rd molar	Delayed eruption of tooth, asymmetry, swelling
Adenomatoid Odontogenic Tumor	F:M2:1	(Average) 16.5 years	Maxilla	Anterior	Maxillary canine	Delayed eruption of tooth, asymmetry, swelling
Central giant cell granuloma	F:M2.4:1 26 years	(Average)	mandible first molar	Anterior to	—	History of previous trauma

Vitality test revealed that 44 was non-vital. Hence multiple OKC's in relation to 13, 38, 43 and 48 was considered under the radiographic imaging because the occurrence of multiple OKC's is more common than any other cysts.

The description of radiolucencies is shown in Table 2.

TABLE 2 - Description of the radiographic findings

Region	Radiographic Appearance	Approximate size (cm)	Effect on adjacent structures
Lower right anterior region in the pericoronal aspect of impacted canine	Well defined, with sclerotic border	3 x 2	It caused displacement of the lower right central incisor, lateral incisor and first premolar.
Right ramus of mandible in the pericoronal aspect of impacted 48	Well defined almost involving the whole of ramus, with well defined sclerotic border.	4 x 3	None
Pericoronal radiolucency was in relation to impacted 38 which was extending into the ramus	Well defined with sclerotic border which was comparatively smaller than the former	3 x 2	Displaced the mandibular canal downwards.
Pericoronal radiolucency in relation to upper right impacted canine	Well defined with sclerotic border	1 x 0.5	Caused resorption of the over retained deciduous canine

The patient was then referred to the department of General Medicine for evaluation. Nothing abnormal was detected on review of systems. However dermatologic consultation revealed acanthosis nigrans.

The patient was then referred to the department of Oral Surgery. Under general anesthesia, the lesions were enucleated under general anesthesia. During the surgery, white cheesy material was found extruding from the cystic lesion.

Microscopic examination revealed keratinized stratified squamous epithelium with absence of retepegs and palisaded basal cell layer giving an appearance of tombstone or picket fence (Figure 5).

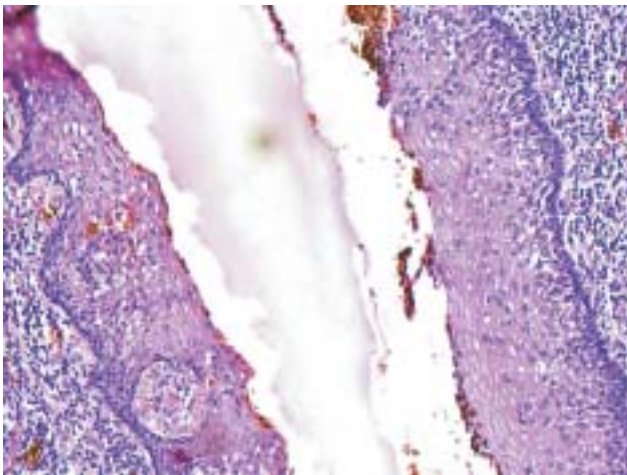


FIGURE 5 - Keratinized stratified squamous epithelium with absence of retepegs and palisaded basal cell layer giving an appearance of tombstone or picket fence (HE 100 X)

The connective tissue revealed multiple daughter cysts and cystic lumen revealed keratin giving a picture of odontogenic keratocyst.

DISCUSSION

Multiple OKCs commonly occur in NBCCS or Gorlin-Goltz syndrome (22), orofacial digital syndrome (23), Ehler-Danlos syndrome (24), Noonan syndrome (25) and Simpson-Golabi-Behmel syndrome (26). OKCs have a biologic behavior similar to a benign neoplasm (7, 21) and it is still debated whether the origin of OKC is developmental or neoplastic (27).

NBCCS is characterized by multiple OKCs, nevoid basal cell carcinomas of the skin, bifid ribs, calcification of the falx cerebri, and other features (28). OKCs, when associated with NBCCS, present together with skeletal, cutaneous, neurologic, ophthalmic and sexual abnormalities (29). However, these features were not present in our case.

Most frequent clinical manifestations at first admission were reported to be swelling, pain or both (8, 10). Our patient reported with both swelling and pain.

Radiographically, OKCs present as a well defined radiolucent lesions with smooth, usually corticated margins and may be either multilocular or unilocular. There is involvement of an unerupted tooth in 25% to 40% of cases (30). Our case complied with these findings, with all the detected radiolucencies being unilocular, having well corticated margins and being associated with an unerupted tooth.

Histologically, OKCs show the presence of a thin band-like parakeratinized or orthokeratinized stratified squamous epithelium, with a prominent basal layer of columnar or cuboidal cells, and an inflammation-free connective tissue wall (11-12). Microscopic examination in our case revealed orthokeratinized stratified squamous epithelium with absence of retepegs and palisaded basal cell layer giving an appearance of tombstone or picket fence. The connective tissue revealed multiple daughter cysts and cystic lumen revealed keratin giving a picture of odontogenic keratocyst.

Histopathological studies have suggested that parakeratinization, intramural epithelial remnants and satellite cysts are a more frequent observation among OKC's associated with NBCCS. (31). However, our case also presented with multiple daughter cysts even though it was non-syndromic.

Treatment modalities include marsupialization and enucleation, combined with adjuvant cryotherapy or chemical cautery or Carnoy's solution, and marginal or radical resection. Cryosurgery seemed to be very promising in documentation by Schmidt and Pogrel in which there was a recurrence rate of only 11.5% in patients treated with enucleation and liquid nitrogen cryotherapy (15). The tendency for multifocal lesions in both syndromic and non-syndromic patients is of paramount importance since OKC patients are usually treated to "prevent" recurrence at the margins of the initial lesion (13).

OKCs associated with NBCCS are more aggressive and have higher recurrence rates than those associated without syndrome (32).

In conclusion, due to the possibility that multiple OKCs might be the first & only manifestation of NBCCS, the higher rate of recurrence of OKCs in NBCCS and the probable development of ameloblastoma (17, 33) & other associated problems in future, it is the responsibility of the dentist and of the oral surgeon to rule out the presence of this syndrome and start the adequate treatment as soon as the diagnostic is made and provide a careful follow-up.

REFERENCES

1. Koseoglu BG, Atalay B, Erdem MA. Odontogenic cysts: a clinical study of 90 cases. *J Oral Sci.* 2004;46(4):253-7.
2. Kramer IRH, Pindborg JJ, Shear M. Histological typing of odontogenic tumours. 2nd ed. Berlin: Springer Verlag; 1992.
3. Chuong R, Donoff RB, Guralnick W. The odontogenic keratocyst. *J Oral Maxillofac Surg.* 1982;40(12):797-802.
4. Mosqueda-Taylor A, Irigoyen-Camacho ME, Díaz-Franco MA, To-rres-Tejero MA. Odontogenic cysts. Analysis of 856 cases. *Med Oral.* 2002;7(2):89-96.
5. Brannon RB. The odontogenic keratocyst. A clinicopathological study of 312 cases. Part I. Clinical features. *Oral Surg Oral Med Oral Pathol Oral Radiol Endod.* 1976;42(1):54-72.
6. Payne TF. An analysis of the clinical and histopathologic parameters of odontogenic keratocyst. *Oral Surg Oral Med Oral Pathol Oral Radiol Endod.* 1972;33(4):536-46.
7. Ahlfors E, Larsson A, Sjogren S. The odontogenic keratocyst: a benign cystic tumor? *J Oral Maxillofac Surg.* 1984;42(1):10-9.
8. Chirapathomsakul D, Sastravaha P, Jansisyanont P. A review of odontogenic keratocysts and the behavior of recurrences. *Oral Surg Oral Med Oral Pathol Oral Radiol Endod.* 2006;101(1):5-9; discussion 10.
9. Stoeltinga PJW. Long term follow up on keratocysts treated according to a defined protocol. *Int J Oral Maxillofac Surg.* 2001;30(1):14-25
10. Myoung H, Hong SP, Hong SD, Lee JI, Lim CY, Choung PH, et al. Odontogenic keratocyst: review of 256 cases for recurrence and clinicopathologic parameters. *Oral Surg Oral Med Oral Pathol Oral Radiol Endod.* 2001;91(3):328-33.
11. Partridge M, Towers JF. The primordial cyst (odontogenic keratocyst): its tumor-like characteristics and behavior. *Br J Oral Maxillofac Surg.* 1987;25(4):271-9.
12. Brannon RB. The odontogenic keratocyst. A clinicopathologic study of 312 cases. Part II. Histological features. *Oral Surg.* 1977;43(2):233-55.
13. Boyne PJ, Hou D, Moretta C, Pritchard T. The multifocal nature of odontogenic keratocysts. *J Calif Dent Assoc.* 2005;33(12):961-5.
14. Pindborg JJ, Hansen J. Studies on odontogenic cyst epithelium. 2. Clinical and roentgenologic aspects of odontogenic keratocysts. *Acta Pathol Microbiol Scand.* 1963;58:283-94.
15. Schmidt BL, Pogrel MA. The use of enucleation and liquid nitrogen cryotherapy in the management of odontogenic keratocysts. *J Oral Maxillofac Surg.* 2001;59(7):720-5.
16. Schmidt BL. The use of liquid nitrogen cryotherapy in the management of the odontogenic keratocyst. *Oral Maxillofac Surg Clin N AM.* 2003;15(3):393-405.
17. Ogunsalu C, Daisley H, Kamta A, Kanhai D, Mankee M, Maharaj A. Odontogenic keratocyst in Jamaica: a review of five new cases and five instances of recurrence together with comparative analyses of four treatment modalities. *West Indian Med J.* 2007;56(1):90-5.
18. Forssell K, Forssell H, Kahnberg KE. Recurrence of keratocysts. A long-term follow-up study. *Int J Oral Maxillofac Surg.* 1988;17(1):25-8.

19. Voorsmit RA, Stoelinga PJ, van Haelst VJ. The management of keratocysts. *J Maxillofac Surg.* 1981;9(4):228-36.
20. Minic AJ. Primary intraosseous squamous cell carcinoma arising in a mandibular keratocyst. *Int J Oral Maxillofac Surg.* 1992;21(3):163-5.
21. Shear M. The aggressive nature of the odontogenic keratocyst: is it a benign cystic neoplasm? Part 2. Proliferation and genetic studies. *Oral Oncol.* 2002;38(4):323-31. Erratum in: *Oral Oncol.* 2004;40(1):107.
22. McGrath CJ, Myall RW. Conservative management of recurrent keratocysts in basal-cell naevus syndrome. *Aust Dent J.* 1997;42(6):399-403.
23. Lindeboom JA, Kroon FH, de Vires J, van den Akker HP. Multiple recurrent and de novo odontogenic keratocysts associated with oral-facial-digital syndrome. *Oral Surg Oral Med Oral Pathol Oral Radiol Endod.* 2003;95(4):458-62.
24. Carr RJ, Green DM. Multiple odontogenic keratocysts in a patient with type II (mitis) Ehler-Danlos syndrome. *Br J Oral Maxillofac Surg.* 1988;26(3):205-14.
25. Connor JM, Evans DA, Goose DH. Multiple odontogenic keratocysts in a case of the Noonan syndrome. *Br J Oral Surg.* 1982;20(3):213-6.
26. Krimmel M, Reinert S. Multiple odontogenic keratocysts in mental retardation-overgrowth (Simpson-Golabi-Behmel) syndrome. *Br J Oral Maxillofac Surg.* 2000;38(3):221-3.
27. Shafer WG, Hine MK, Levy BM. "Textbook of oral pathology". 5th ed. Elsevier/Rajendran R, Sivapathasundharam B. Philadelphia: Saunders; 2006.
28. Sapp PJ, Eversole LR, Wysocki GP. Contemporary oral and maxillofacial pathology. St. Louis: Mosby; 2004.
29. Auluck A, Suhas S, Pai KM. Multiple odontogenic keratocysts: report of a case. *J Can Dent Assoc.* 2006;72(7):651-6.
30. Neville BW, Damm DD, Allen CM, Bouquet JE. Oral and maxillofacial pathology. 2nd ed. Philadelphia: Saunders; 2002.
31. Todd R, August M. Molecular approaches to the diagnosis of sporadic and nevoid basal cell carcinoma syndrome associated odontogenic keratocysts. *Oral Maxillofac Surg Clin N Am* 2003;15(3):447-61.
32. Dominguez FV, Keszler A. Comparative study of keratocysts, associated and non-associated with nevoid basal cell carcinoma syndrome. *J Oral Pathol.* 1988;17(1):39-42.
33. Holmlund A, Anneroth G, Lundquist G, Nordenram A. Ameloblastomas originating from odontogenic cyst. *J Oral Pathol Med.* 1991;20(7):318-21.

Received: 10/10/2008
Recebido: 10/10/2008

Accepted: 11/10/2008
Aceito: 10/11/2008