



THE ANTERIOR DENTAL CROSS-BITE: the paradigm of interception in orthodontics

A mordida cruzada anterior: o paradigma da interceptação em ortodontia

Orlando Motohiro Tanaka^[a], José Vinícius Bolognesi Maciel^[b], Tatiana Banzatto Kreia^[c],
Ana Letícia Rocha Ávila^[d], Matheus Mello Python^[e]

^[a] DDS, MSc, PhD, professor of Pontifícia Universidade Católica do Paraná (PUCPR), Curitiba, PR - Brasil, e-mail: tanakaom@gmail.com

^[b] DDS, MSc, PhD candidate, Orthodontics, Faculty of Dentistry, Universidade Federal do Rio de Janeiro (UFRJ), Rio de Janeiro, RJ - Brasil.

^[c] DDS, MSc, PhD candidate, Orthodontics, Universidade Estadual Paulista Julio de Mesquita Filho (UNESP), Araraquara, SP - Brasil.

^[d] DDS, MSc, candidate, Orthodontics, Faculty of Dentistry, Pontifícia Universidade Católica do Paraná (PUCPR), Curitiba, PR - Brasil.

^[e] DDS, MSc. PhD candidate, Orthodontics, Universidade Federal do Rio de Janeiro (UFRJ), Rio de Janeiro, RJ - Brasil.

Abstract

OBJECTIVES: To present specific clinical interception procedures instituted to reduce malocclusion severity on developmental stage. Anterior tooth cross-bite, involving one or two permanent teeth, is a common form of malocclusion diagnosed in children about 6 years of age. **RESULTS AND DISCUSSION:** Various devices can be suggested for single tooth cases, like removable cantilevered double-helix apparatus with digital springs, which is one of the most efficient to intercept malocclusion. In the other hand, fixed appliance does not depend on patient's cooperation and have greater action power and liberates more continuous forces. **CONCLUSION:** Dental anterior cross-bite, involving one tooth, can be corrected by means of the multi-loop arch wire with a double-helix, even in cases where adequate space for alignment is lacking.

Keywords: Anterior cross-bite. Interception. Double-helix apparatus. Fixed appliances.

Resumo

OBJETIVOS: Apresentar procedimento de interceptação clínica específica para reduzir a severidade da má oclusão no estágio de desenvolvimento. O cruzamento anterior, comprometendo um ou dois dentes permanentes, é forma comum de má-oclusão, diagnosticada em crianças em torno de seis anos de idade. **RESULTADOS E DISCUSSÃO:** Vários dispositivos podem ser

utilizados para casos de cruzamento de um dente apenas, como os aparelhos de duplo hélice em extremo livre, com molas digitais, um dos mais eficientes para interceptar más-oclusões. Por outro lado, os aparelhos fixos não dependem da colaboração do paciente, tendo maior poder de ação e de liberação de forças contínuas. **CONCLUSÃO:** Os cruzamentos anteriores comprometendo um dente podem ser corrigidos por meio de arco com dobras múltiplas, com hélice dupla, mesmo em casos onde há deficiência de espaço para o alinhamento.

Palavras-chave: Mordida cruzada anterior. Interceptação. Aparelho duplo hélice. Dispositivos fixos.

INTRODUCTION

Anterior tooth cross-bite involving one or two permanent teeth is a form of malocclusion diagnosed in children of about six years of age, where all authors prescribe correction as soon as possible, as long as the essential prerequisites are satisfied regarding compliance in using the recommended corrective device. Fundamentally, there must be sufficient room for tooth movement, as when malocclusion is diagnosed due to hereditary factors or intrinsic and extrinsic standards. Specific clinic procedures must be

instituted to reduce malocclusion severity and, in certain cases, to have it eliminated (1, 2).

During the mixed dentition stage, dental anterior cross-bite is frequently observed on routine clinical exams at the offices of general clinicians, as well as those of pediatric dentistry and speech therapists. The general clinician must identify, diagnose and even intercept the problem causing occlusion (3).

Dental anterior cross-bite will happen when one or more upper teeth erupt lingually in relation to those lower teeth with which they should occlude, (4) and when the mandible is in maximum intercuspation (2) (Figures 1-4E).

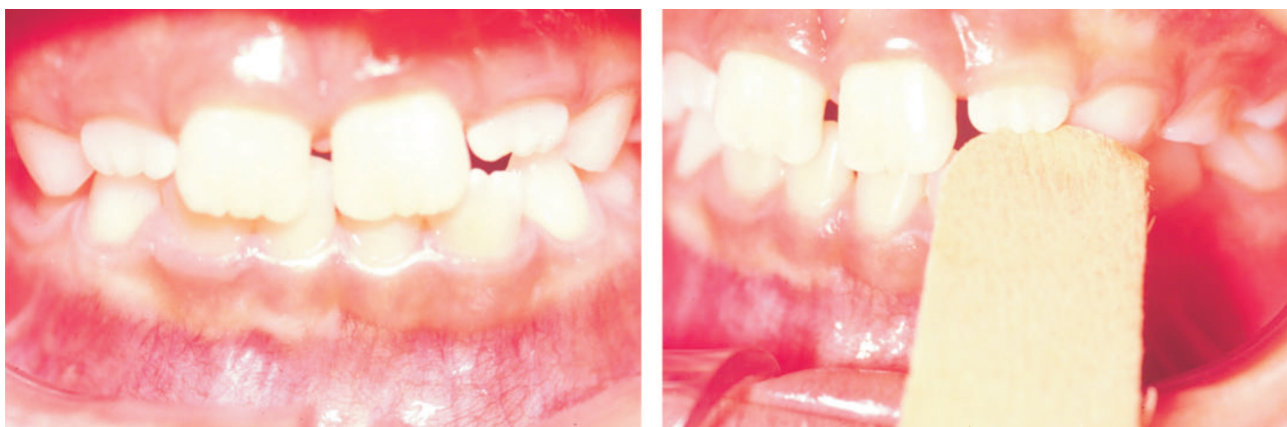

Figure 1 - The stick is oriented under the upper left lateral incisors erupting in the lingual position. Observe the ischemic area in the marginal gingiva of upper lateral incisors due to mild and constant pressure

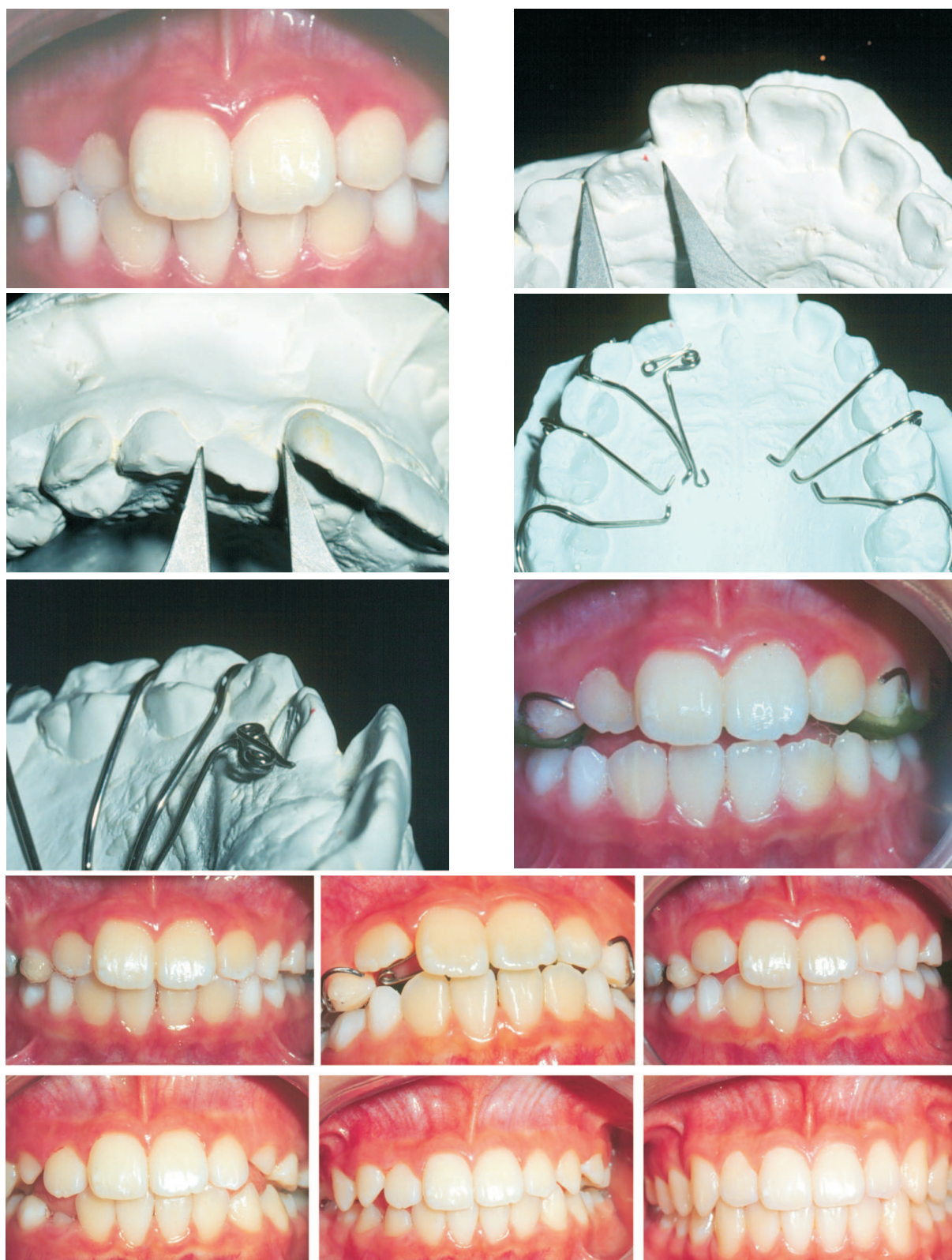

Figure 2 - Dental cross-bite of upper right lateral incisor is diagnosed. Enough space exists for the positioning in the line of occlusion. A removable appliance is installed with a occlusal bite plane and a double-helix digital spring adapted on cantilever. Observe normal gingival contour of the alveolar ridge of the lateral incisor

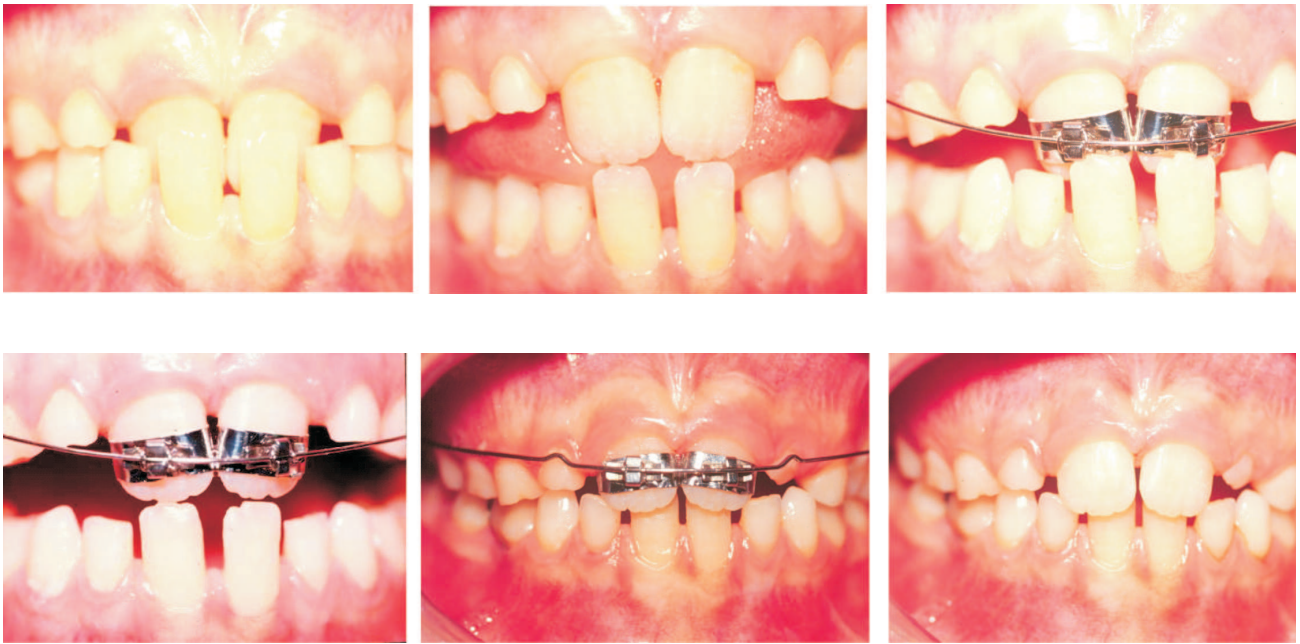


Figure 3 - Both upper central incisors in cross-bite, in maximum intercuspation with deep bite and centric relation position with incisors edge-to-edge. Bands, instead of brackets were fixed (round and rectangular arch wire) to obtain teeth movements in three planes of space

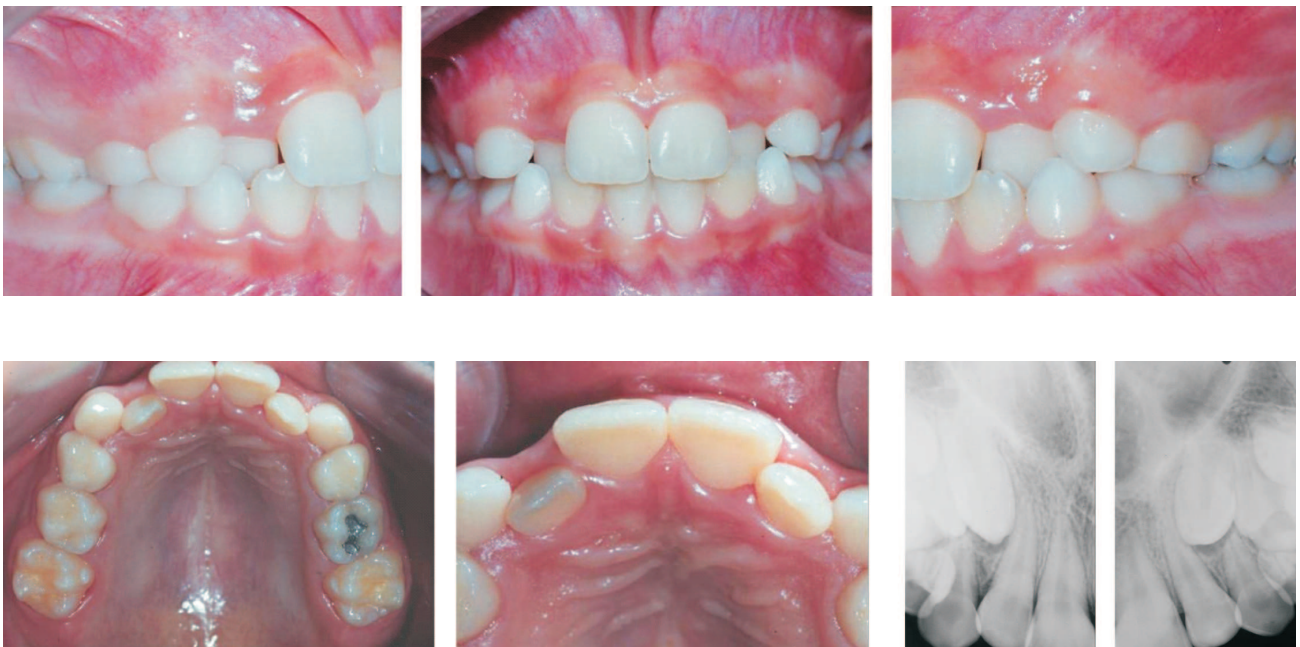

Figure 4 A - 10 years and 10 months. Angle Class I malocclusion. Cross-bite of both lateral incisors, without space for alignment. Peri-apical x-rays showing the developmental stage of canines, about one third of the way down the lateral roots

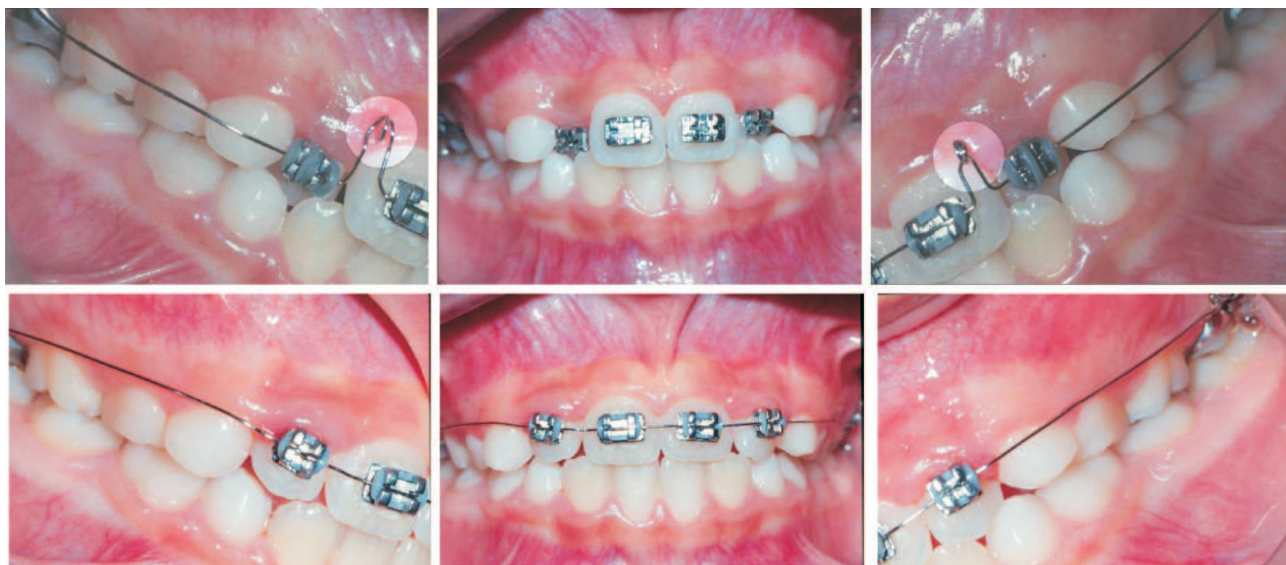

Figure 4 B - 10 years 10 months. Brackets on upper incisors. Bands on first permanent molars. Double helicoidal multiloop .016" stainless steel arch wire medial to crossed lateral incisors. Four weeks later, .016" stainless steel arch wire with offsets on almost uncrossed lateral incisors

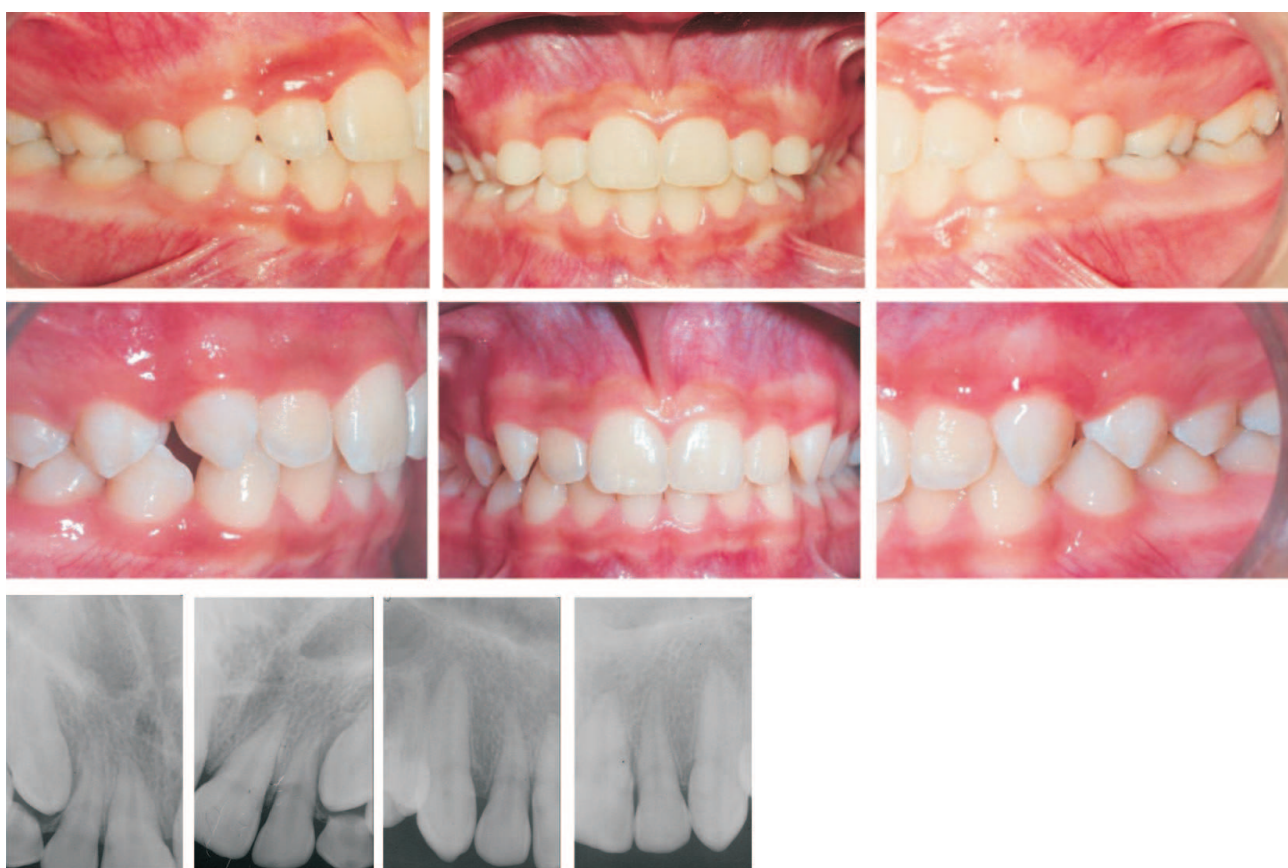

Figure 4 C - At age 13.0. Lateral incisors are maintained uncrossed. 14 years 7 months. Permanent dentition and acceptable aesthetics even with diastema between canines and first bicuspids. Radiographs showing end of mixed dentition with complete rhyssolysis of deciduous canines. In the permanent dentition, radicular normality of both lateral incisors and canines

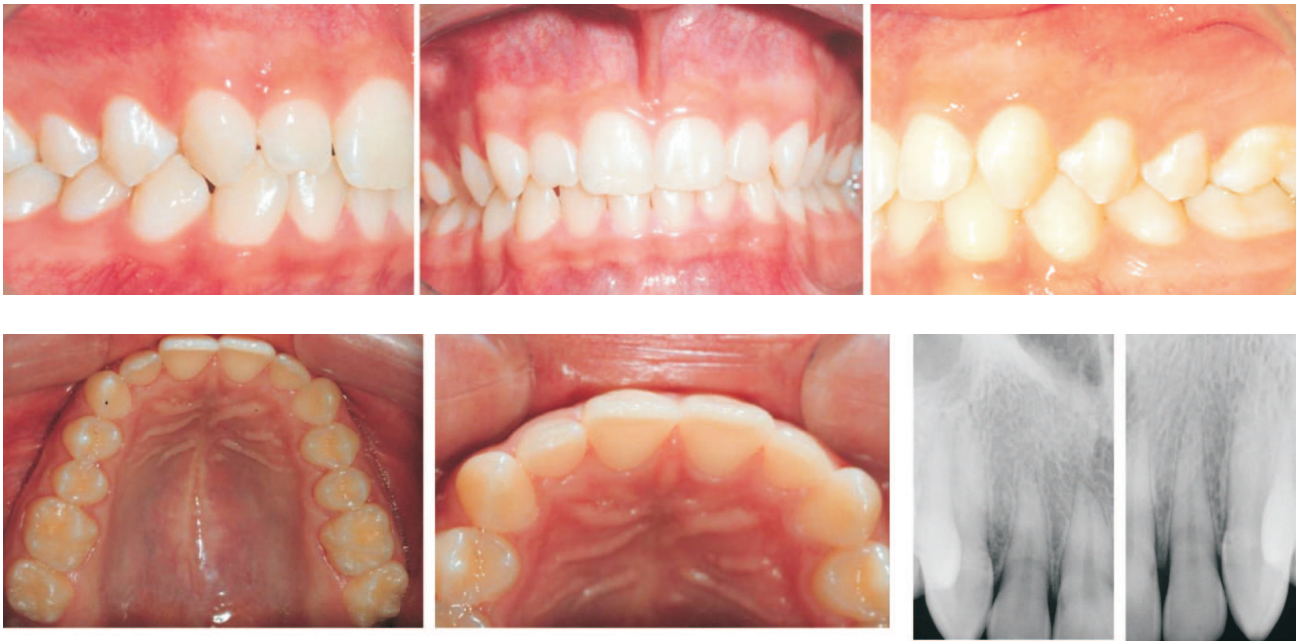

Figure 4 D - 18 years 11 months old. Permanent dentition without corrective orthodontic treatment. Alignment and intercuspation are acceptable. Right and left laterality movement guided by canines. Protrusion movement with contact on incisors. Aspects of bone and radicular normality at this age

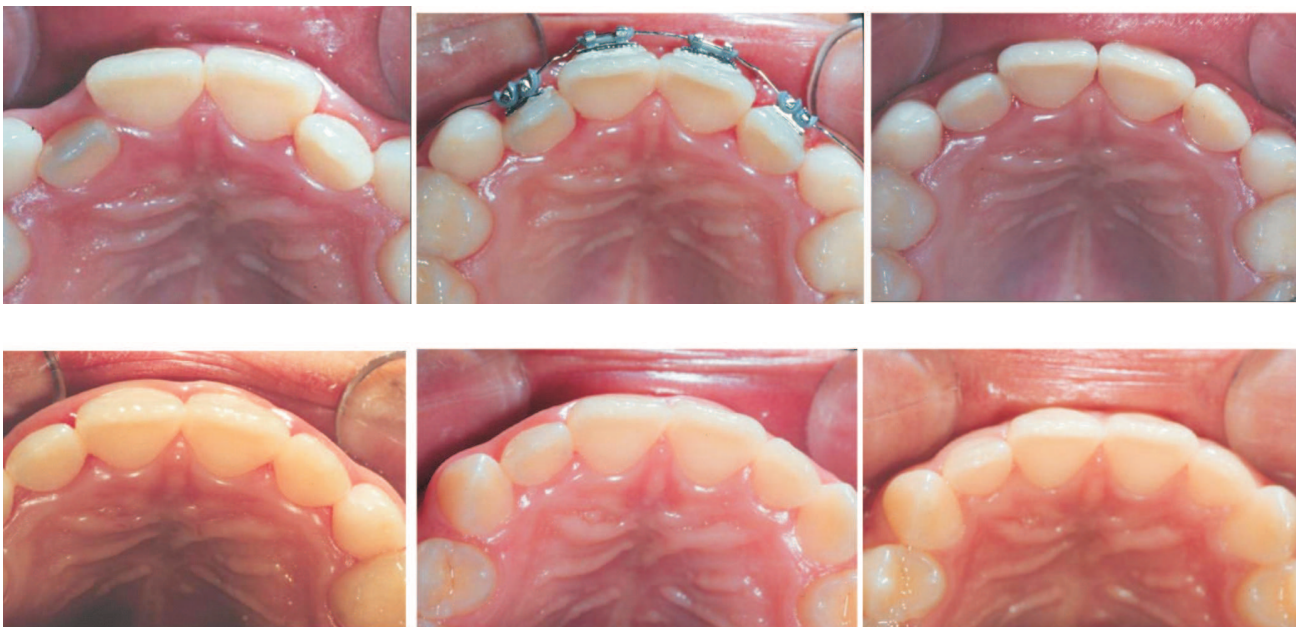

Figure 4 E - Occlusal view at 10 years 10 months old; 10 years 11 months; 11 years 9 months; 13 years of age; 14 years 7 months and 18 years 11 months of age

Interception in the context of orthodontics implies the existence of an abnormal situation (2). It is the period when science and art are employed in orthodontics to identify and eliminate potential irregularities and malpositionings of the developing dentofacial complex (1, 2).

It is believed the interception of anterior cross-bite is easier during its development. Clinical procedures regarding the elected device must take into consideration the number of teeth involved, and the correction to be made to the jaw (2, 5). Should the problem be deemed a local one, and sufficient space exist for the involved tooth, various devices can be suggested (Figures 2 and 3).

The prescribed removable upper device is comprised of 6 retention clasps, of which 4 are circular or circumferential, 2 are ring-shaped or interproximal, and 1 (having 1 tooth in cross-bite) is a cantilevered double-helix digital spring, all of them embedded in self-curing acrylic with an occlusal back-stop. The spring must have maximum flexibility, so as to move the involved teeth in a vestibular direction (6). General instructions as to buccal hygiene and the use of the device must be passed on to the patient and/or the responsible persons. Activation must be performed at the moment the device is installed, and as many times as necessary, by the surgeon dentist. It represents a mechanical interception often delegated to more general clinics (Figure 2).

Supposedly, interception of anterior cross-bites is easier during their developmental stage. Unfortunately, the orthodontist is not able to examine the child/patient at the moment cross-bites are installed. For the surgeon-dentist fortunate enough to anticipate the eruption of an incisor (central or lateral) in a lingual position, a possibility will exist to instruct/guide the patient/parents or responsible persons in the use of a tooth-pick/Popsicle-stick/tongue depressor. Resting/reposing on the incisal edge and working as a fulcrum, the intra-oral portion of the stick is turned upward and forward/outward, recruiting the lingual surface of the lingually inclined tooth. The operation is recommended to be carried out for 1-to-2 hours daily. For those who spend time watching TV, the exercise can be performed in front of the set (2) (Figure 1).

Ten to fourteen days should be enough to move the lingually erupted tooth "to the other side of the fence" (2). The patient is instructed to

maintain constant pressure on the inclined plane and, simultaneously, to operate a light but constant pressure of the hands on the stick so as to prevent dislodgments.

Though easy, interception (Figure 1) may require knowledge of orthodontic mechanics such as is applied to fixed orthodontic devices (Figures 3 and 4).

The removable cantilevered double-helix apparatus with digital springs is one of the most efficient to intercept malocclusion. With its use, normal occlusion is restored, but orthodontic movements become somewhat limited, depending on the patient's cooperation and, above all, on the available free space on the arch (Figure 3).

The fixed appliance, having greater power of action and liberating more continuous forces when compared to removable ones, reduces the need for patient cooperation and allows for three-dimensional control of the tooth to be moved (Figure 3). For those cases where space is insufficient, the recommendation is for a fixed device formed by two pre-formed orthodontic bands, two brackets and multi-loop arch wire with double helix, mesial and distal to the lateral incisor on the cross-bite. This is an "orthodontic" interception exclusively designated for the orthodontist (Figures 4A-4E).

The multi-loop arch wire with double-helix is efficient for the straightening of teeth, particularly those lateral incisors lacking space to align the occlusion by means of a removable device; nevertheless, orthodontic mechanics must be well-understood (Figure 4B).

DISCUSSION

In cases where upper lateral incisors present dental cross-bite, with the permanent canines in the developmental stage, positioned approximately at $\frac{1}{2}$ of the apical third of lateral incisors, the force system with multi-loop arch wire is to be prescribed, even where sufficient space is lacking for the correction of cross-bite and positioning of these teeth to the line of occlusion. This interception can prevent undesirable inclination of the adjacent teeth and normalize the alveolar edge of laterals which present cross-bite, thus avoiding a second phase of corrective orthodontics.

CONCLUSION

Dental anterior cross-bite involving one tooth can be corrected by means of the multi-loop arch wire with a double-helix, even in cases where adequate space for alignment is lacking.

CONFLICT OF INTEREST STATEMENT

The authors declared no conflict of interest in the present manuscript.

INFORMED CONSENT STATEMENT

The patients signed an informed consent, kept in the records, in the archives of the Pontifícia Universidade Católica do Paraná (PUCPR).

REFERENCES

1. Davis JW. Why early treatment of cross-bites? *Dent Dig.* 1969;75(11):449-52.
2. Graber TM. *Orthodontics principles and practice.* 3rd ed. Philadelphia: W.B. Saunders; 1972. p. 668-708.
3. Araújo MCM. *Ortodontia para clínicos.* 2nd ed. São Paulo: Santos, 1982.
4. Telles CS. Um processo fácil para a correção da mordida cruzada na região anterior. *An Fac Nac Odont Univ Brasil.* 1954;7(5):127-39.
5. Sim J. *Minor tooth movement in children.* 2nd ed. St. Louis: CV Mosby; 1977.
6. Proffit WR, Fields Jr HW, Sarver DM. *Contemporary orthodontics.* 4th ed. St Louis: Elsevier; 2007.

Received: 11/20/2009

Recebido: 20/11/2009

Accepted: 01/26/2010

Aceito: 26/01/2010