

DIFFERENT IMPACTED TEETH IN MONOZYGOTIC TWINS: discussion of an unusual case

Diferentes dentes inclusos em gêmeos monozigóticos: discussão de um caso incomum

Moacyr Tadeu Vicente Rodrigues¹, Camila Lopes Cardoso², Etiene de Andrade Munhoz³, Renato Yassutaka Faria Yaedu⁴, Eduardo Sant'Ana⁵, Osny Ferreira Junior⁶

¹ DDS, MSc, Bauru School of Dentistry, University of São Paulo, Bauru, SP - Brazil.

² DDS MSc graduate student, Bauru School of Dentistry, University of São Paulo, Bauru, SP - Brazil.

³ DDS, MSc PhD graduate student, Bauru School of Dentistry, University of São Paulo. Bauru, SP - Brazil, e-mail: etiamfob@yahoo.com

⁴ DDS, MSc, PhD graduate student, Bauru School of Dentistry, University of São Paulo - Bauru, SP -Brazil.

⁵ DDS, PhD, Oral and Maxillofacial Surgeon, Department of Stomatology, Bauru School of Dentistry, University of São Paulo, Bauru, SP - Brazil.

⁶ DDS, PhD, Oral and Maxillofacial Surgeon, Department of Stomatology, Bauru School of Dentistry, University of São Paulo, Bauru, SP - Brazil.

Abstract

Two monozygotic twin sisters presented to the Surgery clinic after referral, each for extraction of an impacted tooth. Clinical examination revealed that one twin presented the mandibular left second premolar impacted, whereas the other had the mandibular left canine impacted. The literature demonstrates that alterations in tooth development may manifest in either of two ways in the context of this type of twinning. The first manifestation occurs when the characteristics are similar, yet on opposite sides; in this case, it is called "mirror imaging". The second manifestation is the expression of a certain characteristic identically in both, called "duplicates". Manifestation of these two types is directly related to the period of formation of the twins and consequently with chorionicity. This case presents a significant departure from the patterns previously described, suggesting that the actions of unknown local or environmental factors were able to alter the patterns of expression of this characteristic.

Keywords: Impacted tooth; Monozygotic twins; Environmental exposure.

Resumo

Dois gêmeos monozigóticos foram indicados para a Clínica Cirúrgica, ambos para remoção de dentes inclusos. Ao exame clínico, um dos gêmeos apresentava o segundo pré-molar inferior esquerdo incluso, enquanto que o outro apresentava o canino inferior esquerdo incluso. A literatura indica que alterações no desenvolvimento dentário podem manifestar-se de duas maneiras no contexto desse tipo de geminação. A primeira manifestação ocorre quando as características são similares, ainda que em lados opostos; nessa situação, é chamada "imagem em espelho". A segunda manifestação é a expressão de certas características idênticas em ambos, chamadas "duplicatas". Manifestação desses dois tipos está diretamente relacionada com o período de formação dos gêmeos e conseqüente corionicidade. Esse caso apresenta um distanciamento significativo dos padrões anteriormente descritos, sugerindo que ações locais desconhecidas ou fatores ambientais foram responsáveis pela alteração dos padrões de expressão dessa característica.

Palavras-chave: Gêmeos monozigóticos; Dentes inclusos; Exposição ambiental.

INTRODUCTION

Like supernumerary teeth, impacted teeth can occur in isolation or in combination (1, 2), and can be either unilateral or bilateral. Familial occurrence of supernumerary and impacted teeth is a poorly discussed issue (3). Twins, as first suggested by Galton (4), provide a unique tool to evaluate the interactions between "nature" and "nurture" in this context. Twins are the easiest and most frequently used tool to obtain heritability estimates of diseases, malformations and biometric traits.

Monozygotic twins originate from one fertilized egg that divides later on, whereas dizygotic twins originate from two separately fertilized eggs (5). The absolute frequency of monozygotic twins (3.5 to 4 per thousand pregnancies) is the same in all races at all maternal ages, and for all parties (5). Monozygotic twins share the same genotype and are often said to be identical when they share many physical features (6). The determination of monozygosity traditionally depends on the identification of numerous similar general physical features of each twin, known as concordance (7-9). Head size, hair color and texture, iris color and pattern, finger and palm prints, number and direction of hair spirals, morphology of the pinna of the ear, tongue rolling and midphalangeal hair pattern have all been considered (9).

Lundstom (9) found that the general morphological characteristics of teeth were a reliable indication of zygosity. However, minor differences

in the shapes of particular teeth, such as differences in the number of lingual cusps of a premolar, may be the result of variation in the expression of the same gene(s). The same degree of variation often occurs between contralateral teeth on the right and left sides of the dental arch in the same individual.

An interesting aspect of concordance between monozygotic twins is the occurrence of "mirror imaging". This phenomenon is the appearance of an asymmetrical feature or anomaly occurring on the right side of one twin and on the left side of the other twin. Mirror imaging in twins has been reported frequently in relation to several unilateral dental anomalies (8, 10-14).

Sometimes, the twins' features can be similar on the same side of the body. They are then called "duplicates" because they have exactly the same feature on the corresponding side (6, 15).

The aim of this article is to describe a curious case of differentially impacted teeth in monozygotic twins.

CASE REPORT

Two monozygotic twins aged 18 years attended the Surgery clinic with orthodontic indications for extraction of two impacted teeth. Radiographically, twin 1 presented the mandibular left canine impacted (Figure 1), and twin 2 presented with the mandibular left second premolar impacted, as well as the deciduous mandibular left second molar

in advanced stages of exfoliation (Figure 2). Intraoral examination of twin 1 revealed that the former did not present crowding of the mandibular teeth and had the mandibular left canine impacted (Figure 3), whereas

twin 2 presented severe crowding of the mandibular teeth, as well as an impacted mandibular left second premolar; the deciduous mandibular left second molar had already been extracted (Figure 4).

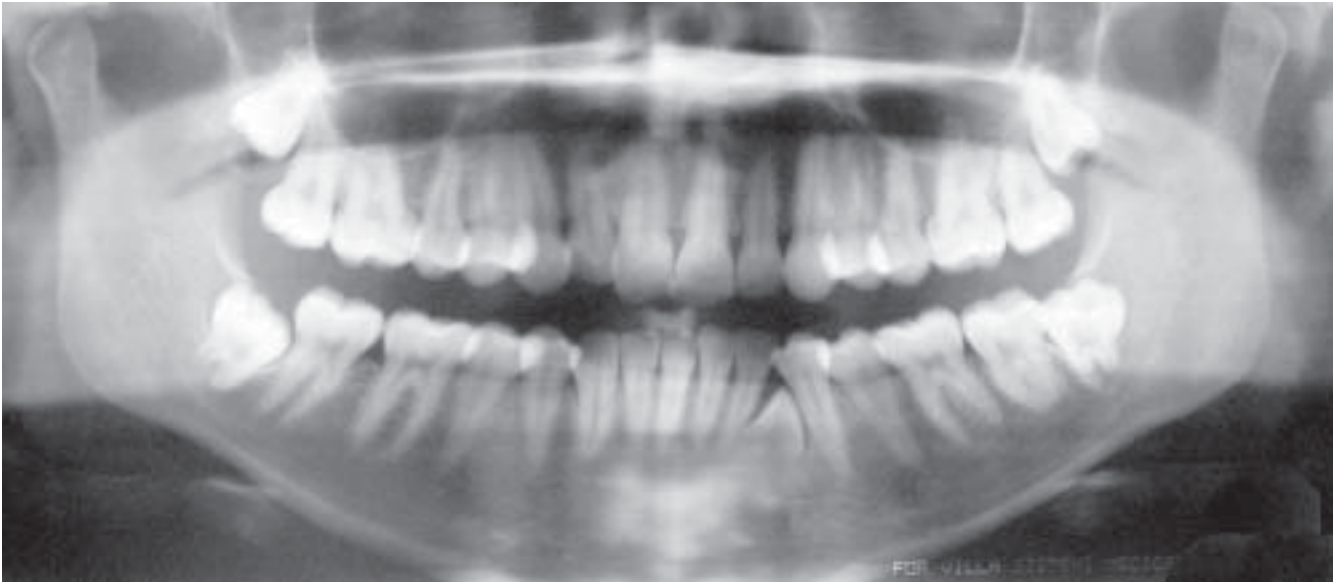


FIGURA 1 - Panoramic radiograph of twin 1

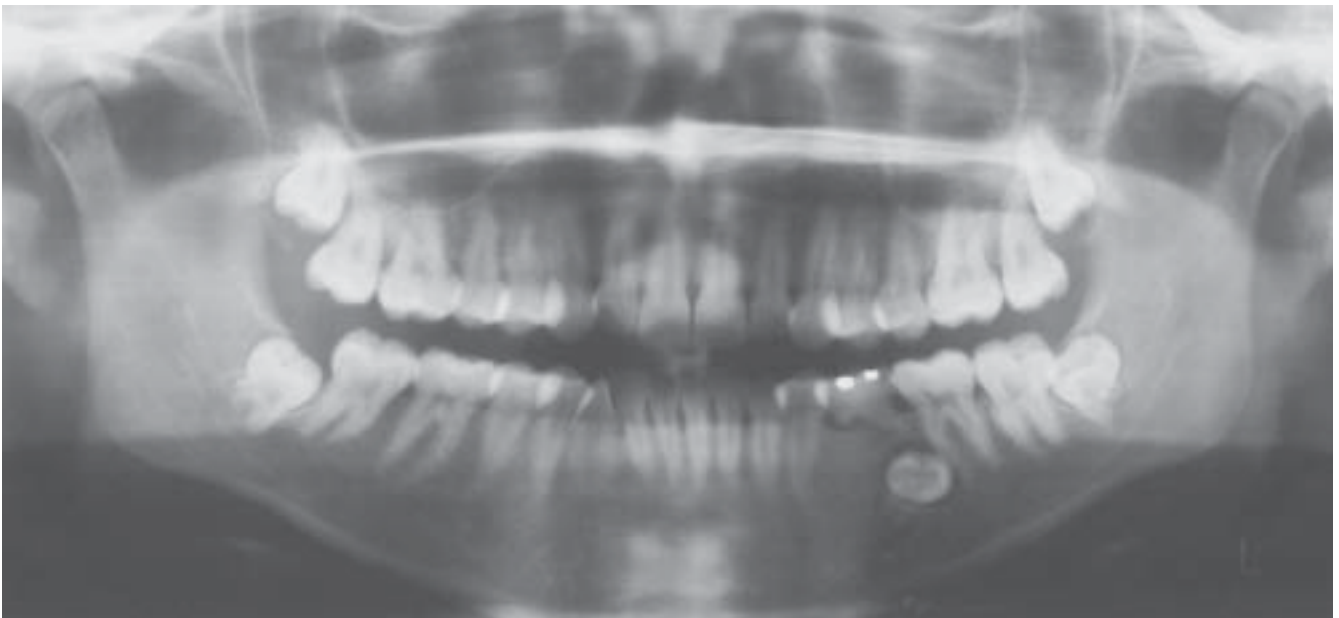


FIGURA 2 - Panoramic radiograph of twin 2

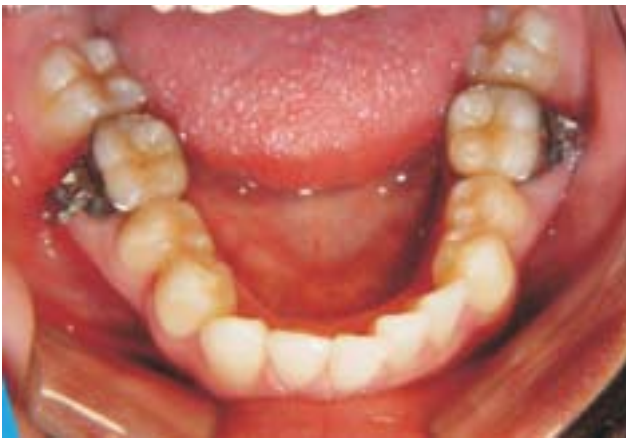

FIGURA 3 - Occlusal photograph of twin 1

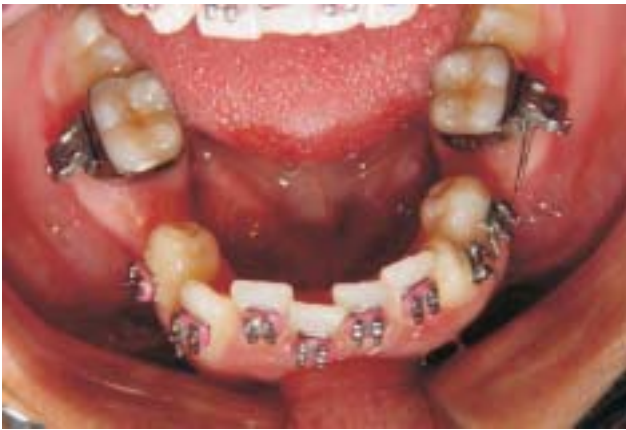

FIGURA 4 - Occlusal photograph of twin 2

The impacted teeth were extracted following the surgical technique (flap and sectioning) indicated in these cases. The surgical access of impacted canine was buccal in twin 1 (Figure 5), and the premolar was lingual in twin 2 (Figure 6).

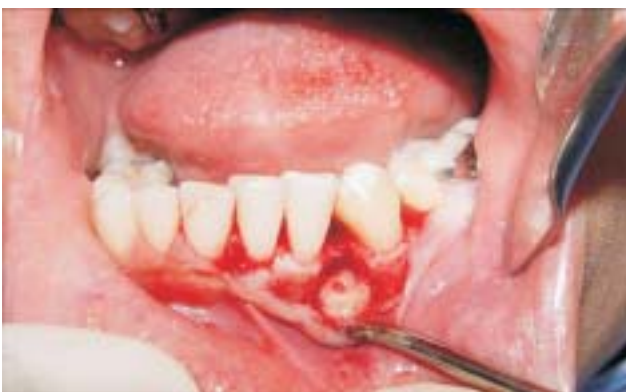

FIGURA 5 - Canine being extracted from buccal flap

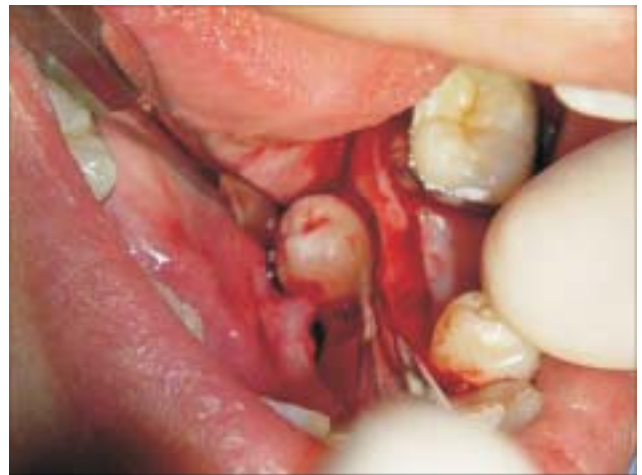

FIGURA 6 - Pre-molar being extract from lingual flap

After extraction and observation that it was an uncommon case, the parents were questioned as to possible events during pregnancy or growth of the twins that might lead to this unusual pattern.

The gestational period was nine months. The birth weight was 3.1 Kg and 2.9 Kg. We sought signs of prematurity or even significant difference in weight, which might give rise to different patterns of development. No drugs were used during pregnancy except for those recommended by the gynecologist. There were no reports of trauma during pregnancy. No deciduous tooth had been prematurely extracted. Except for the deciduous mandibular left second molar, which had been extracted some weeks before, the twins reported that they had never extracted any tooth. This eliminates the hypothesis of trauma during extraction of deciduous teeth that might have displaced the permanent tooth bud. Both had never suffered any trauma at the mandibular region, such as dentoalveolar and/or skeletal fractures. This finding also rules out the hypothesis that a trauma might have interfered with the tooth formation or eruption. Remaining hypotheses are related to general environmental factors, such as nutrition, school activities, daily activities, and others.

DISCUSSION

The unusual aspect of this case was the occurrence of differentially impacted teeth on the same side of the mandible. The reports in the literature on the occurrence of alterations in tooth

development present cases of “mirror imaging” or “identical duplicates”. Slight differences as to shape and calcification are typically found.

The dynamics of events during the first days after fertilization, when the embryo cells multiply and are divided in two, is extremely important during the gestation of monozygotic twins. This explains the occurrence of “mirror imaging” and “duplicates”.

When twinning occurs between the 1st and 3rd days, the twins have separate chorions, leading to formation of two amnions and two chorions; they are then called dichorionic diamniotic. If twinning occurs between the 3rd and 7th days, they share a single chorion, yet will have separate sacs, thus being called monochorionic diamniotic, corresponding to nearly 75% of identical twins. This period is much earlier than formation of the embryonic primitive line and therefore there is formation of two exactly identical individuals, or “duplicates”.

If twinning occurs from the 7th to 13th day, the twins share the same chorion and amniotic sac, and are called monochorionic monoamniotic. This period coincides with formation of the embryonic primitive line (which creates normal bilateral asymmetry). Thus, when the division is established, there is formation of two identical halves, and each half will engender what is lacking. For example, the left side of embryo 1 became the right side of embryo 2, which led to the term “mirror imaging”. Goldberg (16) (1930) and Runner (17) (1984) observed the occurrence of “mirror imaging”, assigning this phenomenon to the late division of the embryo, before formation of the primitive line (lateral differentiation).

On the other hand, when the twinning process occurs after the 13th day, the pregnancy is considered as high risk for formation of Siamese twins, since the division occurred after formation of the primitive line.

Despite these described patterns, several authors found differences between twins, both in “duplicates” and in “mirror imaging”. Brook (18) (1984) concluded that the genetic and environmental influences may alter expression with regard to the number of teeth involved (supernumerary) and dental morphology (number of cusps, calcification stage). Seddon (6) (1975) observed differences in the shape and orientation of teeth. Bucci and Martina (19) (1997) investigated two twin sisters with supernumerary teeth (hyperdontia) and indicated differences in the number of teeth and their distribution.

On the basis of the clinical-radiographic characteristics and statistical probability, the present pair of twins may be considered as “duplicate”. This gives rise to a question: Why didn't they present the same impacted teeth?

This is poorly explained in the literature, since there certainly is a relationship with factors difficult to evaluate, i.e. the environmental variables interfering during development. Some of these factors may be observed during the anamnesis; however, in the present case, no factors were found that may have significantly interfered with the development process and originated such differences between the twins.

CONCLUSION

As it is known, it is common and acceptable to find differences in the expression of a gene. Therefore, monozygotic twins may be regarded as genotypically identical, yet phenotypically similar. The period of division of the embryo and chorionicity strongly influence the manifestation of certain characteristics, such as tooth development disturbances. Thus, the action of environmental factors was probably the cause for this difference between the twins. Moreover, the impossibility of obtaining such aspects of the medical history as chorionicity and dental records from childhood (dental casts and radiographs) impairs the identification of any relevant environmental factors that might have interfered with tooth development and eruption. Further investigation is of the utmost importance, as careful documentation of monozygotic twins may provide the information necessary to explain many diseases and malformations.

REFERENCES

1. Mitchell L. Supernumerary teeth. *Dent Update*. 1989 Mar;16(2):65-6, 68-9.
2. Nazif M, Buffalo F, Zullo T. Impacted supernumerary teeth: a survey of 50 cases. *J Am Dent Assoc*. 1983;106(2):201-4.
3. Langowska-Adamczyk H, Karmanska B. Similar locations of impacted and supernumerary teeth in monozygotic twins: a report of 2 cases. *Am J Orthod Dentofacial Orthop*. 2001;119(1):67-70.

4. Galton F. The history of twins as a criterion of the relative powers of nature and nurture. *J. Anthropol Inst.* 1875;5(4):391-406.
5. Lauweryns I, Carels C, Vlietinck R. The use of twins in dentofacial genetic research. *Am J Orthod Dentofacial Orthop.* 1993;103(1):33-8.
6. Seddon RP, Johnstone SC, Smith PB. Mesiodentes in twins: a case report and a review of the literature. *Int J Paediatr Dent.* 1997;7(3):177-84.
7. Gravely JF, Johnson DB. Variation in the expression of hypodontia in monozygotic twins. *Dent Pract Dent Rec.* 1971;21(6):212-20.
8. Jasmin JR, Jonesco-Benaiche N, Muller-Giamarchi M. Supernumerary teeth in twins. *Oral Surg Oral Med Oral Pathol.* 1993;76(2):258-9.
9. Lundström A. Tooth morphology as a basis for distinguishing monozygotic and dizygotic twins. *Am J Hum Genet.* 1963;15:34-43.
10. Beere D, Hargreaves JA, Sperber GH, Cleaton-Jones P. Mirror image supplemental primary incisor teeth in twins: case report and review. *Pediatr Dent.* 1990;12(6):390-2.
11. Mensing CA. Mirror-image twins. *Northwest Dent.* 1983;62(6):41-2.
12. Nik-Hussein NN, Salcedo AH. Double teeth with hypodontia in identical twins. *ASDC J Dent Child.* 1987;54(3):179-81.
13. Schneider PE. Mirror-image twins with geminated incisors: report of a case. *Quintessence Int.* 1985;16(6):429-31.
14. West VC. Mirror image twins. *Aust Orthod J.* 1985;9(2):243.
15. Schön F. Supernumerary incisors in uniovular twins, and their treatment by means of electrosurgery. *Quintessence Int Dent Dig.* 1974 Jul;5(7):13-8.
16. Goldberg S. The dental arches of identical twins. *Dental Cosmos.* 1930;72(8):869-81.
17. Runner MN. New evidence for monozygotic twins in the mouse: twinning initiated in the late blastocyst can account for minor mirror image asymmetries. *Anat Rec.* 1984;209(2):399-406.
18. Brook AH. A unifying etiological explanation for anomalies of human tooth number and size. *Arch Oral Biol.* 1984;29(3):373-78.
19. Bucci E, Martina R. Iperdontia vera in gemelle monocoriali: caso clinico. *Archivio Stomatologico.* 1975;16(3):305-13.

Received: 05/14/2008

Recebido: 14/05/2008

Accepted: 07/15/2008

Aceito: 15/07/2008