



SCINTIGRAPHY OF THE SALIVARY GLAND IN PATIENTS WITH SJÖGREN'S SYNDROME TREATED WITH PILOCARPINE

*Cintigrafia da glândula salivar em pacientes com Síndrome de Sjogren
tratados com pilocarpina*

Luis Antônio Nogueira dos Santos^[a,b], Francisco Haiter Neto^[a], Frab Noberto Boscolo^[a],
Paulo Sérgio Flores Campos^[a], Hercílio Martelli Júnior^[b], Anamaria Lima Laranjeira^[c],
André Emerson Souza Santos^[d]

^[a] Department of Radiology, Faculdade de Odontologia de Piracicaba, Universidade Estadual de Campinas (Unicamp), Piracicaba, SP - Brasil, e-mail: luisnogueira@fop.unicamp.br

^[b] Universidade Estadual de Montes Claros (UNIMONTES), Montes Claros, MG - Brasil.

^[c] Private Clinic, Radiocenter Oral Radiology, Montes Claros, MG - Brazil.

^[d] Nucleus Clinic, Nuclear Medicine, Montes Claros, MG - Brazil.

Abstract

OBJECTIVE: This report describes monitoring of salivary glands through scintigraphy in one patient with SS before and after the administration of 1% pilocarpine. **DISCUSSION:** Sjögren's Syndrome (SS) is an immune-mediated disease that most commonly attacks the exocrine glands. The diagnosis of SS is based on the objective and subjective criteria that confirm the damage or diminished activity of salivary and lachrymal glands, in turn resulting in xerostomia and xerophthalmia. **CONCLUSION:** Scintigraphy with [^{99m}Tc] pertechnetate can be used to assess the progression of disease activity, the location affected and severity on the glands involved. Scintigraphy can also be used to assess xerostomia through activity time analyses, numeric indices, visual interpretations, and radiopharmaceutical percentages retained in the gland.

Keywords: Salivary gland. Scintigraphy. Sjögren's syndrome. Pilocarpine. ^{99m}Tc.

Resumo

OBJETIVO: Este relato descreve a monitoração de glândulas salivares por meio de cintigrafia em um paciente com Síndrome de Sjogren antes e após administração de pilocarpina a 1%. **DISCUSSÃO:** A Síndrome de Sjogren (SJ) é uma doença imunomediada que mais comumente

ataca as glândulas exócrinas. O diagnóstico da SJ é baseado em critérios objetivos e subjetivos que confirmam o dano ou atividade diminuída das glândulas salivares e lacrimais, resultando em xerostomia e xeroftalmia. CONCLUSÃO: Cintigrafia com pertecnato [^{99m}Tc] pode ser para determinar a progressão da doença, o local afetado e a severidade do envolvimento glandular. A cintigrafia pode também ser usada para avaliar xerostomia por análises de atividade no tempo, índices numéricos, interpretação visual e porcentagens radiofarmacêuticas retidas na glândula.

Palavras-chave: Glândulas salivares. Cintigrafia. Síndrome de Sjogren. Pilocarpina. ^{99m}Tc.

INTRODUCTION

Sjögren's Syndrome (SS) is an autoimmune disease characterized by dryness of the salivary and lacrimal glands ("sicca" symptoms) with extraglandular features including the involvement of the joint and nervous systems (1). In accordance with international diagnostic criteria, the diagnosis of SS is based on subjective and objective findings that confirm damage to or dysfunction of tear and salivary glands (2). Histopathologic and serologic tests, radiological findings, and salivary flow measurements are used to establish a diagnosis of SS (3). Pathologic analysis of a minor salivary gland biopsy is the gold standard for the diagnosis of SS. Two or more aggregates of inflammatory cells (50 or more lymphocytes) in a 4-mm² salivary gland sample should be examined (4). SS may occur in association with other autoimmune diseases, such as rheumatoid arthritis, systemic lupus erythematosus and scleroderma. Primary SS can be defined by extra glandular organ involvement, including lung (interstitial pneumonia), kidney (interstitial nephritis), peripheral and central nervous system manifestations, vasculitis of skin and other organs, and increased frequency of lymphoma (5).

Sialography has also been used as a gold standard in the diagnosis of SS. It is a sensitive method but has proven to be quite invasive. Radiographic criteria have been applied to the appearance of sialographic alterations (punctuate, globular and cavitary sialectasia), and related to a decrease in salivary gland function (2). Contrast radiography provides data on the morphology and flow velocity of the salivary duct system during invasive cannulation (6).

Salivary gland scintigraphy with [^{99m}Tc] pertechnetate is a readily available and non-invasive

method and is now included in diagnostic studies for SS defined by the European Community Study Group (7). Scintigraphy provides a functional evaluation of all salivary glands by observing the rate and density of [^{99m}Tc]pertechnetate uptake and its time of appearance in the mouth over a 60-min period after intravenous injection. This method presents high sensitivity but not disease specificity. The daily amount of saliva produced has been estimated to be 1000 to 1500 ml. Saliva facilitates the activities of eating and speaking. A decrease in salivation can cause various symptoms affecting the patient's quality of life. Thus, it is important to measure the function of the salivary glands in patients with SS and decreased salivation (8).

Scintigraphy of salivary glands, compared to other imaging modalities, allows glandular functions and excretions to be assessed (9). Objective evidence of salivary function is essential for the diagnosis, prognosis, and monitoring the progress of the disease and the effects of therapy (10).

Pilocarpine is a parasympathomimetic, muscarinic-stimulating cholinergic agonist, that increases the smooth muscle tone and motility of the gastrointestinal and urinary tracts, biliary ducts, and bronchi. The drug stimulates water and electrolyte flow and other salivary components. Secretory stimulation by these agents requires that residual functional salivary gland tissue be present. The side effects include excessive sweating, rhinitis, and urinary and gastrointestinal disturbances in addition to the risk of cardiovascular and pulmonary effects. This drug is contraindicated for users of beta-adrenergic blockers or in patients with gastric ulcers, uncontrolled asthma, or hypertension (11). The present report describes monitoring of the salivary glands using scintigraphy in one patient with SS who was treated with pilocarpine.

CASE REPORT

A 32-year-old, asymptomatic, female patient was directed by her physician to the health services of the Department of Stomatology at the State University of Montes Claros for treatment of dry mouth and dental care. The patient had previously been diagnosed with SS; that diagnosis was confirmed by a biopsy on the lower lip. The patient reported dry mouth and eyes, pain in the hands, and use of corticosteroids. Extraoral examination presented no changes. Clinically, the patient presented partial edentulism and defective dental restorations. Treatment of xerostomia with 1% pilocarpine hydrochloride (5

mg three times a day) was considered for the patient. Possible collateral effects were explained to the patient before she agreed to the treatment. Before the treatment was begun, the patient underwent a sialoscintigraphy, including an injection of 150 $\mu\text{Ci}/\text{kg}$ of pertechnetate to assess the amount of glandular parenchyma present. The images were acquired using a SPX-4 (Elsint) gamma camera with a 128 x 128 matrix, parameters for low energy, high resolution and parallel collimator hole. Fifteen minutes after the injection of 150 $\mu\text{Ci}/\text{kg}$ of pertechnetate, 4 frames per 60 s, were taken. New images were taken at 15 and 30 min after stimulation with lemon (Figure 1).

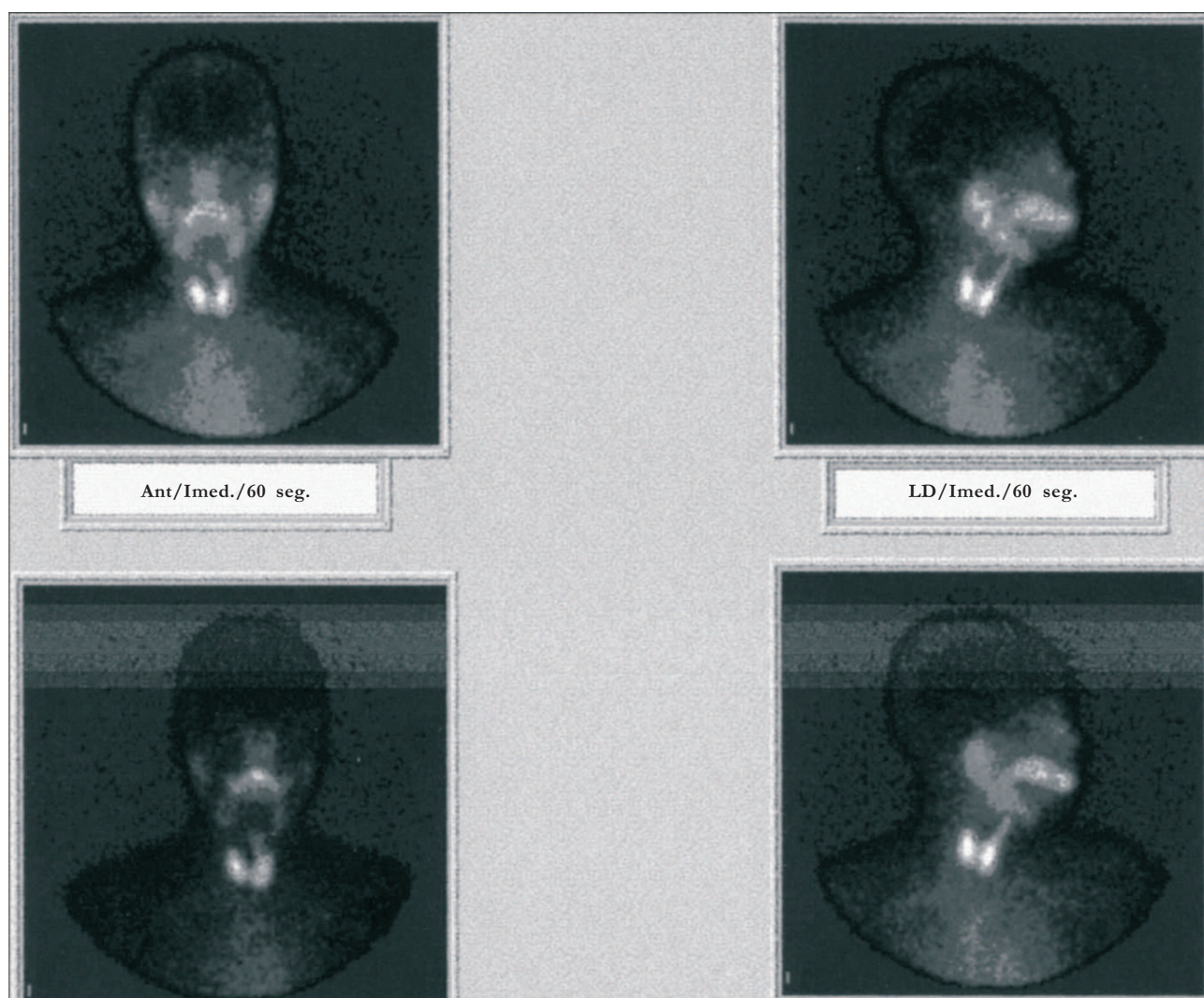


Figure 1 - Severe dysfunction, before treatment

The result of the examination revealed a severe dysfunction (excretion $\leq 25\%$). The damage in the salivary gland was classified according to the scoring system proposed by Shizukuishi et al. (12). Treatment with pilocarpine was carried out over a 12-week period. The patient also underwent 6 months of follow-up treatment using the new sialoscintigraphy, following the same protocol applied in the first examination, to assess the amount of active parenchyma. The examination proved that the medication was effective. Moreover, after 6 months of stimulation with pilocarpine, the production and secretion of saliva increased on the right side, with a minor improvement on the left side. Therefore, the classification was changed to moderate dysfunction (25% excretion rate, 25 - 40%) (Figure 2).



Figure 2 - After 6 months of stimulation with pilocarpine

During the treatment, the only discomfort reported by the patient was increased sweating.

DISCUSSION

Boner et al. (13) introduced [^{99m}Tc]pertechnetate in salivary gland scintigraphy more than 30 years ago for use as a radiopharmaceutical in the functional assessment of xerostomia. Scintigraphy non-invasively assesses the site, the severity, and the nature of salivary derangement, a unique capability (13). Despite its high level of sensitivity, this method is rarely used by dentists when assessing salivary glands in patients with sialorrhoea, xerostomia, sialadenitis, and radiation damage. Scintigraphy is a sensitive method for objective evaluation of salivary gland function. It is based on sequential measurement of the uptake, concentration, and excretion of [^{99m}Tc]pertechnetate. The pattern of [^{99m}Tc]pertechnetate uptake is recorded using a gamma scintillation camera. Salivary gland scans are graded on a scale of 1 to 4, based on the level of parotid gland uptake and secretion into the oral cavity (13). Taura et al. (14) investigated the correlation between thyroid uptake and the histopathologic grade of labial biopsy, or the stage of SS, to clarify the relation between SS and thyroid dysfunction. For this, the author considered the use of salivary gland scintigraphy for the assessment of thyroid disorders in patients. It was found that the uptake of [^{99m}Tc]pertechnetate by the thyroid was significantly less in patients with advanced-stage SS than in patients with early-stage SS or in healthy controls.

In the present case, this healthy case of early-stage SS presented a normal uptake of [^{99m}Tc]pertechnetate in the thyroid. Pilocarpine is a cholinergic agonist that stimulates gland function by acting at muscarinic-cholinergic receptors, including those of salivary glands. A number of clinical studies of patients with multiple causes of dry mouth report a clinical response to orally administered pilocarpine with an improvement of mouthwetting in up to 90% of patients (15). The action of pilocarpine stimulated the salivary gland to increase its production with only minor side effects (high sudorese). When the use of the medication was interrupted, scintigraphy showed a high concentration and excretion from the salivary gland. Salivary gland scintigraphy provides a detailed functional assessment of salivation as it measures

the amount and speed of radioisotope uptake and excretion for all four major salivary glands. Twenty-four patients, 8 with SS and 16 presenting isolated sicca symptoms, were assessed. Peak tracer distribution was lower for patients with SS, whereas uptake was symmetrically delayed in all glands in SS patients. Stimulated excretion was significantly reduced in SS patients (16.3% in parotid and 17.4% in submandibular glands). However, in the isolated sicca patients, the excretions (32.2% in parotid glands and 26.9% in submandibular glands) were similar for all glands in the control groups. SS patients presented a longer time-to-peak (TP) uptake and a lower peak tracer (PT) distribution in the parotid glands and a reduced stimulated excretion (SE). Thus, quantitative salivary gland scintigraphy is a useful and objective tool to distinguish patients with SS (6).

In this case report, a reduction in TP uptake, PT distribution, and SE was found for all glands. The function of the parotid gland after treatment with pilocarpine was found to be asymmetric for TP, PT, and SE. The right side presented better results compared with the left side. The dysfunction of the submandibular gland was more severe than that of the parotid gland. Thus, when visual interpretation or time-activity curves were used, better results were found for parotid glands; the results remained unchanged for submandibular glands. Residual functional salivary gland tissue was present on the left side. When isolated stimulated excretion was analyzed, high excretion could be observed after treatment, which proves the efficacy of treatment with pilocarpine. Asymmetric conditions were found according to the damage in the parotid gland parenchyma, the degree of severity of the disease, and the opportunity for diagnosis. The action of pilocarpine is a cholinergic agonist that stimulates a rapid increase in salivary flow in the parotid gland but shows little to no efficacy in the submandibular gland. The degree of reduction in speed, peak uptake and secretion in this study is, on the whole, in agreement with data presented in other studies of paired time-activity curves for submandibular and parotid glands in primary SS patients (6).

In conclusion, salivary scintigraphy is a useful technique to objectively assess salivary gland function in patients with SS and to test their response to pilocarpine. Better results found in salivary uptake after 6 months lead to the conclusion that pilocarpine does improve salivary gland function.

ACKNOWLEDGMENTS

A.L.L. is in receipt of a scholarship from the Minas Gerais Research Support Foundation – FAPEMIG.

CONFLICT OF INTEREST STATEMENT

The authors formally declare that there is no conflict of interest in the present manuscript.

INFORMED CONSENT STATEMENT

The patient has signed an informed consent, kept in the records in the archives of the Institution.

REFERENCES

1. Langerman AJ, Blair EA, Sweiss NJ, Taxy JB. Utility of lip biopsy in the diagnosis and treatment of Sjogren's syndrome. *Laryngoscope*. 2007;117(6):1004-8.
2. Vissink A, Kalk WWI, Mansour K, Spijkervet FKL, Bootsma H, Roodenburg JLN, et al. Comparison of lacrimal and salivary gland involvement in Sjogren's syndrome. *Arch Otolaryngol Head Neck Surg*. 2003;129(9):966-71.
3. Kalk WWI, Vissink A, Spijkervet FKL, Bootsma H, Kallenberg CGM, Nieuw Amerongen AV. Sialometry and sialochemistry: diagnostic tools for Sjögren's syndrome. *Ann Rheum Dis*. 2001;60(12):1110-6.
4. Selim MA, Shea RC. Dermatopathologic manifestations of rheumatologic diseases. *Pathol Case Rev*. 2004;9(1):66-76.
5. Aragona P, Di Pietro R, Spinella R, Mobarici M. Conjunctival epithelium improvement after systemic pilocarpine in patients with Sjögren's syndrome. *Br J Ophthalmol*. 2006;90(2):166-70.
6. Henriksen AM, Nossent HC. Quantitative salivary gland scintigraphy can distinguish patients with primary Sjogren's syndrome during the evaluation of sicca symptoms. *Clin Rheumatol*. 2007;26(11):1837-41.
7. Vitali C, Bombardieri S, Jonsson R, Moutsopoulos HM, Alexander EL, Carsons SE, et al. Classification criteria for Sjogren's syndrome: a revised version of the European criteria proposed by the American-European consensus Group. *Ann Rheum Dis*. 2002;61(6):554-8.
8. Inamura T, Ino C, Katoh M, Kishimoto A, Kumazawa H, Matsumoto A, et al. A simple method to estimate the secretion of saliva from minor salivary glands using iodine-starch reaction. *Laryngoscope*. 2001;111(2):272-7.
9. Loutfi I, Nair MK, Ebrahim AK. Salivary gland scintigraphy: the use of semiquantitative analysis for uptake and clearance. *J Nucl Med Technol*. 2003;31(2):81-5.
10. Booker J, Howarth D, Taylor L, Voutnis D, Sutherland D. Appropriate utilization of semi-quantitative analysis in salivary scintigraphy. *Nucl Med Commun*. 2004;25(12):1203-10.
11. Von Bultzingslowen I, Sollecito TP, Fox PC, Daniels T, Jonsson R, Lockhart PB, et al. Salivary dysfunction associated with systemic diseases: systematic review and clinical management recommendations. *Oral Surg Oral Med Oral Pathol Oral Radiol Endod*. 2007;103 (Suppl:S57):1-15.
12. Shizukuishi K, Nagaoka S, Kinno Y, Saito M, Takahashi N, Ikawamoto M, et al. Scoring analysis of salivary gland scintigraphy in patients with Sjögren's syndrome. *Ann Nucl Med*. 2003;17(8):627-31.
13. Hermann GA, Vivino FB, Shnier D, Krumm RP, Mayrin V. Diagnostic accuracy of salivary scintigraphic indices in xerostomic populations. *Clin Nucl Med*. 1999;24(3):167-72.
14. Taura S, Muratay, Aung W, Ishida R, Zhang L, Hossain M, et al. Decreased thyroid uptake of Tc-99m pertechnetate in patients with advanced-stage Sjögren syndrome: evaluation using salivary gland scintigraphy. *Clin Nucl Med*. 2002;27(4):265-9.
15. Gorsky M, Epstein JB, Parry J, Epstein MS, Le ND, Silverman JS. The efficacy of pilocarpine and bethanechol upon saliva production in cancer patients with hyposalivation following radiation therapy. *Oral Surg Oral Med Oral Pathol Oral Radiol Endod*. 2004;97(2):190-5.

Received: 11/20/2009

Recebido: 20/11/2009

Accepted: 01/26/2010

Aceito: 26/01/2010