



RESTORATION OF NON CARIOUS CERVICAL TOOTH SURFACE LOSS LESIONS USING COMPOSITE AND DENTIN PINS: report of two cases

*Restauração de lesões não cariosas cervicais utilizando compósitos e pinos
dentinários: relato de dois casos*

Mehmet Yildiz^[a], Osman Tolga Harorlı^[b], Çağatay Barutcugil^[c]

^[a] Associate professor, Department of Conservative Dentistry, Faculty of Dentistry, Ataturk University Erzurum, Turkey, e-mail: mehmetyildiz25@hotmail.com

^[b] PhD, Department of Conservative Dentistry, Faculty of Dentistry, Ataturk University Erzurum, Turkey.

^[c] Department of Conservative Dentistry, Faculty of Dentistry, Ataturk University Erzurum, Turkey.

Abstract

OBJECTIVE: To illustrate an alternative method for the restoration of non carious cervical tooth surface loss lesions using composite and dentin pins. **METHOD:** In these two cases, extensive Class V non carious cervical tooth surface lesions were restored with composite resins and dentin pins and results were evaluated. **RESULT AND CONCLUSION:** Dentin pins could be an alternative support in large non carious cervical lesions.

Keywords: Cervical dental lesions. Dentin pins. Retention.

Resumo

OBJETIVO: Ilustrar um método alternativo para a restauração de perdas cervicais não cariosas utilizando compósitos e pinos dentinários. **MÉTODO:** Nos casos apresentados, extensas lesões cervicais não cariosas foram restauradas com resinas compostas e pinos dentinários, para avaliação dos resultados. **RESULTADOS E CONCLUSÕES:** Os pinos de dentina podem ser um suporte alternativo na restauração de dentes com grandes lesões cervicais não cariosas.

Palavras-chave: Lesões dentárias cervicais. Pinos dentinários. Retenção.

INTRODUCTION

The incidence of non carious cervical tooth surface loss (NCCTSL) is increasing due to augmentations of lifespan and tooth retention period. The number and size of lesions both tend to increase with age. Commonly, NCCTSLs are found on the facial aspects of the teeth and their prevalence and distribution can depend on the oral hygiene habits, as well as the right or left handedness of the patient when tooth brushing (1). The loss of dental hard tissue in the cervical region appears to be a multi-factorial phenomenon (2), with friction, corrosion, and stress playing critical roles in the etiology and progression of these lesions. Friction, which includes abrasion and attrition, leads to wear. Corrosion arises from chemical and electrochemical degradation of the dental tissues, while stress leads to micro fracture and abfraction as a result of compression, flexure, and tension forces (3). In addition, a combination of occlusal load and an acid environment may cause in vitro cervical notch lesions (1).

The choice of technique and materials used in restoration of class V cervical lesions remains controversial (4, 5). Conventional glass ionomer materials, resin-modified glass ionomer cements and polyacid-modified resin composites have all been typically used for adequate restoration of cervical cavities. However, by virtue of their high wear resistance and good esthetic properties, resin composites used with dentin bonding agents are still considered the best alternative for the restoration of cervical lesions (4, 6, 7).

Even though dentin pins carry the possible risk of causing dentin cracks or pulpal perforation (8), retentive dentin pins are widely used in restorative dentistry, as they amplify the retention of dental restorations to teeth that have suffered extensive coronal destruction. Although various pins and techniques are available, self-threading retentive pins are most commonly used due to their excellent retentive properties (9).

In the two cases reported here, an alternative method for restoration of non carious cervical lesions is presented.

Case 1

A 47-year-old male patient was referred to Atatürk University Faculty of Dentistry, Department of Conservative Dentistry, Erzurum, Turkey for a

restoration of his left mandibular first molar. The patient complained about the failure of two previous restorations that occurred few months after the treatments. Clinical examination revealed a remarkable wideness of the non carious cervical lesion. The clinical features seemed to be a consequence of a traumatic occlusion. After clinical examination, dental tissues were beveled with a diamond bur and dentinal surfaces were cleaned with tungsten carbide burs. Two small diameter titanium dentin pins were inserted into the each root dentin (Stabilok™ Medium Diameter Dentin Pins; Fairfax Dental™, Ireland), taking special care to avoid pulp exposure. One step dentin adhesive was applied to the tooth surface according to the manufacturer's instructions (Adper Prompt L-Pop™, 3M ESPE™, St Paul, MN, USA) and the restoration was completed with a universal composite resin (Filtek Valux Plus™; 3M ESPE™, St Paul, MN, USA) with an incremental technique using A2 shades. Finishing and polishing procedures were performed using contouring and finishing discs (Sof-Lex™; 3M ESPE™, St Paul, MN, USA).

The restoration was controlled in a routine dental examination after five years. After this long clinical service, although marginal defect and discoloration were observed in the enamel margins, the restoration was in place and required no restoration repair or replacement (Figure 1).

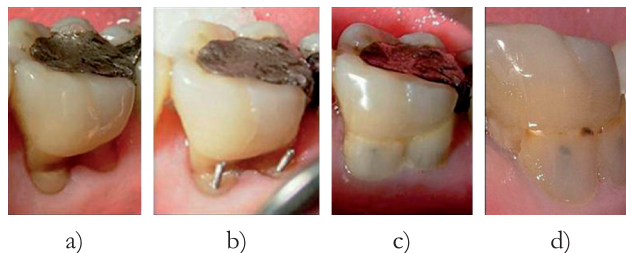


Figure 1 - a) wide non carious cervical lesion in left mandibular first molar; b) dentin pins were inserted; c) final restoration; d) restoration after five years

Case 2

A 69-year-old male patient who had a wide class V cervical lesion on his maxillary right second premolar was referred to Atatürk University Faculty

of Dentistry, Department of Conservative Dentistry, Erzurum, Turkey. His dental history revealed that the previous filling had failed within a short time after the restoration. Dentin hypersensitivity was observed during the clinical examination.

After beveling with a diamond bur and cleaning the dentinal tissues with tungsten carbide burs, two small diameter titanium dentin pins (Stabilok™ Medium Diameter Dentin Pins; Fairfax Dental™, Ireland) were inserted reciprocally under local anesthesia. The tooth surface was coated with a one step dentin bonding agent, according to the manufacturer's instructions. (Single Bond™, 3M ESPE™, St Paul, MN, USA) Final restoration was finished with a universal composite resin (Filtek Z250™ 3M ESPE™, St Paul, MN, USA) using UD and A2 shades with an incremental technique. Finishing and polishing processes were done with contouring and finishing discs (Sof-Lex™; ESPE St Paul™, MN, USA).

After two years of clinical service, the restoration was in place and no defects or discolorations were observed. After this period, the patient stated that the dentin hypersensitivity had resolved and that he was satisfied with the esthetics (Figure 2).

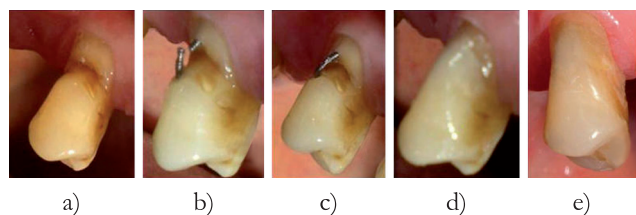


Figure 2 - a) class V cervical lesion on maxillary right second premolar; b) dentin pins were inserted; c) dentin pins were positioned; d) final restoration; e) restoration after two years

DISCUSSION

Adhesive technology has undergone great progress in the last decade; however, bonding to the dentin still remains challenging. Adhesive failure is still a particular risk for restorations, particularly those involving class V lesions. Since these lesions provide no macro-mechanical retention, ineffective bonding will result in early restoration loss (5). The cavity

margins of these lesions are generally positioned in both the enamel as well as in the dentin and /or cementum. However, restorative materials may not bond equally to these different tissues (4). Class-V lesions have a relatively small C-factor, which means that the mechanical properties of the composite used are more or less unimportant. It is the actual adhesive performance that determines the eventual clinical outcome, to a great extent (5).

Dentin pins can be viewed as an alternative support in large non carious cervical lesions. In these two case reports, dentin pins were found to amplify the cavity retention by forming a barrier in the cervical region. As seen in case one, even after five years clinical service, although partial resin failures were observed along the margins, the restoration was still in service. We consider that the macro-mechanical retention provided by dentin pins played an important role in cavity retention. More investigations are needed regarding the restoration of non carious cervical lesions with dentin pins, in order to evaluate the success of this clinical technique in class V restorations.

CONFLICT OF INTEREST STATEMENT

The authors formally declare that there is no conflict of interest in the present manuscript.

INFORMED CONSENT STATEMENT

Patients signed an informed consent, kept in the records in the archives of the Atatürk University Faculty of Dentistry.

REFERENCES

1. Wood I, Jawad Z, Paisley C, Brunton P. Non-carious cervical tooth surface loss: a literature review. *J Dent.* 2008;36(10):759-66.
2. Rees JS, Jagger DC. Abfraction lesions: myth or reality? *J Esthet Restor Dent.* 2003;15(5):263-71.
3. Grippo JO, Simring M, Schreiner S. Attrition, abrasion, corrosion and abfraction revisited: a new perspective on tooth surface lesions. *J Am Dent Assoc.* 2004;135(8):1109-18.

4. Folwaczny M, Loher C, Mehl A, Kunzelmann KH, Hickel R. Class V lesions restored with four different tooth-colored materials--3-year results. *Clin Oral Investig*. 2001;5(1):31-9.
5. Van Meerbeek B, Peumans M, Poitevin A, Mine A, Van Ende A, Neves A, et al. Relationship between bond-strength tests and clinical outcomes. *Dent Mater*. 2010;26(2):e100-21.
6. Ozgunaltay G, Onen A. Three-year clinical evaluation of a resin modified glass-ionomer cement and a composite resin in non-carious class V lesions. *J Oral Rehabil*. 2002;29(11):1037-41.
7. de Melo FV, Belli R, Monteiro Jr S, Vieira LC. Esthetic noncarious Class V restorations: a case report. *J Esthet Restor Dent*. 2005;17(5):275-84.
8. Segovic S, Ferik S, Anic I, Jukic S, Galic N, Sistig S. Changes in dentin after insertion of self-threading titanium pins with 3 methods: a scanning electron microscope pilot study. *J Prosthet Dent*. 2002;87(2):182-8.
9. Ersoz E. Evaluation of stresses caused by dentin pin with finite elements stress analysis method. *J Oral Rehabil*. 2000;27(9):769-73.

Received: 12/12/2009

Recebido: 12/12/2009

Accepted: 02/20/2010

Aceito: 20/02/2010