

## CORRECTION OF CANINE ROTATION WITH BOX LOOP

### *Correção da rotação de canino com alça em caixa*

Allan Abuabara<sup>1</sup>, Antonio Hiroshi Yoshida<sup>2</sup>, José Carlos Faria Lago<sup>3</sup>

<sup>1</sup> DDS, Specialist in Dental and Maxillofacial Radiology, City Hall of Joinville. Joinville, SC - Brazil, e-mail: allan.abuabara@gmail.com

<sup>2</sup> DDS, Ortodontist, Professor of the Institute of Post-graduation and Research of Joinville. Joinville, SC - Brazil.

<sup>3</sup> DDS, MSc, Professor of Institute of the Post-graduation and Research of Joinville. Joinville, SC - Brazil.

#### **Abstract**

Eruption disturbances of permanent canines have multifactorial causes and occur in a significant percentage of the population. To rotate a tooth on own axis using the continuous arch-wire can be quite complex. Whereas with the use of a fixed segmented TMA (titanium molybdenum alloy-TMA 0.017x0.025-inch) arch (box loop), rotation of the majority of single rooted teeth can be corrected. A case report of mandibular canine rotation in a fourteen year-old girl with a Class I skeletal pattern in the permanent dentition stage illustrates the principles of case management. It can be concluded that the box loop can correct the rotation of the mandibular canine simply in a short time, during the course of fixed orthodontic therapy.

**Keywords:** Orthodontics; Tooth movement; Biomechanics; Canine rotation.

---

#### **Resumo**

*Alterações de erupção dos caninos permanentes têm etiologia multifatorial e ocorrem em percentagem significativa da população. Girar um dente em seu próprio eixo é bastante complicado usando um arco contínuo. Usando um arco fixo segmentado de TMA (liga de titânio-molibdênio TMA 0.017x0.025 polegadas) em forma de alça "em caixa" (in box), podemos corrigir a rotação da maioria dos dentes unirradiculares. Para ilustrar os princípios do processo, relata-se o caso de giroversão do canino mandibular em uma menina de quatorze anos de idade, na dentição permanente e padrão esquelético de Classe I. É lícito concluir que um simples arco segmentado (alça "em caixa") pode corrigir a rotação do canino de maneira simples e em curto período de tempo, durante o curso da terapia ortodôntica.*

**Palavras-chave:** Ortodontia; Movimentação dentária; Biomecânica; Rotação de canino.

## INTRODUCTION

The causes of eruption disturbance of permanent canines are multifactorial. Canines require the longest period to develop, and they have the most difficult path of eruption in comparison with all of the other teeth (1). Genetic, systemic and local factors have been shown to be intimately associated with this phenomenon (2) which occurs in a significant percentage of the population (3). Using a box loop in a fixed segmented TMA (titanium molybdenum alloy-TMA 0.017x0.025-inch) arch, the rotation of single rooted teeth can be corrected.

## CASE REPORT

A fourteen year-old girl in the permanent dentition stage presented her chief complaint as being the appearance of her mandibular anterior

teeth. She had a Class I skeletal pattern. Radiography and a model revealed rotation of the mandibular right canine (Figures 1 and 2).

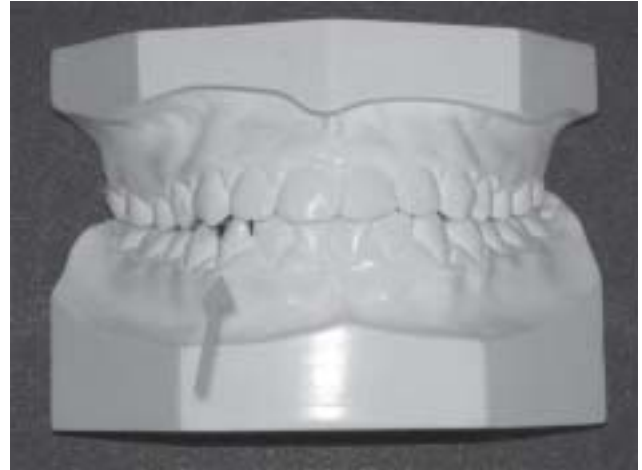


FIGURE 1 - Initial orthodontic model. The arrow indicates the rotated canine

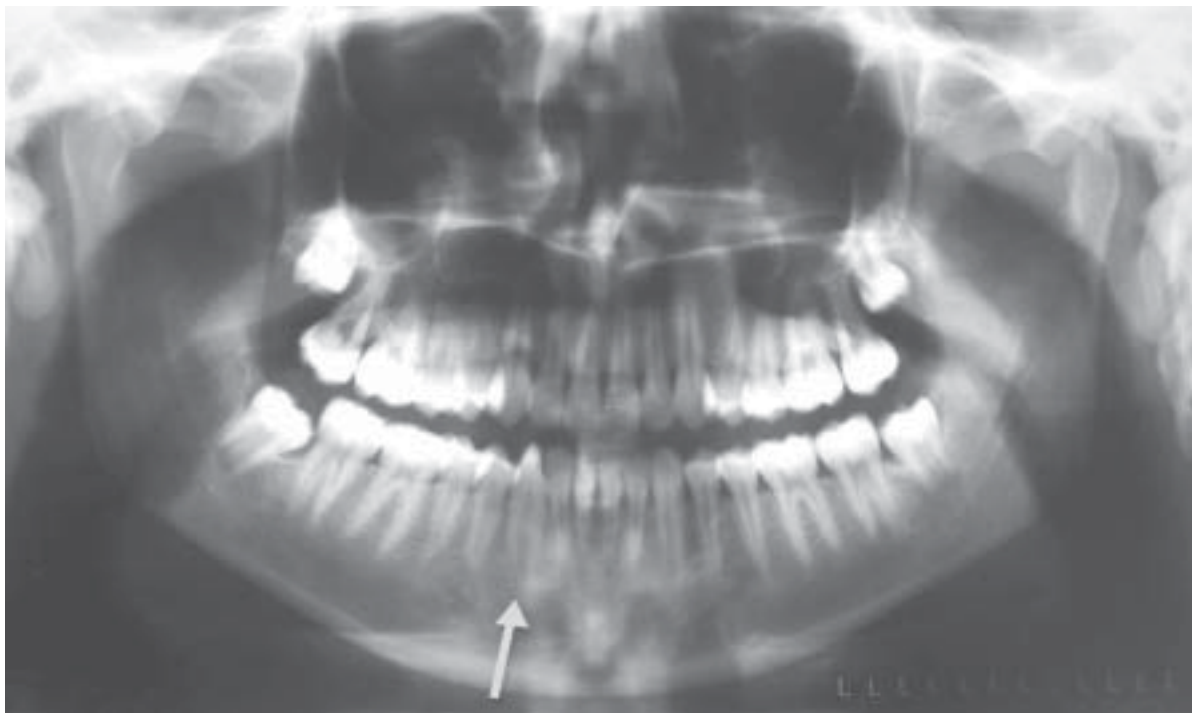

FIGURE 2 - Panoramic radiograph; arrow indicates the rotated canine

Treatment was performed by insertion of a fixed appliance: a 0.022-inch slot preadjusted. Roth appliance and standard mandibular lingual arch of 0.9-mm stainless steel for anchorage. The mandibular right canine rotation was corrected with a box loop

(TMA 0.017x0.025-inch) fixed in the molar auxiliary tube, premolars and canine brackets. The segmented arch was passive in the slot of the pre-molars and molar tube, which were joined with metal wire and active in the canine bracket slot (Figure 3).

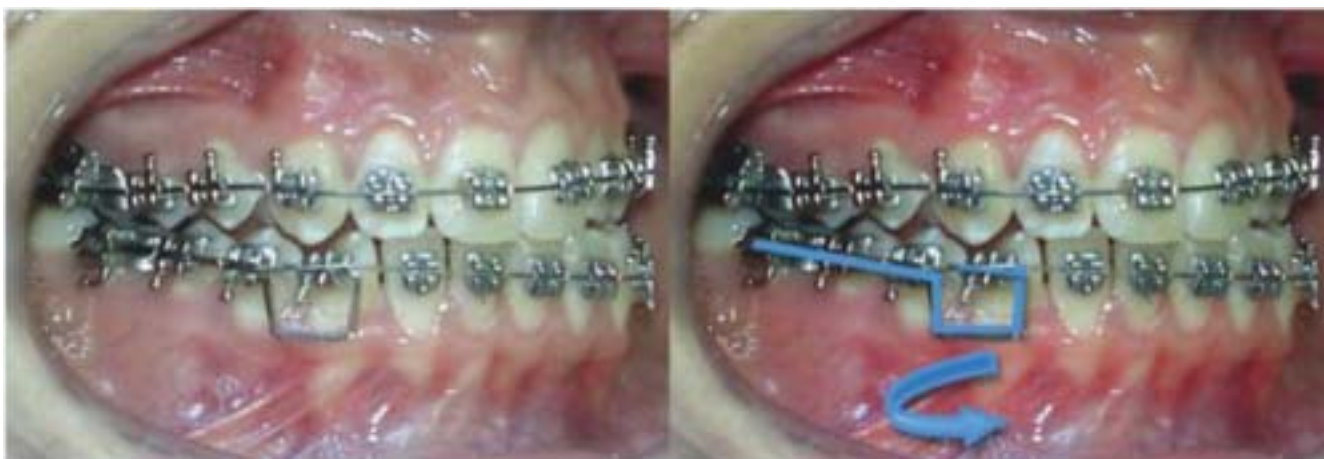

FIGURE 3 - Insertion of the segmented arch, "in Box" loop

Dental stripping with metal strips was performed to create space between the first premolar, canine and lateral incisor teeth. After treatment lasting two months, with monthly follow up, the position of the mandibular right canine was corrected. During the treatment, the other teeth were aligned with nickel titanium (NiTi) superelastic arch-wire, which added another two months to the treatment time. Bilateral intermaxillary intercuspitation was performed with 3/16-inch elastics during one month (Figure 4).

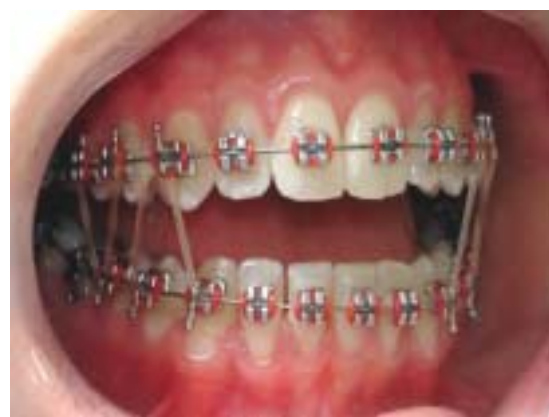

FIGURE 4 - 3/16-inch intermaxillary elastics

The fixed appliance was removed (Figures 5 and 6) and an Indirect Planas Track (IPT), a functional orthopedic appliance for a stable occlusal relationship was inserted (4).

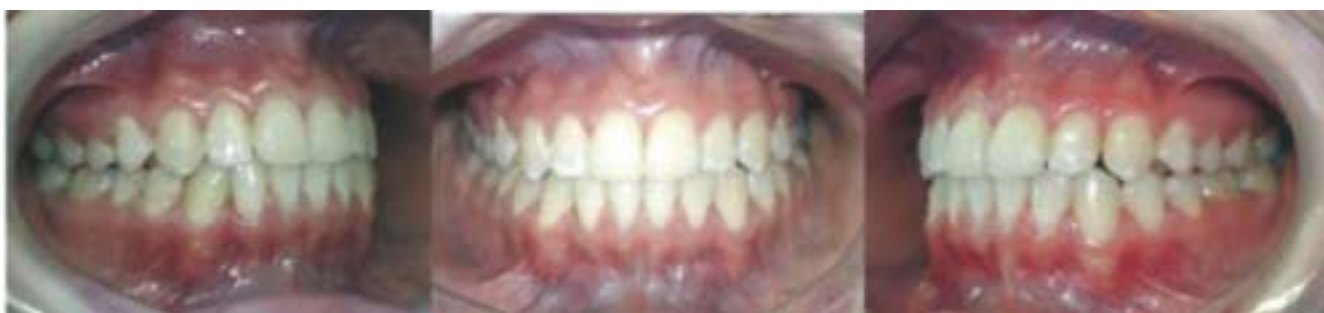

FIGURE 5 - Front and bilateral views immediately after the fixed appliance was removed

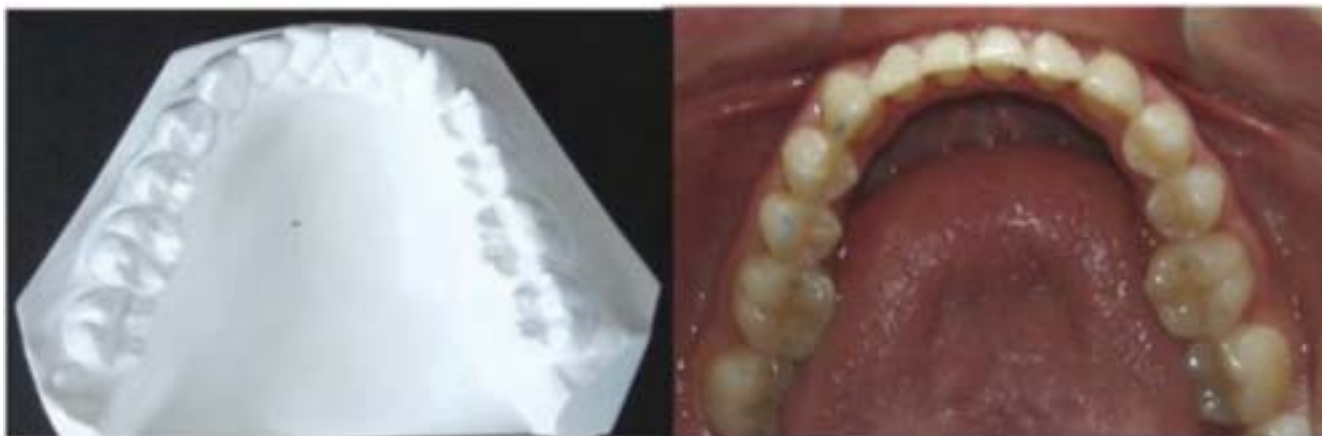

FIGURE 6 - Occlusal view before (orthodontic model) and after treatment (photo)

## DISCUSSION

Failure of tooth eruption may be the consequence of local factors. These factors may include mechanical obstruction (by a supernumerary tooth, cyst, or tumor); insufficient space in the dental arch due to skeletal incongruities (micrognathia); or to the premature loss of deciduous teeth or a tooth arch size discrepancy. Systemic factors such as genetic disorders, endocrine deficiencies, and previous irradiation of the jaws

are also associated with a failure of tooth eruption. In systemic conditions multiple teeth are usually impacted. However, in most cases the specific cause of failure of eruption remains unknown (5).

It can be quite complex to rotate a tooth on own axis by using the continuous arch-wire. In this case one can use the TMA segmented arch with the entrance to the bracket slot (box loop - Figure 3) in the opposite direction, which will allow only simple rotation. It can also be used for intrusion or extrusion teeth, as illustrated in Figure 7.

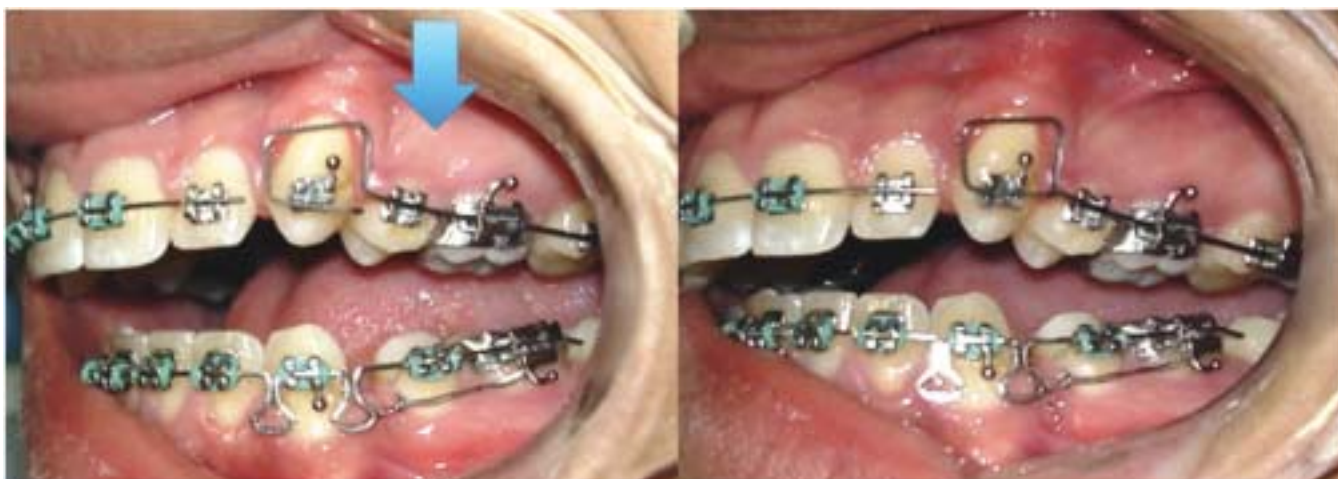

FIGURE 7 - Example of "in Box" loop use for canine extrusion

TMA is a stabilized titanium alloy in the beta phase, composed of titanium (79%), molybdenum (11%), zirconium (6%), and tin (4%). This alloy presents a lower modulus of elasticity, springback greater than that of steel, and a combination of adequate shape memory, medium stiffness, good formability, weldability and high attrition (6-9), therefore, it is used in the segmented arch technique (10). The segmented arch technique has been developed with three primary objectives, which were obtained in this clinical case: control of force on active and reactive teeth, reduction in the number of chair hours required to treat a case and minimized need for patient cooperation (11).

## CONCLUSION

Finally, it can be concluded that the simple box loop can correct the rotation of the mandibular canine simply in a short time during the course of the fixed orthodontic therapy.

## REFERENCES

1. Jacoby H. The etiology of maxillary canine impactions. *Am J Orthod.* 1983;84(2):125-32.
2. Bayram M, Özer M, Sener I. Maxillary canine impactions related to impacted central incisors: two case reports. *J Contemp Dent Pract.* 2007;8(6):72-81.
3. Yavuz MS, Aras MH, Büyükkurt MC, Tozoglu S. Impacted mandibular canines. *J Contemp Dent Pract.* 2007;8(7):78-85.
4. Planas P. *Rehabilitación neuro-occlusal (RNO)*. 2<sup>nd</sup> ed. Barcelona: Masson-Salvat; 1994.
5. Fonseca JR. *Oral and maxillofacial surgery*. Philadelphia: W. B. Saunders; 2000.
6. Kapila S, Sachdeva R. Mechanical properties and clinical applications of orthodontic wires. *Am J Orthod Dentofacial Orthop.* 1989;96(2):100-9.
7. Burstone CJ, Goldberg AJ. Beta titanium: a new orthodontic alloy. *Am J Orthod.* 1980;77(2):121-32.
8. Claro CAA, Abrão J, Reis SAB. Forces in stainless steel, TiMolium® and TMA® intrusion arches, with different bending magnitudes. *Braz Oral Res.* 2007;21(2):140-45.
9. Kusy RP. A review of contemporary archwires: their properties and characteristics. *Angle Orthod.* 1997;67(3):197-207.
10. Manhartsberger C, Morton JY, Burstone CJ. Space closure in adult patients using the segmented arch technique. *Angle Orthod.* 1989;59(3):205-10.
11. Burstone CJ. The mechanics of the segmented arch techniques. *Angle Orthod.* 1966;36(2):99-120.

Received: 01/26/2007  
 Recebido: 26/01/2007

Aceito: 20/03/2007  
 Accepted: 03/20/2007