



## Ocular prosthesis: art meets science

### *Prótese ocular: a Arte encontra a Ciência*

**Sonia Bhat**

BDS, MDS. Senior Lecturer, Department of Prosthodontics, Karnataka Lingayat Education Dental College and Hospital, Bangalore, Karnataka, India, e-mail: sonubhat@rediffmail.com

---

#### **Abstract**

**Objective:** To describe a method of fabricating of ocular prosthesis. **Discussion:** The conventional method of painting the iris region of a scleral prosthesis has been circumvented in this method. Fabricating an ocular prosthesis by conventional methods requires painting the scleral region. Painting the corneal region of the prosthesis is a tedious process. This article describes an easier, faster and a more aesthetic technique of customizing an ocular prosthesis.

**Keywords:** Ocular prosthesis. Scleral prosthesis. Stock prosthesis.

#### **Resumo**

**Objetivo:** Descrever um método de fabricação de prótese ocular. **Discussão:** O método convencional de pintura (caracterização) da região da íris numa prótese escleral foi modificado neste método. A fabricação de prótese ocular por métodos convencionais requer pintura da esclerótica. Pintar a região corneal da prótese é um processo tedioso. Este artigo descreve uma maneira rápida, fácil e com resultados estéticos satisfatórios de customização de próteses oculares.

**Palavras-chave:** Prótese ocular. Prótese escleral. Prótese de estoque.

---

#### **Introduction**

Loss of any part of the face is more disabling to the patient than loss of any other part of the body.

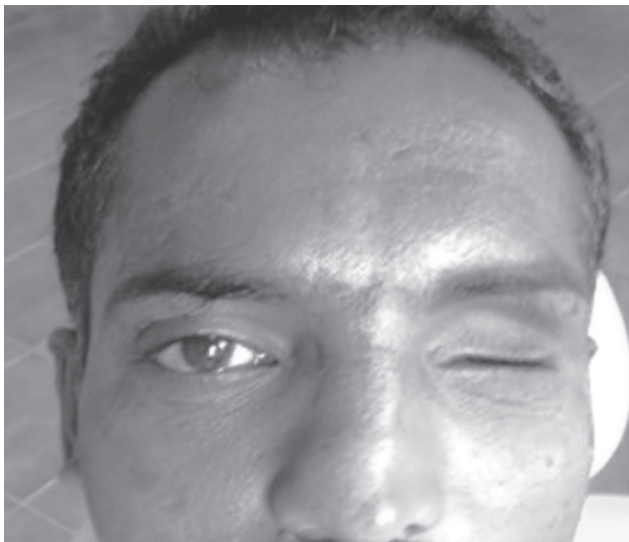The psychological impairment to the patient often exceeds physical impairment. A maxillofacial prosthodontist can help replace the missing part with a prosthesis that will restore the defect, improve esthetics,

and thereby improve the morale of the patient (1, 2). Loss of the eye can occur due to trauma, infection or congenital reasons (3, 4).

Replacement may be limited to the ocular content or in extensive cases the entire orbital and periorbital region. An ocular prosthesis is a simulation of human anatomy using prosthetic materials to create the illusion of a perfectly normal healthy eye and surrounding tissue (1, 2, 5)

## Case report

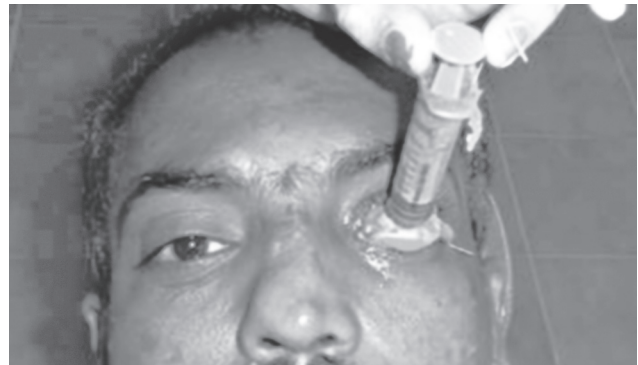A 35-year-old male patient was reported for replacement of his left ocular prosthesis (Figure 1).



**Figure 1** - Patient at the time of examination

It was a 6-year-old stock ocular prosthesis which had been placed following a surgical excision of the ocular content, damaged in a motor vehicle accident. The original prosthesis (stock prosthesis) was placed by an ophthalmologist. At the time of examination it was observed that the whole eyeball was surgically excised, but the muscles at the base of the socket were intact. The existing prosthesis had poor retention, did not support the eyelids well and did not match the opposite eye. The patient complained of poor aesthetics and requested a new prosthesis, emphasizing his wish to not wear tinted glasses. It was decided to fabricate a custom acrylic ocular scleral prosthesis to attend to all the

problems of the current prosthesis. After a thorough examination of the ocular defect, the treatment was initiated. First the impression of the defect was recorded (Figure 2).



**Figure 2** - Recording the impression

An intraocular special tray was fabricated with autopolymerizing acrylic resin (DPI). The convex surface of the pad of a thumb of the left hand of a volunteer was used as an index for the fitting surface, to simulate the convexity, size and shape of a normal eye. An opening was created with acrylic round burr in the centre to fit a narrow short hollow plastic tube. This acts as a channel for the impression material to enter the socket. The custom tray was tried in the patients socket and adjusted for a passive fit. Rubber base medium body impression material (Aquasil™, Dentsply) was loaded in syringe and injected into the socket through the hollow stem of the impression tray (ocular grade alginate can also be used).

Patient was seated in erect position with the head tilted backward at 45 degree angle while the socket was filled with impression material. The patient was asked to move his eyes both up and down. This facilitates the flow of the impression material into all aspects of the socket (2). Later the patient was asked to look directly at a fixed point 6 feet away at the level of the eye. This allows impression of the site with the muscles in a neutral gaze position (5).

The impression was used to pour a two piece split cast mould (2, 6). After the stone set, the two parts of the split cast were separated and the impression material along with the tray was removed.

In order to prepare the wax pattern for the scleral prosthesis, the inner surface of the mould was coated with separating medium. Inlay wax was heated and molten wax was poured into the mold. Additional wax was poured to compensate for the wax shrinkage. Then mold was opened to retrieve the wax pattern. Wax sprue and sharp edges were removed and recontoured into a smooth hemispheroid. The wax pattern should be highly polished and free from dust and debris before placing it in the socket.

At the time of try-in of scleral wax pattern, the author:

- checked for any area of discomfort or pressure points and relieve them;
- checked the eye contour and lid configuration from different angles, with the patients eyes open and by manual palpation with the eyes closed (7);
- centered the height of convexity over the pupil, usually slightly medial to the midline between the inner and outer canthi;
- checked the eyelids that should close completely over the wax pattern;
- checked that contours and palpebral fissure that should resemble the adjacent natural eye (6). Observed the fit of the wax pattern;

The size of the iris was determined and marked on the wax pattern using the normal eye as a guide (2, 7).

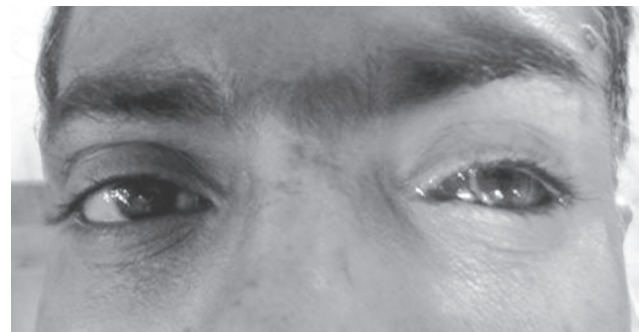A close-up photograph of the patients natural eye was taken to determine the colour of cornea. A stock prosthesis having a cornea of similar size and colour was selected and the cornea was cut of it using acrylic trimmer (7, 8). This cornea was then placed on the pre-determined position in the wax pattern such that the margins of cornea were flush with the wax pattern (Figure 3) and the wax pattern was tried in (Figure 4).

Shade selection of the sclera was done using the natural eye as a guide. The patient had a diffused redness in the normal eye showing more veins than usual, which needed to be duplicated in the prosthesis (8, 9). Later the waxed up prosthesis was invested in an ocular flask (Figure 5). To stabilize the corneal button into plaster, a small handle of autopolymerizing acrylic was attached to it, which prevented its

displacement during dewaxing. Processing was done in a manner similar to the normal denture processing using a long curing cycle with heat cure tooth coloured resin.



**Figure 3** - Waxed up prosthesis with cornea



**Figure 4** - Try-in process



**Figure 5** - Flasking in an ocular flask

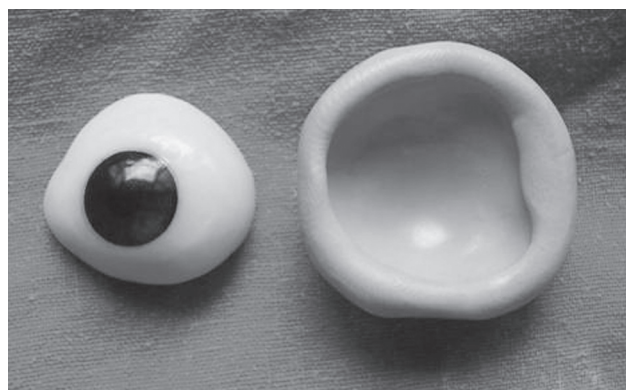
The acrylized prosthesis was then retrieved from the flask and trimmed to remove the acrylic handle and all irregular and sharp surfaces (Figure 6).



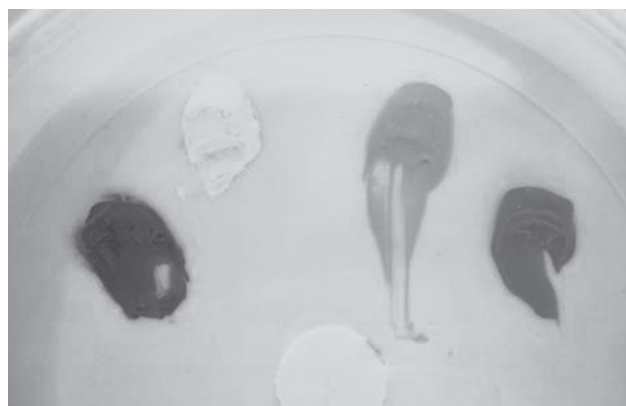
**Figure 6** - Acrylized prosthesis

At this stage the prosthesis needed to be customized to give it a life like appearance (10). This is the most important step of the entire procedure and it requires an artistic flair on the part of the dentist/ technician. First a putty impression (Aquasil™, Dentsply) of the prosthesis was made (to be used later as a reference for original contour). Acrylic resin was removed to a depth of 1 mm around the corneal button of the prosthesis with an acrylic trimmer. A combination of yellow, red and orange oil paint (Figure 7) was applied on the trimmed surface to simulate the colour of the natural eye (Figure 8) using photograph of the normal eye as a guide. The colours were selected and mixed using monomer as the thinning agent. To simulate blood vessels, red satin strands were placed. One needs to hone their artistic skills to match the adjacent eye and simulate a natural appearance.

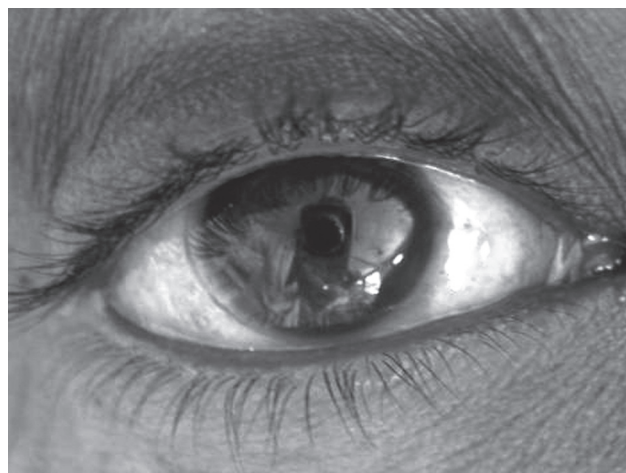Then autopolymerizing clear acrylic resin was mixed, placed on the painted surface and the prosthesis was replaced in the putty impression to regain the original contour of the surface. After the acrylic polymerizes, the prosthesis was trimmed, polished and finished. At the time of insertion, aesthetics, fit and the movement of the prosthesis were assessed (Figure 9) (7).



**Figure 7** - Putty impression of acrylized prosthesis



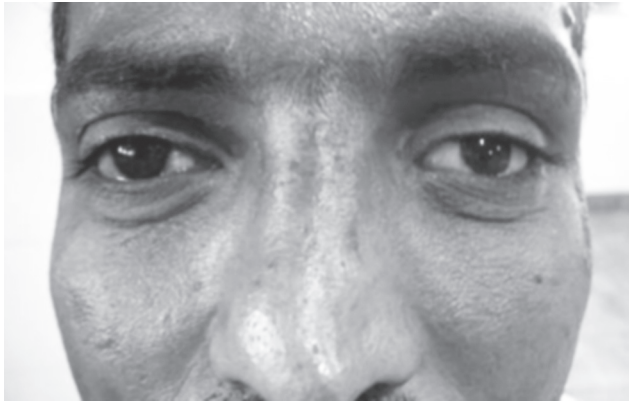**Figure 8** - Oil paint used



**Figure 9** - Right normal eye used as a guide

As the patients demand for the aesthetics of the prosthesis were exacting and his wish to avoid wearing tinted glass spectacles (normally patient is

advised to wear tinted glasses to prevent slight color mismatch with the natural eye) was accepted before starting the treatment, painting of the scleral region was redone twice to the patients satisfaction and for a normal appearance (Figure 10).



**Figure 10** - After treatment appearance

Post insertion instructions included regular removal and cleaning of the prosthesis with a ophthalmic irrigation solution (10).

In this case we were able to meet the aesthetic requirement of the patient satisfactorily. The patient demonstrated excellent ocular movement (Figures 11A and 11B).

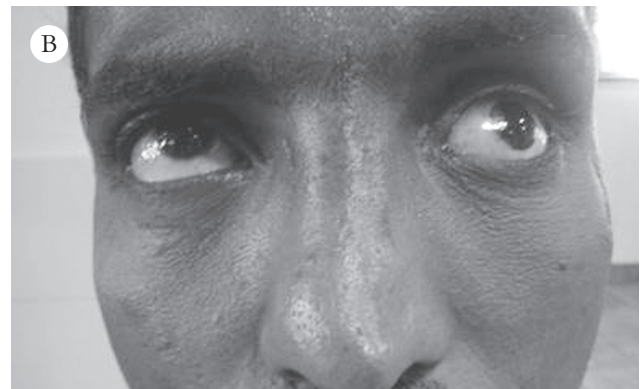## Discussion and conclusion

Loss of any part of the face inflicts both physical and psychological trauma to the patient. Replacement of these lost parts is often warranted not only to prevent supporting tissue changes but also to avoid distress to the patient. One needs to be a little artistic and very innovative to treat such patients, utilizing the available materials and techniques. A thorough knowledge of the regional anatomy and recent developments in the field is prudent. Above all empathy towards the patients condition must be present.

## Conflict of interest

The author declares no conflict of interest.

Publication of the case was approved by the Ethical Committee of the Institution.



**Figure 11A and 11B** - Demonstration of eye movement

## Acknowledgements

Dr K. Kamalakanth Shenoy, HOD & professor Dept of Prosthodontics, Yenepoya Medical and Dental College, Mangalore;

Dr Sanath Shetty, professor, Department of Prosthodontics, Yenepoya Medical and Dental College, Mangalore;

Dr Srivatsa G. HOD & professor Dept of Prosthodontics, KLE Dental College and Hospital.

## References

1. Taylor TD. Clinical maxillofacial prosthetics. Carol Stream: Quintessence; 2000.
2. Beumer J, Curtis TA, Firtell DN. Maxillofacial rehabilitation: prosthodontic and surgical consideration. Los Angeles: Mosby; 1979.
3. Bailey CS, Buckley RJ. Ocular prostheses and contact lenses-1 cosmetic devices. Br Med J. 1991;302(6783):1010-2.

4. Barlett SO, Moore DJ. Ocular prosthesis: a physiologic system. J Prosthet Dent. 1973;29(4):450-9.
5. Allen L, Webster HE. Modified impression method of artificial eye fitting. Am J Ophthalmol. 1969;67(2):189-218.
6. Brown KE. Fabrication of an ocular prosthesis. J Prosthet Dent. 1970;24(2):225-35.
7. Benson P. The fitting and fabrication of a custom resin artificial eye. J Prosthet Dent. 1977;38(5):532-8.
8. Firtell DN. Coordination of iris sizes in ocular prostheses. J Prosthet Dent. 1975;34(4):334-5.
9. Firtell DN, Anderson CR, Donnan ML. Vein application technique for ocular prostheses. J Prosthet Dent. 1975;34(4):192-4.
10. Parr GR, Goldman BM, Rahn AO. Post insertion care of the ocular prosthesis. J Prosthet Dent. 1983;49(1):220-4.

Received: 02/17/2010

*Recebido:* 17/02/2010

Approved: 03/25/2010

*Aprovado:* 25/03/2010