



## Bart Syndrome: a rare entity

### *Síndrome de Bart: uma entidade rara*

**Chitreddy Uma Reddy<sup>[a]</sup>, Komar Suresh Reddy<sup>[b]</sup>, Jaddu Jyothirmai Reddy<sup>[c]</sup>**

<sup>[a]</sup> BDS, MDS, professor, Department of Oral Medicine & Radiology, Adesh Institute of Dental Sciences and Research, Barnala Road, Bathinda, Punjab - India.

<sup>[b]</sup> BDS, MDS, professor, Department of Oral and Maxillofacial Surgery, Manasarovar Dental College, Bhopal, Madhya Pradesh - India.

<sup>[c]</sup> BDS, MDS, senior lecturer, Department of Preventive and Community Dentistry, Darshan Dental College & Hospital, Ranakpur Road, Loyara, Udaipur, Rajasthan - India, e-mail: drjoe0802@gmail.com

---

#### Abstract

**Introduction:** Bart Syndrome is a rare inherited skin blistering disorder. It is also known as congenital transient mechano-bullous dermatosis and is one of the lesser known presentations of epidermolysis bullosa (EB). **Case report:** The objective of this report is to present a case of Bart Syndrome in a 3 day old newborn female baby. The skin lesions showed denuded areas with bullae rupturing easily to reveal painful eroded areas. Eroded lesions were distributed over the hands, feet, chest and on the face over the cheeks bilaterally. The lips were erythematous, eroded with tissue tags. Eroded, crusted lesions were seen on the labial mucosa and anterior palate. Histopathological examination revealed split localized to the epidermis. The epidermal layer above the split appeared to be normal. The basement membrane was intact, along with normal underlying connective tissue. **Discussion:** Management consisted of decompression of blisters followed by topical antibiotics. Oral corticosteroids were given for control of blistering, since they reduce collagenase activity. Avoidance of trauma is essential aspect of management: baby was nursed with care to prevent occurrence of new lesions. Therapy and counseling sessions were scheduled for the parents.

**Keywords:** Bart Syndrome. Epidermolysis Bullosa Dystrophica. Transient bullous dermolysis of the newborn. Oral manifestations.

**Resumo**

**Introdução:** A Síndrome de Bart é uma rara desordem hereditária cutânea bolhosa. Também conhecida com dermatose congênita transitante mecano-bolhosa, é uma das apresentações menos conhecidas de epidermólise bolhosa (EB). Relato de caso: O objetivo deste relato é apresentar um caso de Síndrome de Bart em um neonato (com três dias) do sexo feminino. As lesões de pele caracterizavam-se por áreas desnudas com lesões bolhosas de rompimento fácil, revelando áreas erodidas dolorosas. As lesões erodidas estavam distribuídas pelos pés, mãos, peito e face, sobre as regiões malares. Os lábios estavam eritematosos e erodidos. Lesões erodidas e crostosas foram observadas na mucosa labial e no palato anterior. O exame histopatológico revelou fenda localizada na epiderme. A camada epidérmica acima da fenda apresentava normalidade. A membrana basal estava intacta e o tecido conjuntivo subjacente normal. Discussão: O tratamento das lesões consistiu na descompressão das bolhas seguida de uso de antibióticos tópicos. Foram administrados corticosteróides orais, para controle das lesões bolhosas, uma vez que estes reduzem a atividade da colagenase. Evitar o trauma é um aspecto essencial no tratamento desses casos. Assim, o bebê era manejado com cuidado para evitar novas lesões. Foram agendadas sessões de terapia e aconselhamento aos pais.

**Palavras-chave:** Síndrome de Bart. Epidermólise bolhosa distrófica. Dermólise bolhosa transitória do neonato. Manifestação oral.

**Introduction**

Bart Syndrome or congenital transient mechano-bullous dermatosis is one of the lesser known presentations of epidermolysis bullosa (EB) (1). It is a rare inherited skin blistering disorder. It is an autosomal dominant inheritance, caused by mutation in the collagen type VII gene on chromosome 3p. It is characterized by congenital skin defects with bullae of the extremities and intertriginous areas, congenital localized absence of skin anterior aspect of lower extremities and dorsa of the feet, erosions of mouth and dystrophic nails. All of these features are remitted within a few years (2).

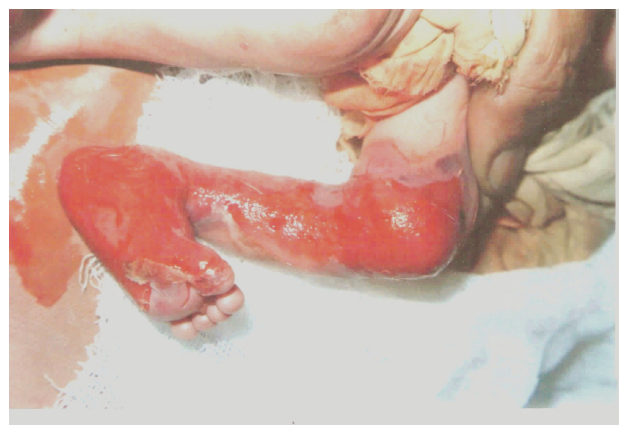**Case report**

A female newborn aged 3 days old was admitted to the neonatal ward of Dermatology Department, Adesh Institute of Medical Sciences and Research, Bathinda, Punjab, India, with chief complaint of erosions of the legs and difficulty in feeding. Hence an oral diagnostician was called upon.

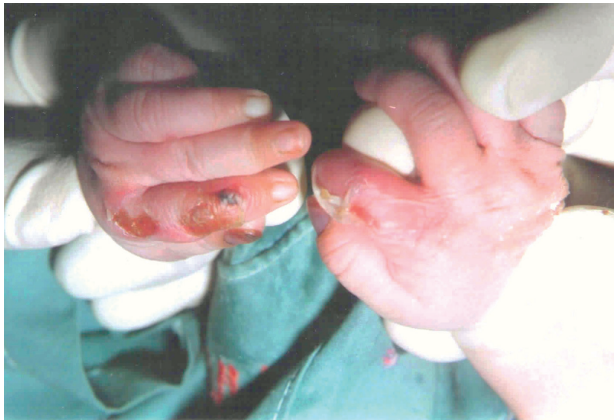A detailed case history revealed positive family history; maternal uncle had history of EB. On examination it was observed that eroded lesions were distributed over the hands, feet, and chest and on the face over the cheeks bilaterally. The skin lesions showed denuded areas with bullae rupturing easily

to reveal painful eroded areas. The entire medial aspect of the left leg showed raw eroded skin extending from the knee to the toes (Figure 1). The ruptured bullae were also distributed over the chest, face and hands (Figure 2). The nails showed dystrophic changes. The lips were erythematous, eroded with tissue tags (Figure 3). On intraoral examination, the entire labial mucosa showed eroded, crusted lesions. Intra oral blisters were seen over anterior palate which subsequently ruptured to form erosions.

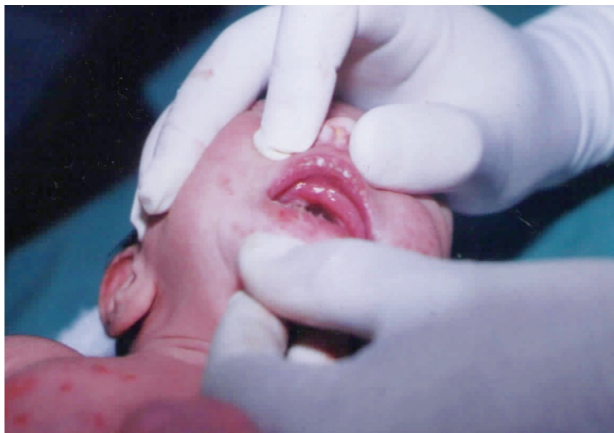Based on the above findings, provisional diagnosis of EB was given. Routine blood investigations revealed raised erythrocyte sedimentation rate (ESR). A blister was induced by rubbing normal looking



**Figure 1** - Clinical presentation: denuded areas with raw eroded skin extending from the knee to the toes involving the entire medial aspect of the left leg



**Figure 2** - Clinical presentation: denuded areas distributed over the hands



**Figure 3** - Clinical presentation: erythematous, eroded lips with tissue tags. Also seen are eroded, crusted lesions on the entire labial mucosa

skin for one minute. The skin biopsy was taken from the area after 10 min. Histopathological examination revealed split localized to the epidermis. The epidermal layer above the split appeared to be normal. The basement membrane was intact, along with normal underlying connective tissue, suggestive of EB (Figure 4).

The above clinical findings of bullae of skin, oral mucosa and dystrophic nails and histopathological findings helped arrive at the final diagnosis of Bart Syndrome.

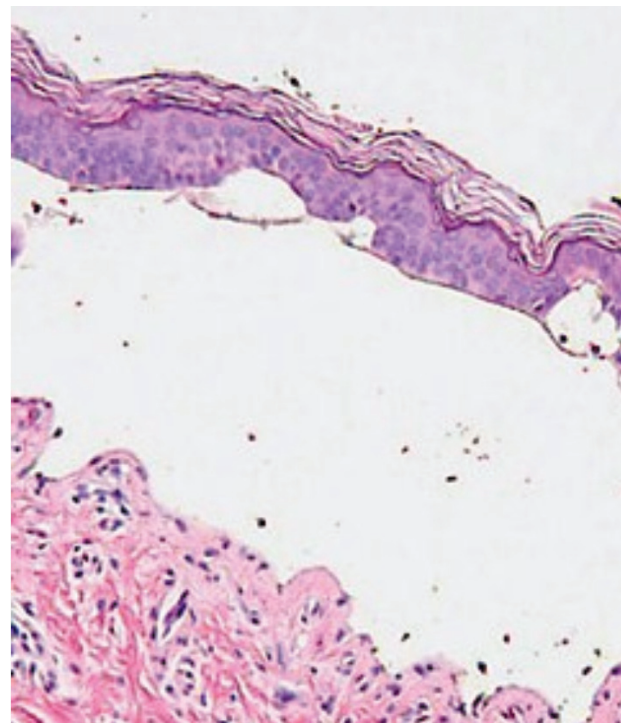
#### Management

The patient was given dressing over the left leg, along with topical antibiotic cream. Oral

corticosteroids were given for control of blistering, since they reduce collagenase activity. Therapy and counselling sessions were scheduled for the parents. Genetic counselling is an essential part of management of families in whom there is an individual with EB. Skin care instructions were as follows: the baby was nursed on a foam mattress one inch in thickness. New bullae were drained by puncturing them with a sterile needle and roof left *in situ*. The baby was bathed in warm water containing a little potassium permanganate. Vaseline gauze was applied to the eroded areas. Avoidance of trauma is essential aspect of management, baby nursed with care to prevent occurrence of new lesions.

#### Discussion

The term 'epidermolysis bullosa' was first coined by Koebner. Hallopeau was the first to distinguish between simple (non-scarring) and dystrophic (scarring) forms of the disease. Bart Syndrome was originally described in a large family in 1966 by Bart (3).



**Figure 4** - Histologic features: split localized to the epidermis, intact basement membrane along with normal underlying connective tissue (H&E stain;  $\times 100$ )

Bart Syndrome is a triad of bullous involvement of cutaneous, oral lesions and dystrophic nails. The onset is at birth or in early infancy. Mechanical trauma experienced during delivery may lead to bullae and erosions at the sites of trauma. The common sites are hand, feet and other areas of friction including oral mucosa. Blistering is usually worse in summer and in absence of secondary infection, heals without scarring. Oral ulcers formed as a result of rupture of bullae heal without remarkable sequelae, may develop in the newborn due to vigorous sucking (4).

Though its etiology is unknown, it is believed to be an autoimmune disorder. The antigen is type VII collagen, a 290 KD glycoprotein which is specifically found in basement membranes beneath stratified squamous epithelia (5-7). Physical trauma in utero has also been proposed as a mechanism to explain denuded areas of the limbs (2).

A detailed history should include (8):

- 1) mapping of the family pedigree;
- 2) evidence of consanguinity;
- 3) age of onset;
- 4) seasonal effects;
- 5) fever: shows extent of disease activity;
- 6) cutaneous findings.

Differential diagnosis can be Bullous pemphigoid, Bullous lichen planus, Cicatricial pemphigoid (9). Histopathological examination of the skin biopsy localizes the split to the epidermis (EB simplex) or the basement membrane zone (junctional and dystrophic EB). Bart Syndrome can present as simplex, junctional or dystrophic forms. Electron microscopy can differentiate between EB simplex (intraepidermal split), junctional EB (intra lamina lucida) and dystrophic EB (sub lamina lucida) (10). Specific antibodies to antigen, type VII collagen can be found by immunofluorescence techniques (11). The form of EB in this case was simplex. Only histopathologic examination by light microscopy was done. EB simplex has onset in childhood or in adult life. Lesions are exacerbated in warm weather. These lesions usually heal without scarring and secondary infection is a common complication. Prognosis of EB simplex is favourable. Oral lesions occur immediately after first feed over palate, tongue and labial mucosa in junctional EB. The bullae rupture to form widespread erosions.

Gastrointestinal tract involvement shows blistering from oesophagus to large intestine leading to pyloric stenosis. This impairs calorie intake causing anaemia and growth retardation. Laryngeal oedema causes asphyxia. Prognosis is grave. Dystrophic EB is characterised by generalized blistering and erosions which heal with atrophy, scarring and milia formation. Squamous cell carcinoma occasionally develops at the site of chronic trauma. Prognosis is unfavourable (4).

Management of this syndrome consists of prevention of trauma, a cool environment and decompression of blisters followed by topical antibiotics.

- a) In neonates blisters are punctured with a sterile needle, bathed in warm water containing a little amount of potassium permanganate. Vaseline gauze is applied to eroded areas. If infected, an antibiotic cream is used.
- b) In older infants and toddlers erosions are covered with topical antiseptics such as 10% povidine iodine or 1% silver sulfadiazine cream (4).

Systemic treatment modalities include oral corticosteroids in high doses for control of blistering in both dystrophic and junctional EB. They reduce collagenase activity of fibroblasts. Retinoic acid inhibits collagenase production. 13-cis-retinoic acid at a dose of 0.4 mg/kg/day reduces the number of lesions. A daily dose of 300-1000 IU of Vitamin E diminishes blister formation (12). Phenytoin can be used in recurrent and junctional EB at a dose 100-300 mg once daily for 6-8 weeks (13, 14). This decreases at least 50% of bullous lesions. It acts by decreasing synthesis of collagenase (15).

Partial thickness skin autografts may be used for reconstructive surgery in neonates affected by severe forms of EB (4).

## Conclusions

Oral professionals have their role in the diagnosis and management of Bart Syndrome. Recognizing the oral clinical features and the prompt management is important.

## References

1. Patrizi A, Pauluzzi P, Dalla Casa P, Badiali de Giorgi L. Congenital transient mechanobullous dermatosis (Bart's Syndrome). A clinical case and review of literature. *G Ital Dermatol Venereol*. 1989;124(10):447-50.
2. Duran-McKinster C, Rivera-Franco A, Tamayo L, de la Luz Orozco-Covarrubias M, Ruiz-Maldonado R. Bart syndrome: the congenital localized absence of skin may follow the lines of Blaschko. Report of six cases. *Pediatr Dermatol*. 2000;17(3):177-82.
3. Gutzmer R, Herbst RA, Becker J, Kiehl P, Bisping-Kuske C, Bohnhorst B, et al. Bart Syndrome-separate entity or a variant of epidermolysis bullosa? *Hautarzt*. 1997;48(9):640-4.
4. Fernandes RJ, Valia AR, Patnage V. Epidermolysis bullosa (EB): vesicubullous disorders. In: Valia RG. *IADVL Textbook and Atlas of Dermatology: volume 2*. Mumbai: Bhalani Publishing House; 1994. p. 777-99.
5. Woodley DT, Burgeson RE, Lunstrum G, Bruckner-Tuderman L, Reese MJ, Briggaman RA. The epidermolysis bullosa acquisita antigen is the globular carboxyl terminus of type VII procollagen. *J Clin Invest*. 1988;81(3):683-7.
6. Shimizu H, McDonald JN, Gunner DB, Black MM, Bhogal B, Leigh IM, et al. Epidermolysis bullosa acquisita antigen and the carboxy terminus of type VII collagen have a common immunolocalization to anchoring fibrils and lamina densa of basement membrane. *Br J Dermatol*. 1990;122(5):577-85.
7. Woodley DT, Briggaman RA, Gammon WR. Acquired epidermolysis bullosa: a bullous disease associated with autoimmunity to type VII (anchoring fibril) collagen. *Dermatol Clin*. 1990;8(4):717-26.
8. Shelly WB, Shelly ED. *Advanced dermatological diagnosis*. Philadelphia: WB Saunders Company; 1992. p. 503-4.
9. Gammon WR, Kowalewski C, Chorzelski TP, Kumar V, Briggaman RA, Beutner EH. Direct immunofluorescence studies of sodium chloride-separated skin in the differential diagnosis of bullous pemphigoid and epidermolysis bullosa acquisita. *J Am Acad Dermatol*. 1990;22(4):664-70.
10. Nioboer C, Boorsma DM, Woerdeman MJ, Kalsbeek GL. Epidermolysis bullosa acquisita. Immunofluorescence, electron microscopic and immunoelectron microscopic studies in four patients. *Br J Dermatol*. 1980;102(4):383-92.
11. Smoller BR, Woodley DT. Differences in direct immunofluorescence staining patterns in epidermolysis bullosa acquisita and bullous pemphigoid. *J Am Acad Dermatol*. 1992;27(5 Pt 1):674-8.
12. Michaelson JD, Schmidt JD, Dresden MH, Duncan WC. Vitamin E in treatment of epidermolysis bullosa. Changes in tissue collagenase levels. *Arch Dermatol*. 1974;109(1):67-9.
13. Bauer EA, Cooper TW. Therapeutic considerations in recessive dystrophic epidermolysis bullosa. *Arch Dermatol*. 1981;117(9):529-30.
14. Rogers RB, Yancey KB, Allen BS, Guill MF. Phenytoin therapy for junctional epidermolysis bullosa. *Arch Dermatol*. 1983;119(11):925-6.
15. Cooper TW, Bauer EA. Therapeutic efficacy of phenytoin in recessive dystrophic epidermolysis. A comparison of short- and long-term treatment. *Arch Dermatol*. 1984;120(4):490-5.

Received: 02/01/2011

Recebido: 01/02/2011

Approved: 02/28/2011

Aprovado: 28/02/2011