
CARNOY'S SOLUTION OVER THE INFERIOR ALVEOLAR NERVE AS A COMPLEMENTARY TREATMENT FOR KERATOCYSTIC ODONTOGENIC TUMORS

Aplicação da solução de Carnoy sobre o nervo alveolar inferior como tratamento complementar para o tumor odontogênico ceratocístico

Ophir Ribeiro Júnior¹, Alexandre Meireles Borba¹,
Carlos Augusto Ferreira Alves¹, Jayro Guimarães Júnior²

¹ DDS, MsC graduate student, Oral Diagnosis Faculty of Dentistry of the University of Sao Paulo, USP, Sao Paulo, SP - Brazil, e-mail: ophirrij@usp.br; ophirrij@ig.com.br

² DDS, PhD, Professor of Oral Diagnosis Faculty of Dentistry of the University of Sao Paulo, USP, Sao Paulo, SP - Brazil.

Abstract

Carnoy's solution is a substance used as a complementary treatment after the conservative exeresis of a ceratocístico odontogenic tumor. The application of Carnoy solution promotes a superficial chemical necrosis and is intended to reduce recurrence rates. However, the inferior alveolar vascular-nervous plexus can occasionally be exposed after the removal of a lesion. The safety of the application of Carnoy solution over this plexus has been reported on, but to date, no clinical report has been made. The authors present two cases that were given Carnoy solution over the inferior alveolar vascular-nervous plexus as a complementary treatment for the keratocystic odontogenic tumor. Effective control of recurrence with low and transient neural morbidity was suggested with this technique.

Keywords: Odontogenic tumors; ceratocístico odontogenic tumor; Recurrence; Paresthesia; Mandibular nerve.

Resumo

A solução de Carnoy é usada como tratamento complementar após a exérese conservadora do tumor odontogênico ceratocístico. A aplicação da solução de Carnoy promove uma necrose química superficial e espera-se uma redução das taxas de recorrência. Entretanto, o plexo vasculo-nervoso alveolar pode ocasionalmente ser exposto após a remoção da lesão. A segurança da aplicação da solução de Carnoy sobre este plexo tem sido relatada. Porém, até o momento não foi relatado nenhum caso clínico. Os autores apresentam dois casos nos quais foi aplicada a solução de Carnoy sobre o feixe vâsculo-nervoso mandibular como tratamento complementar para o tumor odontogênico ceratocístico. O controle efetivo da recorrência com baixa e transitória morbidade é sugerido com o uso desta técnica.

Palavras-chave: Tumores odontogênicos; Tumor odontogênico ceratocístico; Recorrência; Parestesia; Nervo mandibular.

INTRODUCTION

Carnoy's solution, composed of 3ml of chloroform, 6ml of absolute ethanol, 1ml of glacial acetic acid and 1g of ferric chloride, is often used as a complementary treatment of lesions with high recurrence rates, such as the keratocystic odontogenic tumor (KOT) (1-5). Occasionally, soft tissues might be adjacent to the lesion; for example, in cases in the posterior region of the mandible, the inferior alveolar vascular-nervous plexus might be exposed after removal of the lesion. Complementary treatment involves treatment of the remnant surgical bed. In this example, Carnoy's solution can be applied to the vascular-nervous plexus of the mandibular canal when a fenestration exposes it to the surgical bed (although some paresthesia may be a side effect). Studies have already reported on the safety of the application of Carnoy solution over a nerve, but to date, no clinical report has been made (3-6).

The aim of this paper is to report two cases of patients that presented mandibular KOT and were treated with Carnoy solution over the inferior alveolar plexus without any definitive damage to lip sensitivity.

Case 1

A thirty-year-old woman was referred for an evaluation of an osteolytic lesion in the left mandibular ramus. A panoramic radiographic image showed a radiolucent, multilocular, well-defined lesion associated with the crown of an impacted third molar extending to the roots of the second molar (Figure 1).

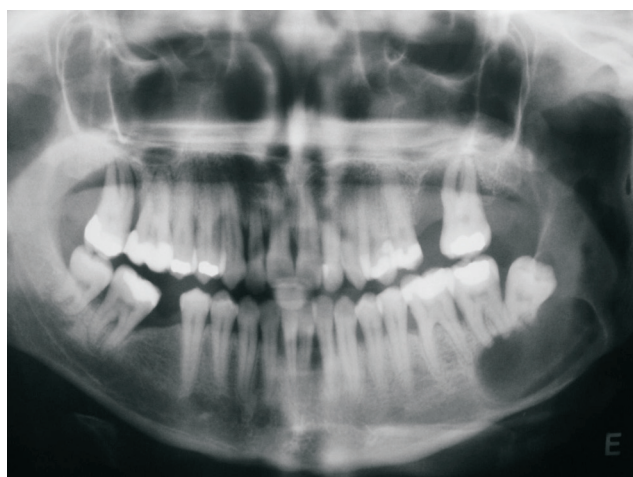

FIGURE 1 - Preoperative panoramic radiograph

Computed tomography (CT) displayed fenestration of the mandibular canal and the lingual cortex (Figure 2).

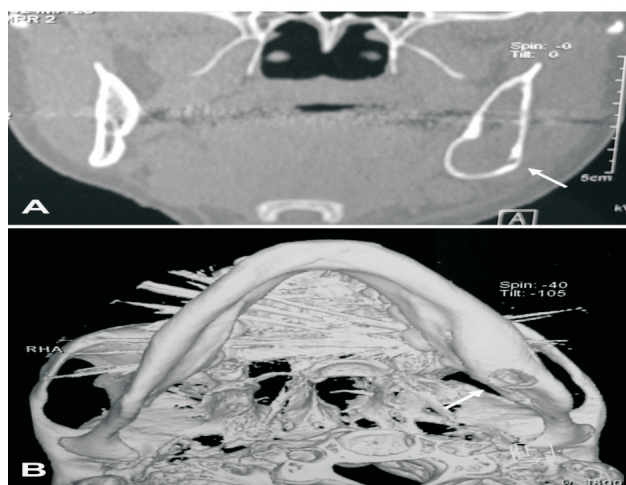


FIGURE 2 - Preoperative computed tomography
A: Fenestration of the mandibular canal (arrow)
B: Fenestration of the lingual cortical (arrow)

Suspicion of a KOT was raised, and KOT was histologically confirmed after incisional biopsy. Enucleation of the lesion by submandibular approach and removal of the second and third molar were accomplished under general anesthesia. Soft tissues adhered to the capsule of the lesion in the lingual fenestration were also removed. In the proximity of the mandibular canal, the capsule of the lesion was dissected from the inferior alveolar plexus. Then peripheral ostectomy of the whole surgical bed was completed, followed by a single application of Carnoy solution, including over the inferior alveolar plexus (Figure 3).

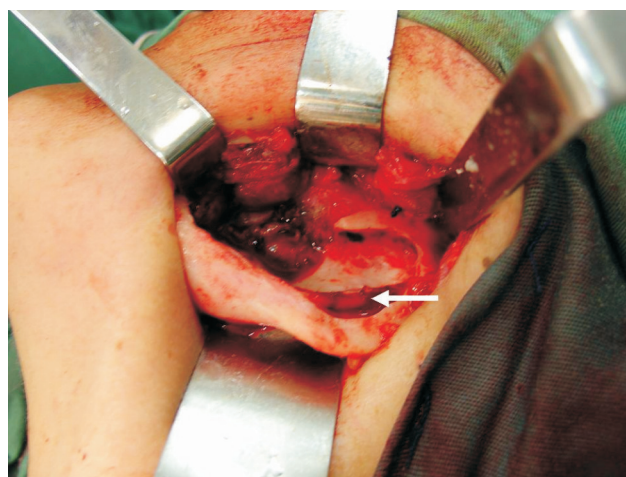


FIGURE 3 - Surgical bed after peripheral ostectomy and application of Carnoy solution; note the inferior alveolar neurovascular bundle (arrow)

In the immediate postoperative period, the patient presented with paresis of the lower lip, which had a total regression after nine months. After a period of 36 months, no sign of recurrence was observed (Figure 4).

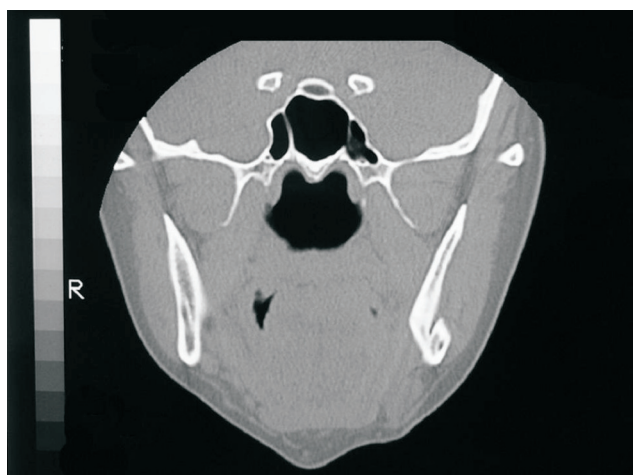

FIGURE 4 - Postoperative computed tomography (36 months)

Case 2

A thirty-three-year-old male returned for follow-up after removal of a KOT two years before. At that time, the lesion was treated by enucleation through a submandibular approach, and the surgical bed was complementarily treated by peripheral ostectomy. The follow-up panoramic radiography showed a multilocular radiolucent image in the right mandibular ramus, suggesting a recurrence. To confirm the suspicion, an aspiration puncture was performed; it revealed dense white fragments like keratin mixed with a sanguinolent and cyst-like liquid. Computed tomography showed the extent of the lesion.

Under general anesthesia, the second intervention was accomplished by an intra-oral approach. Fenestration of the mandibular canal was observed after the enucleation of the lesion, suggesting possible contact of the lesion with the inferior alveolar plexus. After peripheral ostectomy, a single application of Carnoy solution in the whole surgical bed, including the exposed plexus, was performed. The histological diagnosis of the lesion confirmed the suspicion of KOT.

The patient presented temporary paresis of the lower lip, with total regression after six months. After 32 months of follow-up from the second intervention, there were no signs of recurrence.

DISCUSSION

Carnoy solution was first used as a fixative in the 19th century. Late in the last century, it started to be applied after the removal of the KOT in the remaining cavity. It promotes chemical necrosis of up to 1.5mm and elimination of epithelial remnants and possible microcysts (3). The use of this solution is intended to diminish the recurrence rates such that they are similar to those for resection, and to cause lower morbidity (5).

The effects in the inferior alveolar nerve were first reported by Frerich et al. in 1994 (6). The authors applied the substance in the inferior alveolar nerve of rabbits and did not observe axonal damage during the first three minutes of direct application². In contrast, another important study, Wolgen et al. (7), noted that the alterations in neural conductivity developed after two minutes of direct application, with few signs of recovery after two weeks of follow-up. However, there was no mention on how long the solution was left in contact with the nerve, an important point that has been questioned (7).

Previous studies have not correlated the lab findings during the application of Carnoy solution over neural tissue with the clinical results; however, in this case report, we showed that when a proper protocol is followed, the chemical treatment of the nerve can be accomplished without permanent functional damage. In both cases, the sensitive alteration was transitory and compatible with the lab findings described earlier (3, 6). Forssell (8) and Forssell et al. (9) demonstrated increased recurrence rates in the first three years with much lower recurrences after that period, suggesting that the first few years are critical for the follow-up. The cases presented here were followed-up around this time period. Even though they will still need life-long follow-up, good prognoses can be expected, and data from continuous case series are encouraging.

We prefer to apply Carnoy solution after a slight peripheral ostectomy over the remaining bone surgical bed. This promotes mechanical regularization of the bone cavity as well as the mechanical removal of any soft tissue left behind, decreasing the likelihood of a recurrence. The solution is applied for three minutes in the cavity using imbibed gauze, while taking care to protect the adjacent soft tissues. When the nerve is exposed in the cavity, the application is performed only once (4-6).

REFERENCES

1. Blanas N, Freund B, Schwartz M, Furst IM. Systematic review of the treatment and prognosis of the odontogenic keratocyst. *Oral Surg Oral Med Oral Pathol Oral Radiol Endod.* 2000;90(5):553-558.
2. Hellstein J, Hopkins T, Morgan T. The history and mystery of Carnoy solution: an assessment of the need for chloroform. *Oral Surg Oral Med Oral Pathol Oral Radiol Endod.* 2007;103(4):524.
3. Loescher AR, Robinson PP. The effect of surgical medicaments on peripheral nerve function. *Br J Oral Maxillofac Surg.* 1998;36(5):327-332.
4. Stoelinga PJ. The treatment of odontogenic keratocysts by excision of the overlying, attached mucosa, enucleation, and treatment of the bony defect with carnoy solution. *J Oral Maxillofac Surg.* 2005;63(11):1662-1666.
5. Zhao YF, Wei JX, Wang SP. Treatment of odontogenic keratocysts: a follow-up of 255 Chinese patients. *Oral Surg Oral Med Oral Pathol Oral Radiol Endod.* 2002;94(2):151-156.
6. Frerich B, Cornelius CP, Wietholter H. Critical time of exposure of the rabbit inferior alveolar nerve to Carnoy's solution. *J Oral Maxillofac Surg.* 1994;52(6): 599-606.
7. Wolgen P. Re: Loescher & Robinson. The effect of surgical medicaments on peripheral nerve function. *Br J Oral Maxillofac Surg.* 1999;37(3):247.
8. Forssell K. The primordial cyst: a clinical and radiographic study. *Proc Finn Dent Soc.* 1980;76(3):129-174.
9. Forssell K, Forssell H, Kahnberg KE. Recurrence of keratocysts: a long-term follow-up study. *Int J Oral Maxillofac Surg.* 1988;17(1):25-28.

Received: 07/08/2007

Recebido: 08/07/2007

Accepted: 08/15/2007

Aceito: 15/08/2007