

---

# FRONTAL SINUS FRACTURE: superciliary surgical approach

## *Fratura de seio frontal: acesso cirúrgico superciliar*

Ophir Ribeiro Júnior<sup>1</sup>, Alexandre Meireles Borba<sup>2</sup>, Marcia Maria de Gouveia<sup>3</sup>,  
Carlos Augusto Ferreira Alves<sup>4</sup>

<sup>1</sup> Former Resident, Oral and Maxillofacial Surgery, University Hospital, University of São Paulo, São Paulo, SP - Brasil, e-mail: ophirj@usp.br

<sup>2</sup> Former Resident, Oral and Maxillofacial Surgery, University Hospital, University of São Paulo, São Paulo, SP - Brasil.

<sup>3</sup> Assistant Surgeon, Oral and Maxillofacial Program, University Hospital, University of São Paulo, São Paulo, SP - Brasil.

<sup>4</sup> Assistant Surgeon, Oral and Maxillofacial Surgery Program, University of São Paulo, São Paulo - Brasil.

---

### Abstract

Frontal sinus fractures are generally accessed by the coronal or the *gull-wing* approach, depending of the extension and the complexity of the fractures lines. The latter one, in spite of being fast and objective in smaller fractures, presents the main disadvantage of a poor aesthetic result. The superciliary approach is presented and illustrated in a clinical case as an objective and cosmetically efficient option for the treatment of small anterior frontal sinus wall fractures, having the criteria for indication and the technique described throughout the article.

**Keywords:** Skull fractures; Facial bones; Frontal bone; Oral surgery.

### Resumo

*Fraturas do seio frontal geralmente são abordadas pelo acesso coronal ou pelo acesso tipo "asa de gaiivota", dependendo da extensão e da complexidade dos traços de fratura. Esse último, embora rápido e objetivo em fraturas de menor extensão, apresenta pobre resultado cosmético da cicatriz cirúrgica como principal desvantagem. O acesso superciliar é apresentado e ilustrado em um caso clínico, como opção objetiva e cosmeticamente eficaz no tratamento de pequenas fraturas da parede anterior do seio frontal. Seus critérios de indicação e seus princípios técnicos são discutidos no artigo.*

**Palavras-chave:** Fraturas cranianas; Ossos faciais; Osso frontal; Cirurgia bucal.

## INTRODUCTION

The frontal sinuses are pneumatic cavities that together with the other paranasal sinuses, are responsible for warming and moistening of the inhaled air, for the resound of sound waves emitted by the vocal cords and for diminishing the head's weight. Each frontal sinus communicate with the nasal cavity through the frontonasal duct, draining in the lower meatus. Within this cavity the frontal sinuses are indirectly related to the other sinuses. Another function of the frontal sinus is to protect the brain against traumas to the superior third of the face.

Sinus wall fractures can cause several signs and symptoms that vary according to the extent of the lesion, including frontal depression, epistaxis, nasal obstruction and possible neurological alterations. Fractures of the anterior wall with displacement are surgically treated by reduction and fixation of the viable fragments and substitution of the comminuted areas by alloplastic materials.

The approach of these fractures can be accomplished by the coronal incision, if a major

exposition is necessary, by the local wounds or by the "bat wing" approach (1, 2). Even though the "bat wing" approach is faster and more objective in small fractures, the resulting poor cosmetic result generally leads to the coronal approach.

The authors present the superciliary approach as an objective and cosmetically efficient option for the treatment of anterior wall frontal sinus fractures, illustrating its use with a case report.

## CASE REPORT

A 29-years-old man had a traffic accident and was brought to evaluation in the emergency room of the University Hospital of the Universidade de São Paulo, Brazil. The patient presented signs of trauma to left frontal region. He was conscious and a clinical examination revealed no signs of neurologic problems. Computed tomography showed a fracture of the anterior wall of the left frontal sinus (Figure 1).

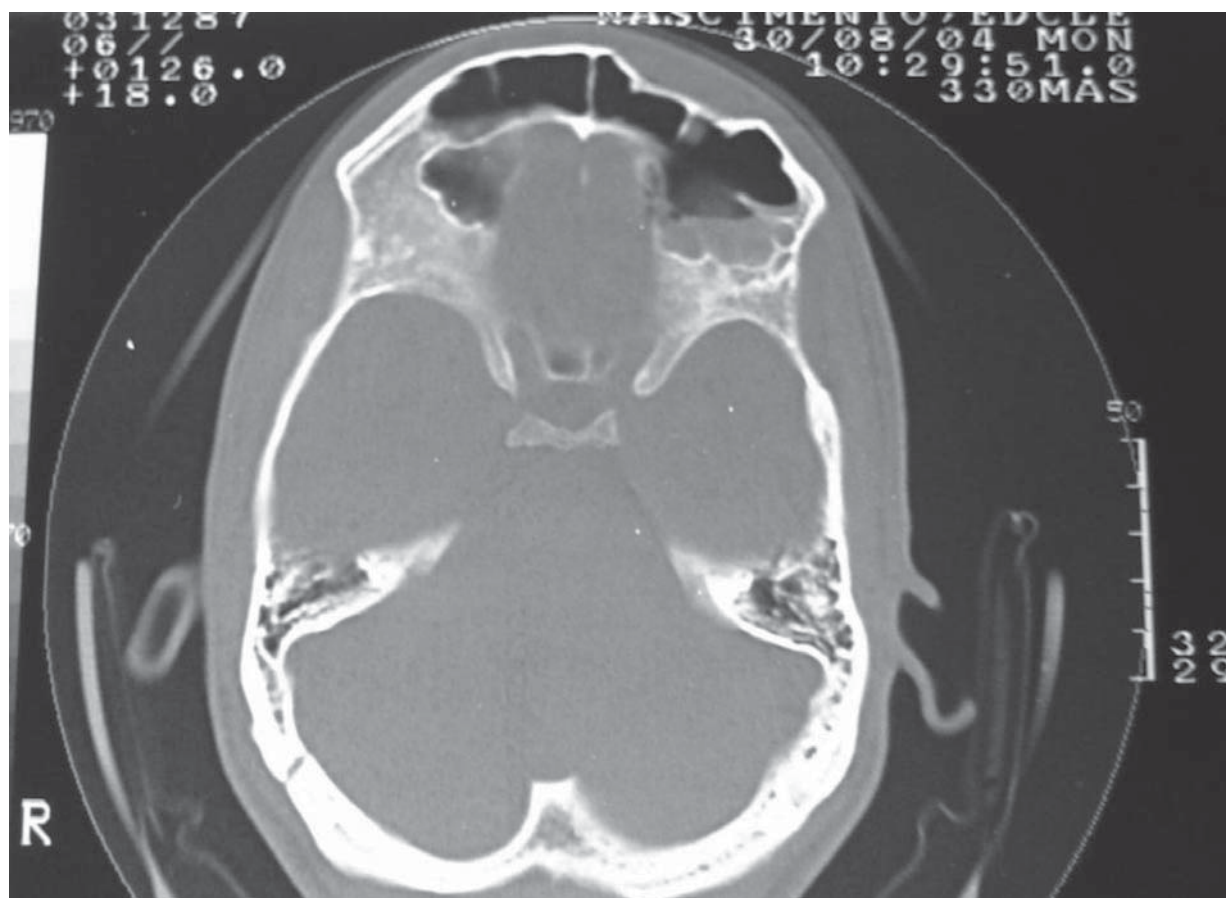


FIGURE 1 - Computed tomography

After resolution of the edema, a frontal depression was observed, leading to the need of surgical exploration due to functional and aesthetic impairment (Figure 2). Since the fracture lines did not compromise the frontal sinus floor and the frontonasal duct, sinus obliteration was not considered, restricting the surgery to the reconstruction of the fractured area. A single superciliary incision over the eyebrow was chosen.

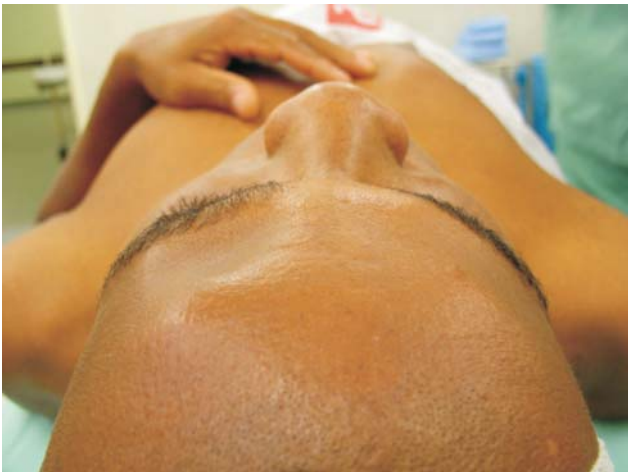

FIGURE 2 - Clinical aspect of the fracture after edema resolution

The incision was accomplished deep to the muscular plane. To obtain elasticity without glabellar skin incision, the cutaneous tissue of this area was released by incision of the muscular and periosteal planes until the median line (Figure 3).

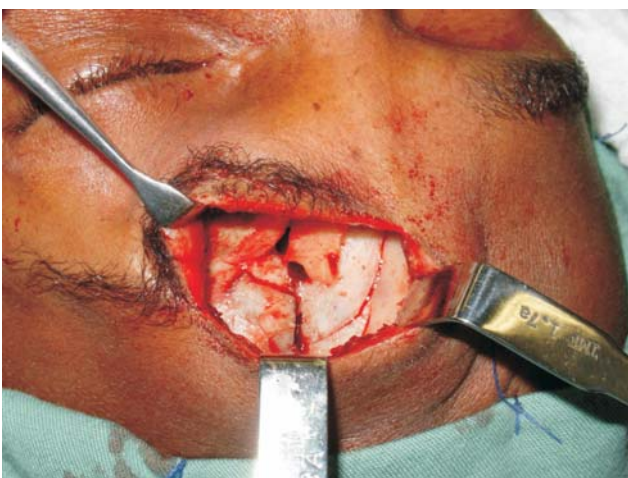

FIGURE 3 - Superciliary surgical approach and fracture exposition

Surgical cleaning of the sinus and inspection of the sinus floor were made. The viable bone fragments were reduced and fixated with miniplates while loss of substance was repaired with a titanium mesh (Figure 4).

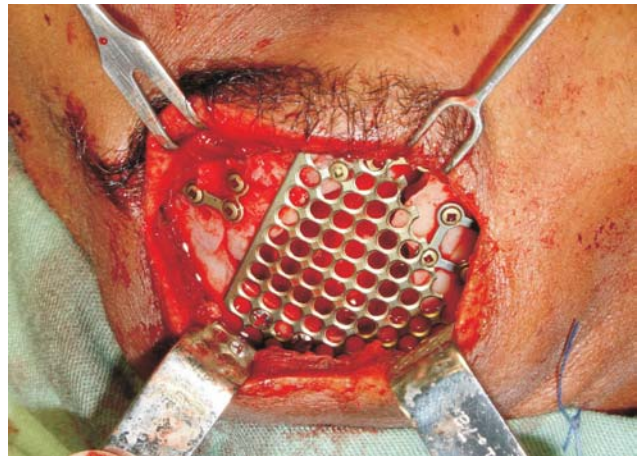


FIGURE 4 - Frontal sinus wall reconstruction

After eight months the patient presents sinus physiology, adequate frontal contour and satisfactory aesthetic results (Figure 5).

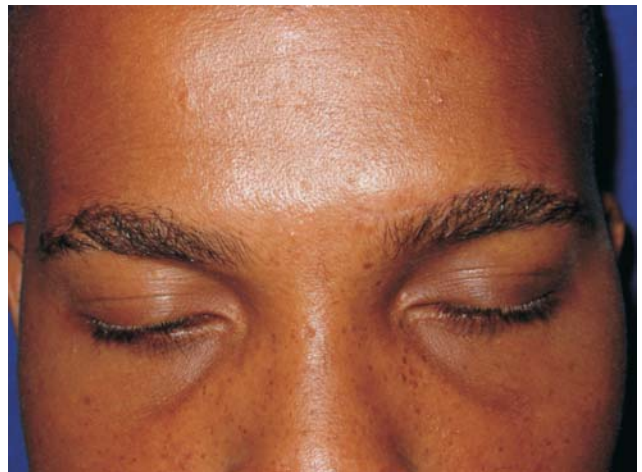

FIGURE 5 - Cicatricial result after surgical incision

## DISCUSSION

Treatment of frontal sinuses fractures vary from conservative to surgical management, depending of the extent and the complexity of the fracture lines. Once surgery indicated, the approach selection is influenced by the extend of the fracture and need of sinus obliteration.

Sinus floor fractures with impairment of the frontonasal duct can lead to the need of sinusal obliteration in order to avoid obstructive complications (1). This conduct tends to the indication of the coronal approach due to a possible aponeurotic galea flap and cranial bone graft for closing the floor and fulfilling the sinus, respectively (2, 3).

When comminuted fractures go beyond the frontal sinus posterior wall, cranialization is generally indicated (1, 4). Such technique aims removal of osseous fragments, communicating the sinus to the anterior cranial fossa. This conduct, however, needs sinusal obliteration to avoid relationship between the dura mater and the inhaled air. Fractures restricted to the anterior wall need greater exposition in the following situations: 1) broad extension; 2) association with naso-orbital-ethmoidal fractures and 3) need of bone graft (3, 4, 5). Even though great fractures can be accessed with the "bat wing" approach, the glabellar incision is cosmetically unfavorable. Naso-orbital-ethmoidal fractures generally need greater surgical exposition, independently of the extent of the frontal sinus anterior wall, making the coronal approach preferable. The coronal approach also facilitates reconstruction of tissue loss using cranial bone grafts, although defects can be also repaired with alloplastic material.

The application of the superciliary approach to the frontal sinus is ideal in exclusive unilateral anterior wall frontal sinus fracture (1). The choice of this approach depends of exclusion of fracture complexity factors, so computed tomography evaluation is essential for planning.

For the frontal region access, superciliary incision must be placed in the superior margin of the eyebrow to avoid damage to the supra-orbital neuro-vascular bundle. For fractures that extend to the glabella, a maneuver that allows integrity of the glabellar skin is release of the cutaneous plane until the median line for incision of the musculature.

## CONCLUSION

In well selected cases, the superciliary approach is an objective and cosmetic option for unilateral anterior wall frontal sinus fractures, representing a good alternative to other conventional approaches.

## REFERENCES

1. Gerbino G, Rocca F, Benech A, Caldarelli C. Analysis of 158 frontal sinus fractures: current surgical management and complications. *J Craniomaxillofac Surg.* 2000;28(3): 133-139.
2. Ribeiro Júnior O, Borba AM, Gouveia MM, Alves CAF, Jorge WA. A utilização do acesso coronal no tratamento de fraturas maxilofaciais: anatomia cirúrgica, técnica e indicações. *Rev Int Cir Traumatol Bucomaxilofac.* 2006;12(4):356-363.
3. Abubaker AO, Sotereanos G, Patterson GT. Use of the coronal surgical incision for reconstruction of severe craniomaxillofacial injuries. *J Oral Maxillofac Surg.* 1990;48(6):579-586.
4. Ioannides C, Freihofer HP, Friens J. Fractures of the frontal sinus: a rationale of treatment. *Brit J Plast Surg.* 1993;46:208-214.
5. Montovani JC, Campos LMP, Gomes MA, Moraes VRS, Ferreira FD, Nogueira EA. Etiologia e incidência das fraturas faciais em adultos e crianças: experiência em 513 casos. *Rev Bras Otorrinolaringol.* 2006;72 (2):235-241.

Received: 03/25/2007  
Recebido: 25/03/2007

Accepted: 04/20/2007  
Aceito: 20/04/2007