



## Alignment and leveling maxillary impacted canines

### *Alinhamento e nivelamento de caninos superiores impactados*

**Renata Lima Lorusso<sup>[a]</sup>, José Henrique Gonzaga de Oliveira<sup>[b]</sup>, Eduardo Franzotti Sant'Anna<sup>[c]</sup>,  
Cristiano Miranda de Araujo<sup>[d]</sup>, Orlando Motohiro Tanaka<sup>[e]</sup>, Odilon Guariza Filho<sup>[f]</sup>,  
Elisa Souza Camargo<sup>[g]</sup>**

<sup>[a]</sup> Specialist in Orthodontics, Pontifical Catholic University of Paraná (PUCPR), Curitiba, PR - Brazil

<sup>[b]</sup> Master in Orthodontics, Federal University of Rio de Janeiro (UFRJ), Rio de Janeiro, RJ - Brazil

<sup>[c]</sup> PhD in Orthodontics, Federal University of Rio de Janeiro (UFRJ), professor of Orthodontics, Federal University of Rio de Janeiro (UFRJ), Rio de Janeiro, RJ - Brazil

<sup>[d]</sup> Master in Orthodontics, Pontifical Catholic University of Paraná (PUCPR), Curitiba, PR - Brazil

<sup>[e]</sup> PhD in Orthodontics, Federal University of Rio de Janeiro (UFRJ), professor of Orthodontics PUCPR, Curitiba, PR - Brazil

<sup>[f]</sup> PhD in Orthodontics, São Paulo State University (Unesp), professor of Orthodontics, Pontifical Catholic University of Paraná (PUCPR), Curitiba, PR - Brazil

<sup>[g]</sup> PhD in Orthodontics, Federal University of Rio de Janeiro (UFRJ), professor of Orthodontics, Pontifical Catholic University of Paraná (PUCPR), Curitiba, PR - Brazil, e-mail: escamargo@uol.com.br

---

#### Abstract

The impaction of maxillary permanent canines is a frequently encountered clinical problem, especially on the palate. The causes for retarded eruption of the teeth may be either generalized or localized, and its diagnosis is based on both specific clinical and radiographic examinations. Combined periodontal-orthodontic treatment has been efficient when a prognostic and adequate technique is assured to preserve the integrity of the tissues around the canine teeth. This review illustrates clinical cases of maxillary impacted canines and procedures to bring them to normal axial inclination on the dental arch.

**Keywords:** Orthodontics. Canine impacted. Impaction.

### Resumo

*A impação de caninos superiores permanentes é um problema clínico frequentemente encontrado, especialmente no palato. As causas para a erupção tardia dos dentes pode ser tanto generalizada ou localizada, e seu diagnóstico é baseado em exames clínicos e radiográficos específicos. O tratamento combinado periodontal-ortodôntico tem sido eficiente quando uma técnica adequada é assegurada para preservar a integridade dos tecidos ao redor dos dentes caninos. Esta revisão ilustra casos clínicos de caninos superiores impactados e procedimentos para trazê-los à inclinação axial normal no arco dentário.*

**Palavras-chave:** Ortodontia. Caninos impactados. Impação.

### Introduction and literature review

The maxillary canine has an essential role in the dental occlusion and it presents a long period of development and a complex path of eruption (1). It is estimated an incidence of 0,92% to 2,2% of impacted canines in children from seven to thirteen years of age, more common on female, on the palatine region and on the left side of the dental arch (2-4).

Although hereditary factors are associated with the presence of impacted canines, most concerns stem from local factors such as prolonged retention or early loss of the deciduous canine (1, 5-8); cystic or neoplastic formation (1, 5, 6); abnormal position of the tooth bud (8); supernumerary teeth (1, 5, 9); ankylosis and dilaceration of the root (4); and space availability on the dental arch (3, 7, 10-11). Maxillary canine impaction has also been associated with the presence of peg shaped small lateral incisors or when lateral incisor is missing. The latest implies the importance of the lateral incisor root as a guide to allow the canine to erupt into normal position (12-14).

Some clinical signs of canine impaction must be observed, such as the delay on canine eruption beyond fifteen years of age; prolonged retention of the deciduous canine; elevation of the labial or palatine mucosa; deviation of midline; presence of space between the incisors and distal inclination of the lateral incisors in relation to the midline (9, 15).

The canines usually erupt in infra-occlusion when there is not enough space on the dental arch. When located palatally, due to the thickness of the palatal cortical bone as well the dense, thick, and resistant palatal mucosa (4), they seldom erupt without surgical exposure. Such diagnosis is carried out through clinical exam and radiographies

(4) such as occlusal, panoramic, teleradiographies and periapical ones (4, 16).

The periodontal-orthodontic treatment is the ultimate approach if adequate surgical technique is associated with light orthodontic forces to minimize deleterious effects on the periodontal tissues (4, 17, 18, 19). This paper is a review illustrated with clinical cases of maxillary impacted canines, besides the singular aspects used for moving the canine to its normal position.

### Discussion

The treatment approach that places the maxillary canine on its right position must always be prioritized once the canine is essential to keep a functional occlusion and maintain the patient's esthetic (5). The treatment protocol will rely on patient's age, dental development, location and space availability on the dental arch to accommodate the tooth (1).

The periodontal procedures to expose the impacted tooth will depend on the labiolingual and mesiodistal positioning of the crown and the quantity of attached gingiva around the canine. The integrity of the periodontal tissues must not be compromised in order to avoid esthetic loss and assure a favorable prognostic to the eruption of the canine. (10, 20, 21) When it is labially positioned, extreme care should be taken not to move the tooth more labially to prevent bone deiscence, gingival migration and recession (19).

In the open technique to expose the impacted canine, the soft tissues and bone that cover the tooth are removed and the tooth is protected with surgical cement. The orthodontic attachment is then bonded to the crown of the tooth when the cement is removed. Such procedure allows observing

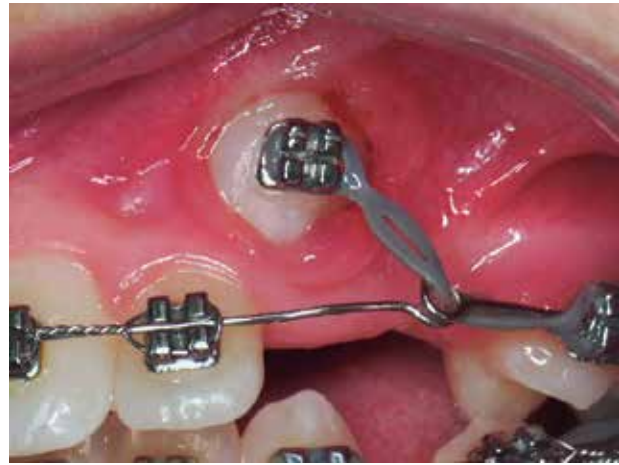the direction of eruption of the tooth and selecting the most favorable force vector during traction. However, the open technique causes several damages to the periodontal tissue such as gingival recession, bone loss, decreased width of keratinized gingiva, delayed periodontal healing and gingival inflammation (21, 22) (Figures 1-3).

In the closed technique, a gingival flap is reflected exposing the crown of the impacted tooth. The bone covering the crown is removed and an orthodontic attachment is placed. The flap is then repositioned over the canine and a chain or wire is extended from the attachment into the oral cavity. This procedure allows the periodontal health to be preserved after positioning the canine on the occlusion line (22) (Figures 4 and 5).

After the surgical exposure, several methods can be used to fix the attachment to the crown of the impacted tooth. However improvements in adhesive systems like hydrophilic adhesive resins and self-curing resin modified glass-ionomer cement made methods like wire ligation (1, 10, 17, 23) (Figure 6), orthodontic bands (9, 23, 24, 25) and perforation (2, 23, 26) (Figure 7) obsolete. Direct bonding technique involves a small area of the tooth, cause no permanent damage, decreases the risk of periodontal loss, ankylosis and external root resorption (27, 28). It is also possible to better control the traction direction by changing attachment position when needed (29). However, under extreme condition in which the canine presents a horizontal position and is very high intraosseous, a perforation of the canine cuspid edge can be carried out to allow tying a ligature wire to realize the traction (2).

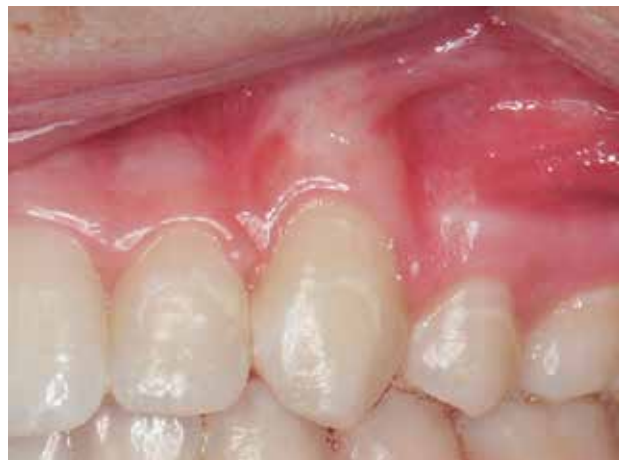Hooks, brackets, bottoms or metal mesh pads bonded to the impacted canine have been used for tractioning. Ligature chains are fixed or soldered on the attachment previously to the bonding to avoid that the soft tissues recover the exposed tooth and another surgical procedure is necessary (30-33) (Figure 8).

There are many forms for aligning the upper impacted canines to its normal axial inclination such as palatine arches provided with handles in the tubes entrance (12), auxiliary arches incorporating loops superposed to the base arch (34, 35), ballista spring system (19, 36), springs soldered to the main archwire (35), superelastic wires (19, 35) and cantilevers (35); removable appliances (33); use of intra or intermaxillar anchorage and the utilization of bone integrated implants and magnets (Figures



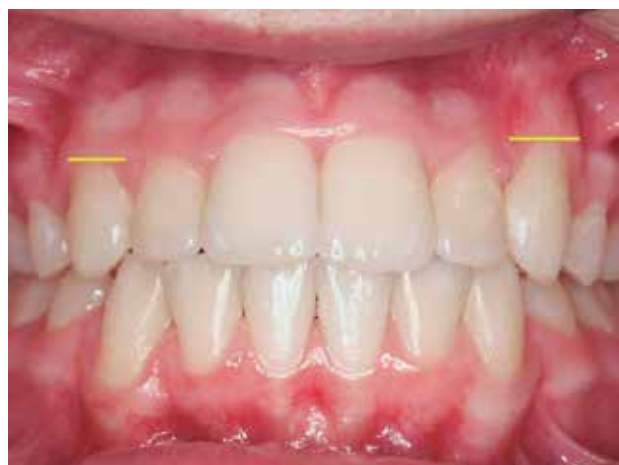**Figure 1** - Open surgical technique

Source: Research data.



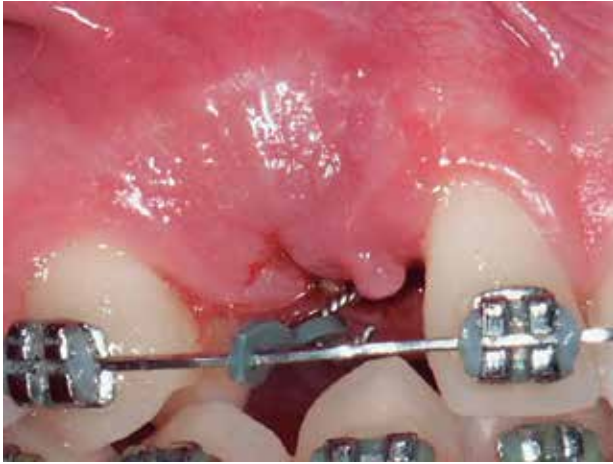**Figure 2**- Periodontal aspect of the open surgical technique in lateral view

Source: Research data.



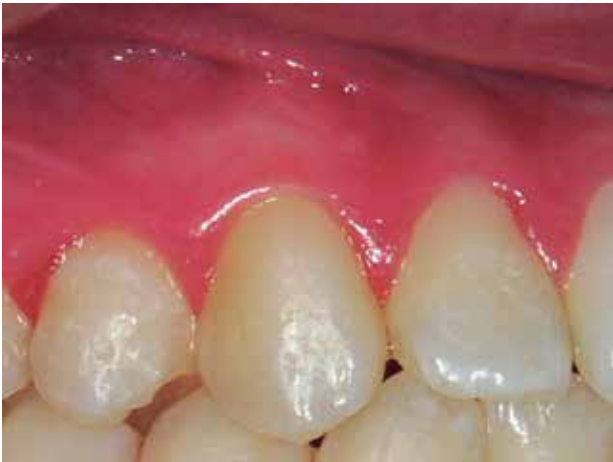**Figure 3** - Periodontal aspect of the open surgical technique in frontal view

Source: Research data.



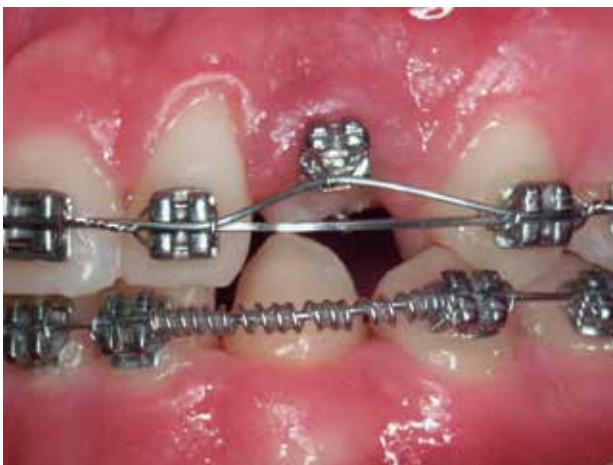**Figure 4** - Closed surgical technique

Source: Research data.



**Figure 5** - Periodontal aspect of the closed surgical technique in lateral view

Source: Research data.



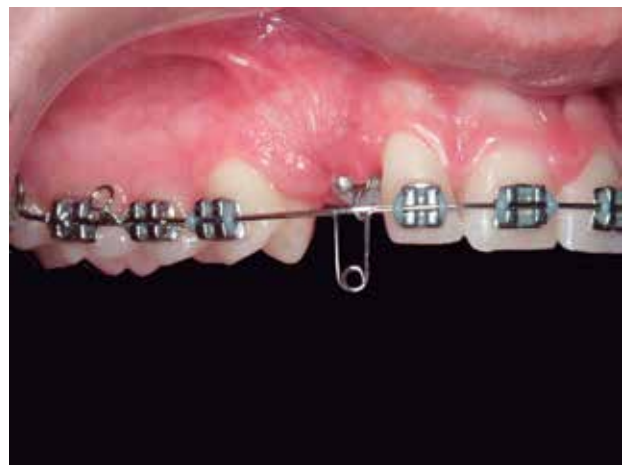**Figure 6** - Obsolete method of wire ligation

Source: Research data.

9-11). The fixed appliance is the most commonly used once it offers greater control during traction. Besides that, in most cases, it is necessary to open space in the dental arch for the impacted canine and correct an established malocclusion (36). During the traction the base arch must be made with a heavy rectangular wire to resist the traction movement and can be associated to any anchorage reinforcement, such as transpalatal bars, Class II elastics and headgears (12, 15, 35-37).

Light and continuous forces are suggested to avoid rupture of the periodontal fibers and/or create areas of hyalinization (22) Forces ranging from twenty (34) to a hundred (29, 32) g/f must be supplied with elastic threads, elastomeric chains, springs, steel ligatures or helicoidals fixed conveniently to the orthodontic arch (4, 19). The traction force initially must improve the axial inclination of the palatally positioned canine in order not to damage the proximal teeth roots. Only after verticalization, the canine must be moved labially to align it on the arch and permit the correction of root torque (4, 10, 14) (Figures 12-14).

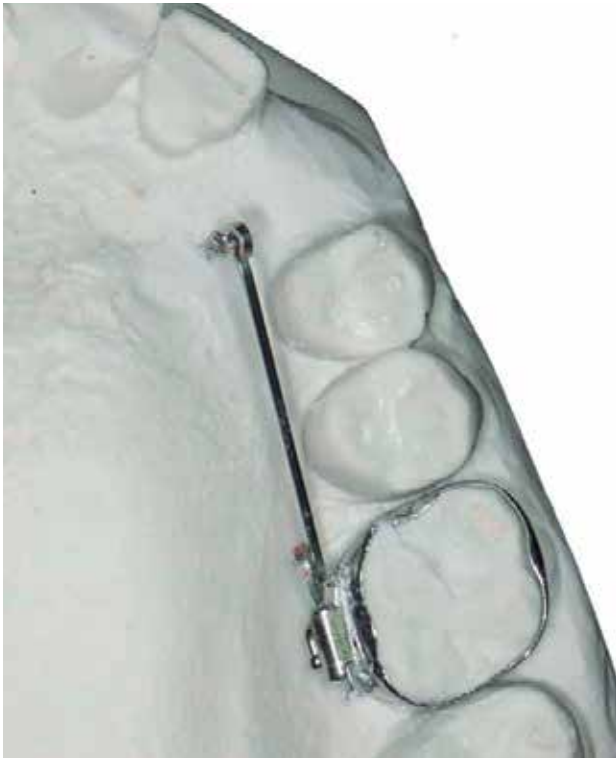
Although the periodontal-orthodontic approach is the most frequent treatment not all maxillary canine teeth are good for traction. In cases where the tooth presents a severe horizontal position; ankylosis; external root resorption; root dilaceration, or even when the patient does not want to undergo orthodontic treatment, extraction of the impacted canine must be considered (4, 16, 38).



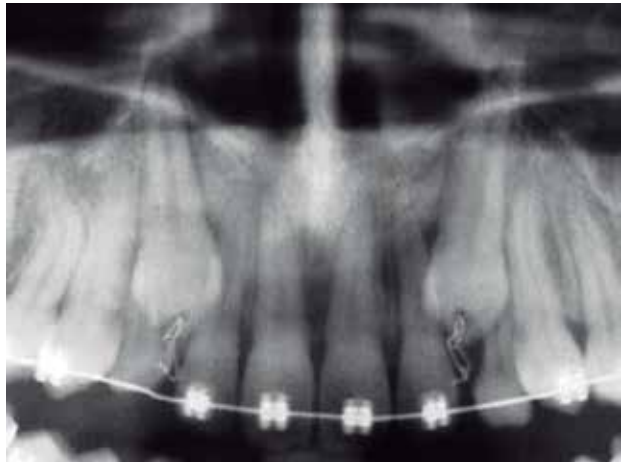**Figure 7** - Crown perforation

Source: Research data.





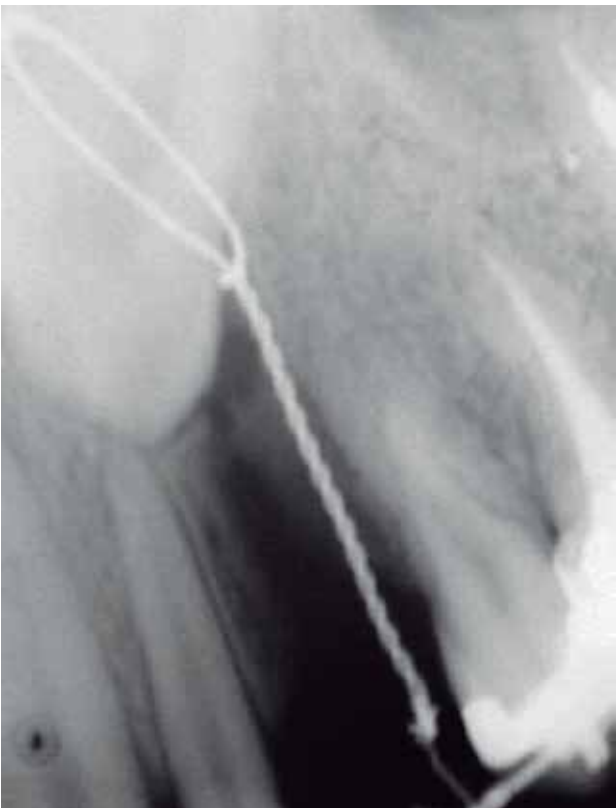**Figure 8** - Example of palatally positioned impacted canine  
Source: Research data.



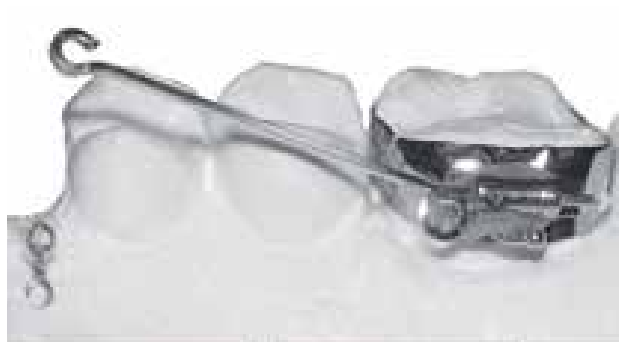**Figure 10** - Radiographic image of the use of cantilever  
Source: Research data.



**Figure 11** - Examples of attachments  
Source: Research data.



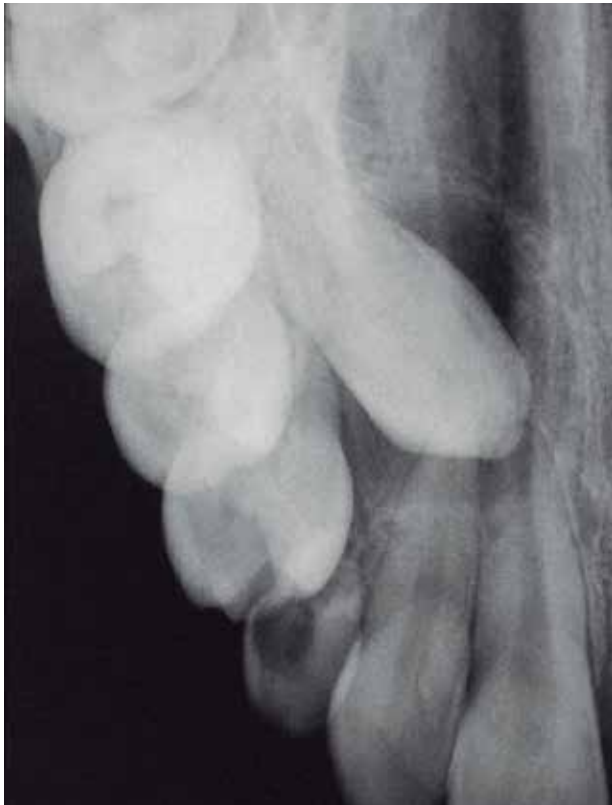**Figure 9** - Occlusal view of cantilever  
Source: Research data.



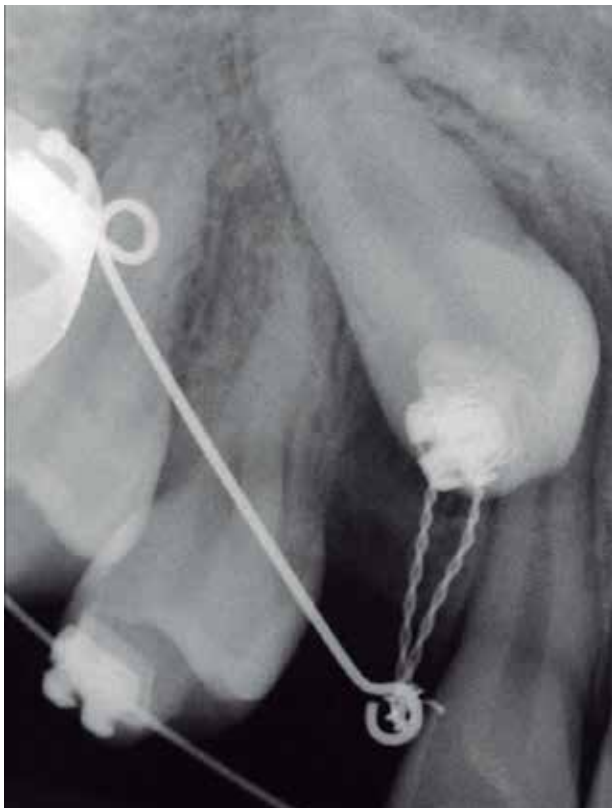
**Figure 12** - Palatal view of the cantilever  
Source: Research data.

**Conclusions**

The combined periodontal-orthodontic treatment is the best option for tractioning palatally or



**Figure 13** - Superposed archwire of Kornhauser  
Source: Research data.



**Figure 14** - Palatal view of the cantilever  
Source: Research data.

labially ectopic canine. The surgical exposure of the dental crown must preserve the integrity of the periodontal tissues making the closed eruption technique the procedure of choice. The fixed appliance provides better force control, avoiding damages to the adjacent teeth. The traction force must be light and continuous, to maintain periodontal health.

## References

1. Moss JP. An orthodontic approach to surgical problems. *Am J Orthod.* 1975; 68(4):363-91.
2. Fournier A, Turcotte JY, Bernard C. Orthodontic considerations in the treatment of maxillary impacted canines. *Am J Orthod.* 1982; 81(3):236-38.
3. Jacoby H. The etiology of maxillary canine impactions. *Am J Orthod* 1983;84(2):125-32.
4. Bishara SE. Impacted maxillary canines: a review. *Am J Orthod Dentofacial Orthop.* 1992;101(2):159-71.
5. Lewis PD. Preorthodontic surgery in the treatment of impacted canines. *Am J Orthod* 1971;60(4):382-97.
6. Bishara SE, Kommer DD, McNeil MH, Montagano LN, Oesterle LJ, Youngquist HW. Management of impacted canines. *Am J Orthod* 1976;69(4):371-87.
7. Moyers RE. *Handbook of Orthodontics.* 4th ed. London: Year Book Medical Publishers; 1988. p. 328-32.
8. Proffit WR, Fields HW. *Contemporary Orthodontics.* 3rd. ed. St Louis: Mosby; 2000. p. 371-73.
9. Fastlicht S. Treatment of impacted canines. *Am J Orthod.* 1954;40:891-905.
10. McBride LJ. Traction – A surgical/orthodontic procedure. *Am J Orthod.* 1979;76(3):287-99.
11. Von der Heydt K. The surgical uncovering and orthodontic positioning of unerupted maxillary canines. *Am J Orthod.* 1975;68(3):257-77.
12. Becker A, Zilberman Y. The palatally impacted canine: a new approach to treatment. *Am J Orthod.* 1978;74(4):422-29.
13. Leivesley WD. Minimizing the problem of impacted and ectopic canines. *ASDC J Dent Child.* 1984;51(5):367-70.

14. Ferguson JW. Management of the unerupted maxillary canine. *Br Dent J* 1990;169(1):11-17.
15. Shoff B. Canine impaction: diagnosis, treatment planning, and clinical management. In: Nanda R. *Biomechanics in clinical orthodontics*. Philadelphia: W. B. Saunders Company; 1996. p. 99-108.
16. Martins DR, Kawakami RY, Henriques JFC, Janson GRP. Impacted teeth: clinical procedures – relate of cases. *Rev Dent Press Ortodon Ortop Facial*. 1998;3:12-22.
17. Ziegler TF. A modified technique for ligating impacted canines. *Am J Orthod*. 1977;72(6):665-70.
18. McDonald F, Yap WL. The surgical exposure and application of direct traction of unerupted teeth. *Am J Orthod*. 1986;89(4):331-40.
19. Kokich VG. Surgical and orthodontic management of impacted maxillary canines. *Am J Orthod Dentofac Orthop* 2004;126(3):278-83.
20. Vanarsdall RL, Corn H. Soft-tissue management of labially positioned unerupted teeth. *Am J Orthod Dentofac Orthop*. 2004;125(3):284-93.
21. Boyd RL. Clinical assessment of injuries in orthodontic movement of impacted teeth. II. Surgical recommendations. *Am J Orthod*. 1984;86(5):407-18.
22. Frank CA, Long M. Periodontal concerns associated with the orthodontic treatment of impacted teeth. *Am J Orthod Dentofac Orthop*. 2002;121(6):639-49.
23. Monti A E. *Tratado de Ortodoncia*. Buenos Aires: El Ateneo, 1958:431-42.
24. Johnston WD. Treatment of palatally impacted canine teeth. *Am J Orthod*. 1969;56(6):589-696.
25. Andreasen GF. A review of the approaches to treatment of impacted maxillary cuspids. *Oral Surg Oral Med Oral Pathol*. 1971;31(4):479-84.
26. Johnson CN. *La Practica Odontologica*. Barcelona: Labor; 1930. p. 992-97.
27. Nielsen IL, Prydso U, Winkler T. Direct bonding on impacted teeth. *Am J Orthod*. 1975;68(6):666-70.
28. Boyd RL. Clinical assessment of injuries in orthodontic movement of impacted teeth. I. Methods of attachment. *Am J Orthod*. 1982(6);82:478-86.
29. Odegaard J. The treatment of a Class I malocclusion with two horizontally impacted maxillary canines. *Am J Orthod Dentofacial Orthop*. 1997;111(4):357-65.
30. Doleac P, Manga RK. Multiple eyelet chain for impacted teeth. *J Clin Orthod* 1991;25(5):322.
31. Goh G, Kaan SK. Reducing failures of gold chain attachment to impacted teeth. *J Clin Orthod*. 1993;27(3):161-62.
32. Crescini A, Clauser C, Giorgetti R, Cortellini P, Pini Prato GP. Tunnel traction of intraosseous impacted maxillary canines. A three-year periodontal follow-up. *Am J Orthod Dentofacial Orthop*. 1994;105(1):61-72.
33. Orton HS, Garvey MT, Pearson MH. Extrusion of the ectopic maxillary canine using a lower removable appliance. *Am J Orthod Dentofacial Orthop*. 1995;107(4):349-59.
34. Kornhauser S, Abed Y, Hahari D, Becker A. The resolution of palatally impacted canines using palatal-occlusal force from a buccal auxiliary. *Am J Orthod Dentofacial Orthop*. 1996;110(5):528-34.
35. Jacoby H. The “ballista spring” system for impacted teeth. *Am J Orthod*. 1979;75(2):143-51.
36. Almeida RR, Fuziy A, Almeida MR, Almeida-Pedrin RR, Henriques JFC, Insabralde CMB. Management of impactions and/or ectopical eruption of the permanent cuspids: general considerations, diagnosis and therapeutic. *Rev Dent Press Ortodon Ortop Facial*. 2001;6:93-116.
37. Shapira Y, Kuftinec MM. Orthodontic management of the palatally impacted tooth. *J Clin Orthod* 1981;15:810-3.
38. Stuani B, Tavares CA, Bolognese AM. The impacted canines traction. *Rev SBO*. 1995;2:263-71.

Received: 07/19/2012

Recebido: 19/07/2012

Accepted: 08/24/2012

Aceito: 24/08/2012