
A SURGICAL PROCEDURE USING SHEEP AS AN ANIMAL MODEL TO EVALUATE OSSEOINTEGRATION

Um procedimento cirúrgico utilizando a ovelha como modelo animal para avaliar ossointegração

**Alexandre Cunha¹, Renata Pedrolli Renz², Gleisse Wantowski,³
Rogério Belle de Oliveira⁴, Eduardo Blando⁵, Roberto Hübler⁶**

¹ M.Sc., Pontifical Catholic University of Rio Grande do Sul (PUCRS), Rio Grande do Sul, RS - Brazil.

² M.Sc., Pontifical Catholic University of Rio Grande do Sul (PUCRS), Rio Grande do Sul, RS - Brazil.

³ M.Sc., Pontifical Catholic University of Rio Grande do Sul (PUCRS), Rio Grande do Sul, RS - Brazil.

⁴ Ph.D., Professor, Pontifical Catholic University of Rio Grande do Sul (PUCRS), Rio Grande do Sul, RS - Brazil.

⁵ Ph.D., Pontifical Catholic University of Rio Grande do Sul (PUCRS), Rio Grande do Sul, RS - Brazil.

⁶ Ph.D., Professor, Pontifical Catholic University of Rio Grande do Sul (PUCRS), Rio Grande do Sul, RS - Brazil, e-mail: hubler@pucrs.br

Abstract

The aim of this paper is to describe a technical sequence of procedures, including anesthesia and surgery steps to adopt as standard surgical procedures using an animal model to evaluate the osseointegration phenomenon and perform the histological analysis after animal deaths at different healing times. In a macroscopic analysis the novel coin-shaped design of titanium implants intended to improve the contact area between the implants surfaces and the cortical bone when compared with titanium screws implants usually applied in the Dentistry area. This non human experimental model presents a probable applicability in Implantology area.

Keywords: Titanium; Implants; Experimental surgery; Veterinary surgery.

Resumo

O objetivo deste artigo é descrever uma seqüência técnica de procedimentos, incluindo anestesia e passos cirúrgicos para sistematizar procedimentos cirúrgicos para avaliar os fenômenos de ossointegração e realizar análise histológica após morte dos animais em diferentes tempos de cicatrização. Numa análise macroscópica, estuda-se um novo desenho em forma de moeda de implantes de titânio, com o objetivo de melhorar a área de contato entre as superfícies implantares e o osso cortical, comparando-se com parafusos de titânio usualmente utilizados em Odontologia. Este estudo experimental não-humano apresenta com provável aplicabilidade na área de Implantologia.

Palavras-chave: Titânio; Implantes; Cirurgia experimental; Cirurgia veterinária.

INTRODUCTION

Titanium implants are widely applied in Dentistry and Orthopedic areas. Recent studies in these areas have focused on the development of new methods to evaluate the interaction between implant surfaces and bone (1). Several phenomena have been investigated, such as osseointegration, cell adhesion, osteoinduction and osteoconduction, all of which have broad applications in *in vitro* and *in vivo* studies. On the other hand, there is a search for the better implant surface and geometry to increase bone adhesion and growth. This study describes surgical procedures using sheep as an animal model to evaluate the osseointegration of a titanium implant that has a novel design.

METHODS

Implant preparation

Coin-shaped titanium (ASTM grade 4) implants, 4 mm thick and 6 mm in diameter, were produced by a Brazilian dental implant manufacturer. A 3 mm screw was adapted to a through hole made in the center of all implants to ensure contact and fixation of the implants to the cortical bone. The new design coin-shaped of implants was developed in order to increase the contact area between the implant surface and the cortical bone and avoiding the shear forces that act on titanium screws routinely used in dental implants (2, 3). The coin-shaped titanium implants are shown in Figure 1.



FIGURE 1 - Coin-shaped titanium implants (4 mm in thickness and 6 mm in diameter) with a 3 mm screw in the through hole located in the center area of the implant for cortical bone fixation

Animal model

This study was approved by the Ethics Committee of the Pontifical Catholic University of Rio Grande do Sul (PUCRS) under number 06/03548. Clinically healthy adult female sheep were used as the animal model because their cortical bone is thicker than that of rats and rabbits, animals also used in *in vivo* studies (4, 5, 6).

Surgery

The tibiae and radii of the animals were used for the implantation of samples.

Anesthesia

Pre-anesthesia consisted of the IM administration of 0.1 mg/kg acepromazine maleate (1% Acepran) and 2 mg/kg meperidine (Dolosal). After 15 minutes, 20 mg/kg cephalothin sodium was injected IV. Anesthesia was induced with an IV injection of propofol (2 - 4 mg/kg), and maintained with isoflurane in 100% oxygen. During surgical procedures, Ringer's solution with sodium lactate (15 ml/kg/h) was administered. The animals vital functions were monitored during the entire anesthetic procedure using a pulse oximeter and electrocardiography.

Incision, sample implantation, postoperative procedures, suture and euthanasia

The operation sites were shaved and cleaned with 2% iodine and isopropyl alcohol before the incisions. The incisions were made along the longitudinal bone axis on all limbs. After incision, all soft tissues were dissected and the cortical bone was exposed. The cortical bone was polished to increase the contact area between the bone and the titanium porous coating. The samples were placed in contact with cortical bone at a distance of 13 mm between each titanium coin-shaped implant. An aluminum template was used to determine the sites of the samples on the cortical bone. The titanium implants were fixed to cortical bone using a screw adapted to the central through hole of the samples. All bone perforations and drillings were performed under constant irrigation with saline

solution to avoid heating damage to the cortical bone. After the implantation of all samples, the soft tissues and the periosteum were replaced, and the operating area was closed with 2.0 nylon suture. After all surgical procedures, the animals were kept in their cages under controlled lighting and temperature. A nonsteroidal anti-inflammatory drug (1 mg/kg ketoprofen) was administered for postoperative analgesia every

24 hours for 5 days, and an opioid drug (2mg/kg Tramadol), every 8 hours for 48 hours. Dressings covering the operation sites were changed daily, and the suture was removed at ten days postoperatively. The health conditions of the animals were monitored until euthanasia. The animals were killed after 30 and 60 day healing times with an injection of sodium thiopental. The mainly steps of the surgery are shown in Figure 2.

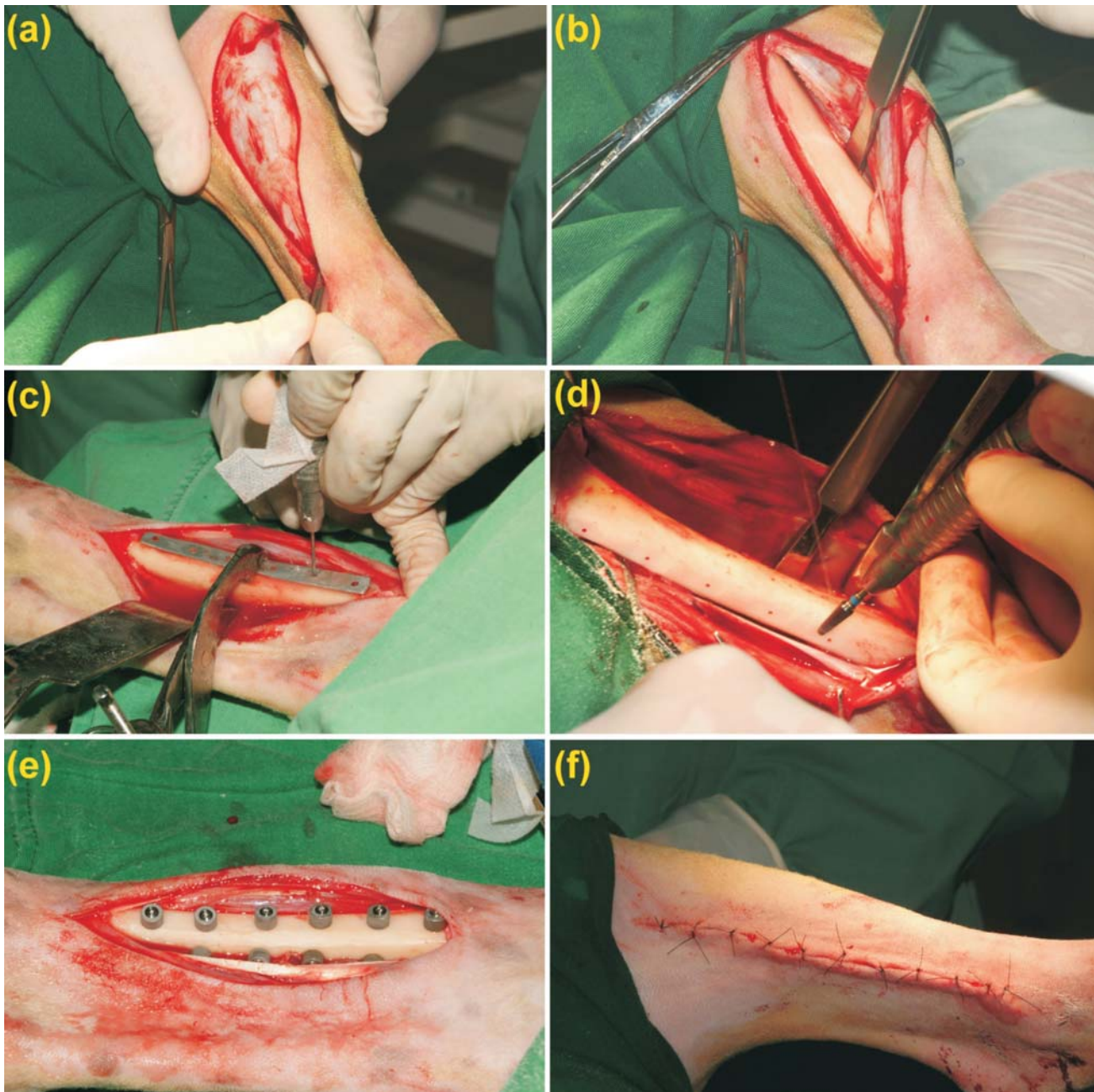


FIGURE 2 - Mainly steps of surgical procedure: (a) incision area (b) dissection of soft tissues and exposition of cortical bone (c) aluminum template sited at cortical bone and perforation of the implants sites (d) polishing of cortical bone surface (e) samples implanted and fixed with screws (f) suture of the operating area

COMMENTS

The novel coin-shaped design of titanium implants intended to obtain a better contact area between the implants surfaces and the cortical bone when compared with the titanium screws implants usually applied in Dentistry. The sequence of these surgical procedures and the use of sheep as animal model are viable methods to evaluate the phenomena that occur at implant surface-bone tissue interface mainly the osseointegration process. This non human experimental model presents a probably applicability in Implantology area.

REFERENCES

1. Liu X, Chu PK, Ding C. Surface modification of titanium, titanium alloys, and related materials for biomedical applications. *Materials Science & Engineering*. 2005;47:49-121.
2. Ronold HJ, Ellingsen JE. The use of a coin shaped implant for direct in situ measurement of attachment strength for osseointegrating biomaterial surfaces. *Biomaterials*. 2001;23:2201-2209.
3. Ronold HJ, Ellingsen JE. Effect of micro-roughness produced by TiO₂ blasting-tensile testing of bone attachment by using coin-shaped implants. *Biomaterials*. 2002; 23:4211-4219.
4. Cunha A. Evaluation of bone ingrowths on titanium implants covered by plasma spraying with different metal-film interfaces. Porto Alegre: Pontifical Catholic University of Rio Grande do Sul; 2008.
5. Renz RP. Osseointegration evaluation of titanium implants with different surface treatments. Porto Alegre: Pontifical Catholic University of Rio Grande do Sul; 2007.
6. Cardoso ES, Cançado RP, Heitz C, Oliveira MG. Descriptive exploratory research related to the use of new zealand white rabbits (*Orytolagus Cuniculus*) as standard animal in evaluation of craniofacial growth patterns. *Revista Odonto Ciência-Fac Odonto/PUCRS*. 2007;22:66-71.

Received: 03/25/2007

Recebido: 25/03/2007

Accepted: 04/24/2007

Aceito: 24/04/2007