



Task dependent muscular volume in unilateral edentulous patients by magnetic resonance imaging (MRI)

Volume muscular função-dependente em pacientes desdentados unilaterais por ressonância magnética (RM)

Shereen M. Shokry^[a], Zeinab Abdel Salam^[b], Abdel Wahab S. Ahmed^[c], Ehab Ismail Ali^[d]

^[a] Lecturer, Oral Radiology, Faculty of Oral & Dental Medicine, Cairo University, Cairo - Egypt, e-mail: shereenmohamedmostafa@yahoo.com

^[b] Professor Oral & Maxillofacial Radiology, Faculty of Dentistry, King Abdulaziz University, Saudi Arabia, e-mail: dr.z.abdelsalam@hotmail.com

^[c] Professor, Oral Radiology, Faculty of Dental Medicine, Cairo University, Cairo - Egypt, e-mail: abdelwahabahmed@gmail.com

^[d] Professor, Diagnostic Radiology, Faculty of Medicine, Cairo University, Cairo - Egypt, e-mail: Ihabismailbakr@yahoo.com

Abstract

Objective: To assess the sequelae of unilateral chewing on muscles of mastication via comparing the approximate muscular volume (AMV) of the masseter (MM), medial pterygoid (MPM), temporalis (TM), superior and inferior lateral pterygoid muscles (SLPM/ILPM) bilaterally using MRI. **Materials and methods:** Twenty patients (16 females and 4 males) were selected from outpatient dental clinics of Kaser Al Aini Hospitals, Cairo University, complaining from being unilaterally edentulous for one year or more. Also six fully dentate individuals (2 males and 4 females) were selected as control group. Magnetic Resonance Imaging (MRI) of the masticatory muscles was performed followed by measuring the approximate muscle volume (AMV) for each muscle bilaterally using the planimetry method. **Results:** Showed increase in the approximate muscular volume (AMV) of the dentate side in both right side and left side edentulous patients. **Conclusion:** Our study shows the effect of long term unilateral chewing on decreasing the AMV in the non-functioning side, suggesting that measuring the approximate masticatory muscle volume using MRI could be helpful in detection of long-term functional disability of each muscle in comparison to adjacent muscles.

Keywords: Masticatory Muscular Volume. Magnetic Resonance Imaging. Unilateral edentulism. Planimetry measurements.

Resumo

Objetivo: Avaliar as sequelas da mastigação unilateral sobre os músculos da mastigação por meio da comparação do volume aproximado muscular (AMV) do músculo masseter (MM), pterigóideo medial (MPM), temporal (TM), músculos pterigóideos laterais superior e inferior (SLPM/ILPM) bilateralmente usando ressonância magnética. **Materiais e métodos:** Vinte pacientes (16 mulheres e 4 homens) foram selecionados a partir de ambulatórios odontológicos do Hospital Kaser Al Aini, Universidade do Cairo; todos os participantes eram unilateralmente desdentados há um ano ou mais. Também, seis indivíduos totalmente dentados (2 homens e 4 mulheres) foram selecionados como grupo controle. Imagem por Ressonância Magnética (RM) dos músculos mastigatórios foi realizada seguido pela medição do volume muscular aproximada (AMV) para cada músculo bilateral utilizando o método de planimetria. **Resultados:** Foi observado aumento no volume aproximado muscular (AMV) do lado dentado em ambos os lados direito e esquerdo de desdentados laterais. **Conclusão:** Este estudo mostra o efeito em longo prazo da mastigação unilateral na diminuição da AMV no lado não funcional, o que sugere que a medição do volume muscular mastigatório aproximado usando ressonância magnética pode ser útil na detecção de deficiência funcional de cada músculo em comparação com músculos adjacentes em longo prazo.

Palavras-chave: Volume mastigatório muscular. Ressonância magnética. Desdentado unilateral. Medidas planimétricas.

Introduction

Although mastication can occur bilaterally, 78% of observed subjects have a preferred side, while in unilateral partial edentulous subjects; they mainly use the dentate side, this is normally the side with the greatest number of teeth contact during lateral glide and this is where the majority of chewing occur (1) thus, continual unilateral mastication may alter the coordination of masticatory muscles (2).

Recently, muscle thickness has been considered as an indicator of jaw muscle function, since tooth loss may cause decreased workload on masticatory muscles and it may affect muscle thickness (1). Occlusal discrepancy can be a predisposing factor to Temporomandibular disorders (TMD), especially when it is asymmetrically expressed. Moreover, significant correlations were seen between signs and symptoms of TMD and occlusal variables describing asymmetry (3).

Magnetic resonance imaging (MRI) is a noninvasive procedure that has the potential to produce high quality tomographic images in any plane with excellent soft tissue resolution and without exposing the patient to ionizing radiation or any known biologic hazards (4).

The purpose of this study is to evaluate the effect of unilateral chewing on the approximate volume of muscles of mastication bilaterally by MRI.

Materials and methods

Twenty patients (16 females and 4 males) their ages range from (25-50) years with a mean age of 37.5 years were selected from out patients dental clinic, Faculty of Oral and Dental Medicine, Cairo University. Also, six fully dentate individuals (2 males and 4 females) whose ages ranged from 25-50 years were selected as control group.

Patients were complaining from the presence of unilaterally edentulous area for one year or more, so they were utilizing only one side of the jaw in mastication and looking forward for prosthetic restoration. All patients were informed about the purpose of this study, and informed consents were obtained from of them. The study was approved by the Ethical Committee of Faculty of Dentistry, Cairo University.

MRI scan was performed by 1.5 T MRI scanner (Philips Medical System, Intera, Germany) equipped with a head surface coil. The imaging protocol consisted of:

- a) Masticatory muscles imaging by utilizing T₂-weighted coronal images where the following parameters were used: time of repetition (TR) = 3655 milliseconds (ms); field of view (FOV) = 200; matrix size = 256 mm × 256 mm; time of echo (TE) = 100 ms; slice thickness = 4.0 mm; intergap distance = 2 mm; and number of excitations (Nex) = 2.

- b) T_1 -weighted axial images, for assessment of MM and MPM, using the following parameters: TR = 580ms; FOV = 230; matrix size = 256 mm × 256 mm; TE = 15 ms; slice thickness = 4 mm; intergap distance = 3; and Nex = 2.
- c) T_1 -weighted parasagittal images were made for assessment of the both SLPM and ILPM. TR = 500ms; TE = 15 ms; slice thickness = 3 mm; intergap distance = 1 mm. Images are transferred from the control unit to the associated work station where data are installed on a compact disc for each patient.

The volume of each muscle was measured by means of the planimetry method using Digital Imaging & Communication of Medicine (DICOM WORKS) program 2000-2001 (Philippe Puech - Loic Bousset, England).

As previously described by (5, 6, 7), using a handheld mouse, each muscle was traced around the area of interest within a slice, then the software calculates the number of pixels enclosed within the traced area, the process is repeated for each slice. Since the pixel dimensions and slice thickness are known. The total AMV can be estimated by:

The total approx. muscular volume = The sum of the area's (cm²) × Slice thickness (mm).

The total of the above areas multiplied by the section thickness provided the approx. total muscular volume. For the planimetry measurements, pictures were taken from the MRIs containing a millimetric scale for calibration. Each measurement was done using software tools to the nearest millimeter at least three times, and the average was considered for calculations (Figure 1).

Statistical Analysis

Data were presented as mean and standard deviation (SD) values. Due to the non-parametric distribution of muscle volume data, Kruskal-Wallis test was used for comparison between the three groups. This test is the non-parametric alternative to one-way ANOVA. Mann-Whitney U test was used for

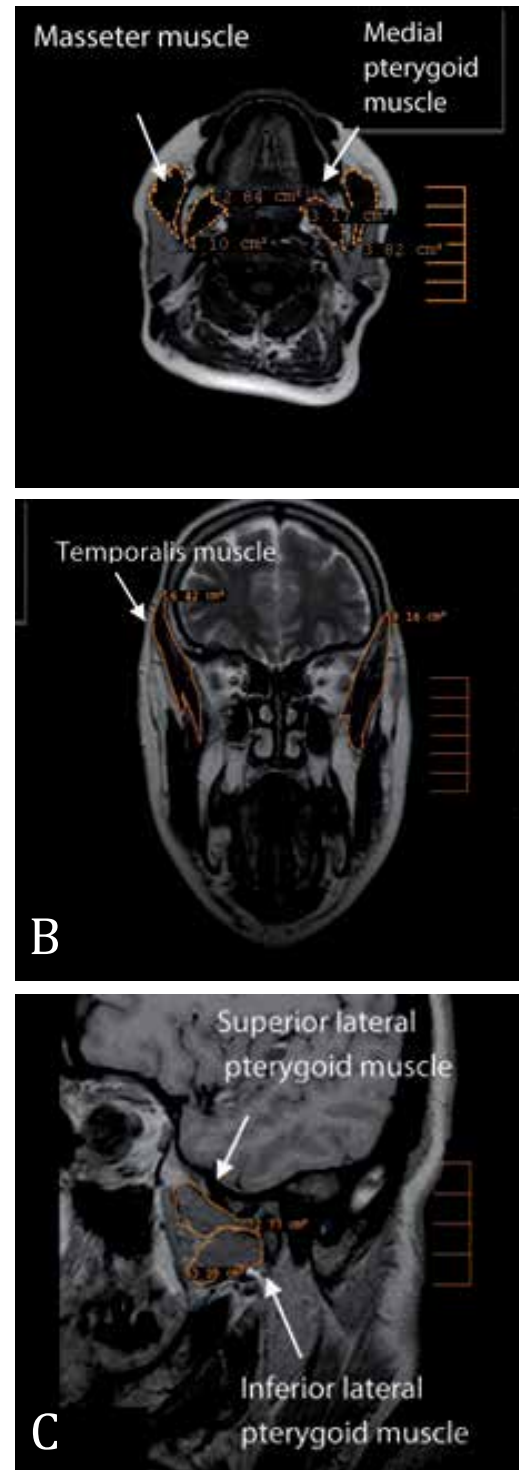


Figure 1 - (A) Tracing of the masseter muscle and the medial pterygoid muscles bilaterally on the axial section. (B) Tracing of the temporalis muscle bilaterally on the coronal section. (C) Tracing of the superior pterygoid muscle and the inferior pterygoid muscle bilaterally on the sagittal section

Source: Research data.

pair-wise comparison between the groups when Kruskal-Wallis test is significant.

Measurement of error

The measurement errors for all measurements were assessed using Dahlberg's method. Dahlberg's formula:

$$\sqrt{\sum d^2 / 2n}$$

Where d is the difference between the measurements and n is the number of duplicates.

Intra-observer reliability (agreement) was measured using Cronbach's alpha reliability coefficient. Cronbach's alpha reliability coefficient normally ranges between 0 and 1. The closer Cronbach's alpha coefficient is to 1.0, the higher the reliability.

The significance level was set at $p \leq 0.05$. Also, intra-observer reliability (agreement) was measured using Cronbach's alpha reliability coefficient.

Statistical analysis was performed with PASW Statistics 18.0 (SPSS, An IBM Company, Chicago, IL, USA – Predictive Analytics Software) for Windows.

Results

As regards right and left temporalis muscles, the mean and standard deviation values are shown in Table 1.

Kruskal-Wallis test for right temporalis muscle showed a statistically significant difference between the groups (p -value = 0.002), while for left temporalis muscle showed a statistically significant difference between the groups (p -value = 0.004).

Pair-wise comparisons between the groups revealed that control group showed the statistically significantly highest mean muscle volume. There was no

Table 1 - The mean, standard deviation (SD) values and results of Kruskal-Wallis test for comparison between muscle volume in the three groups

Side	Muscle	Group						p-value
		Edentulous (Right side)		Edentulous (Left side)		Control		
		Mean	SD	Mean	SD	Mean	SD	
Right	Temporalis	111.3b	34.9	117.1b	30	231.3	70.6	0.002*
	Masseter	98.4	44.2	103.1	29	102	23.6	0.513
	Medial pterygoid	39.1	23.3	34.1	12.9	33.5	14.8	0.932
	Superior lateral pterygoid	20.8	13	17.4	9	23.3	8.9	0.537
	Inferior lateral pterygoid	34.7	13.8	40.6	11.8	45.4	15.4	0.249
Left	Temporalis	121.4b	49.5	114.2b	37.8	236.8	86	0.004*
	Masseter	99.5	41.5	94.7	24.4	103.2	28	0.764
	Medial pterygoid	52.1	42.7	33.7	15.5	36.3	16.8	0.941
	Superior lateral pterygoid	20.9	8.1	16.6	9.8	22.6	9.5	0.448
	Inferior lateral pterygoid	41.6	15.8	45.4	9.6	43.5	9.3	0.503

Legend: * = significant at $p \leq 0.05$.

Source: Research data.

Note: different letters are statistically significantly different.

statistically significant difference between right and left side edentulous subjects; both showed the statistically significantly lowest mean muscle volume.

As regards right and left masseter muscles, medial pterygoid muscles, superior and inferior lateral pterygoid muscles the mean and standard deviation values of muscles volume are shown in Table 1.

Kruskal-Wallis test showed non-statistically significant difference between the groups.

Measurement error and intra-observer reliability

There was a statistically significant intra-observer agreement regarding all measurements in all groups. The measurement error ranged from 0.3 to 1.1 (Table 2).

Discussion

The stomatognathic apparatus develops in an almost symmetric pattern, with two paired bones (the maxillae) and a single symmetric bone (the mandible) bearing two symmetric joints, several pairs of muscles, and two symmetric rows of teeth (2). Unilateral mastication is one of the conditions that affect the stomatognathic balance, by producing strain in a single muscle unlike bilateral mastication

and thus altering the coordination between masticatory muscles (8).

There is a lot of evidence that the masticatory system has the ability to the wide range of adaptive modalities. These adaptations can be functional and/or structural and may respond to transient and/or permanent demands. Therefore, this system, like any biological system, cannot be viewed as a rigid and immutable (9).

Several compensatory adaptations to the altered anatomical situations may be found, and assessment of the patient should be aimed mostly at the functional impairment, providing useful data on the impact of this dysfunction on the masticatory system (10).

Difference in the AMV of the five main muscles of mastication between dentate and unilaterally edentulous patients using MRI has been thoroughly studied. Regarding the temporalis muscle, it was found that in both right side & left side edentulous patients there was significant increase in the mean AMV of the functional side temporalis muscle in relation to the nonfunctional side muscle, reflecting how much being the most affected muscle by unilateral edentulism. This finding coincides with the finding of Geers et al. (11) who mentioned that the anterior temporalis function mainly as a postural muscle of the mandible, thus playing a crucial role in suspending the mandible as an adaptive action towards unilateral loss of molar support, in addition to its

Table 2 - Results of measurement error and reliability coefficient in edentulous group (Right side) and (Leftside)

Side	Muscle	Right side			Left side		
		Error	Cronbach's alpha value	p-value	Error	Cronbach's alpha value	p-value
Right side	Temporalis	1.1	0.937	< 0.001*	0.8	0.971	< 0.001*
	Masseter	0.9	0.955	< 0.001*	0.6	0.982	< 0.001*
	Medial pterygoid	0.7	0.952	< 0.001*	0.7	0.951	< 0.001*
	Superior lateral pterygoid	0.3	0.978	< 0.001*	0.6	0.952	< 0.001*
	Inferior lateral pterygoid	0.7	0.952	< 0.001*	0.7	0.952	< 0.001*
	Temporalis	0.8	0.966	< 0.001*	0.5	0.986	< 0.001*
Left side	Masseter	0.7	0.962	< 0.001*	0.6	0.968	< 0.001*
	Medial pterygoid	1	0.978	< 0.001*	0.7	0.963	< 0.001*
	Superior lateral pterygoid	0.9	0.950	< 0.001*	0.9	0.952	< 0.001*
	Inferior lateral pterygoid	0.8	0.961	< 0.001*	0.8	0.970	< 0.001*

Legend: * = significant at $p \leq 0.05$.

Source: Research data.

role in contralateral mastication. Furthermore, it was previously mentioned that the activity of anterior temporal muscle is higher if there is no dental posterior contact exists, controlling jaw in excursive movements. (12-16).

Insignificant increase in the AMV of left side muscles including the masseter, medial pterygoid, superior lateral pterygoid and inferior lateral pterygoid muscles in right side edentulous patients, where patients with unilateral edentulism may be subjected to shift in the total force from the median line to the masticatory side during unilateral chewing (17).

Regarding the left side edentulous patients, there was an insignificant increase in the AMV regarding the right masseter, right medial pterygoid and right superior lateral pterygoid muscles except for the left inferior lateral pterygoid muscle which showed significant increase in its AMV, this could be due to the different duration of edentulism since the duration of loss was 2 years for most of patients, while in one patient the duration was 8 years which was the maximum duration of edentulism showing increase in the AMV of the right inferior lateral pterygoid muscle. This finding disagrees with the finding of Koca-Ceylan et al. (1) where they mentioned that the duration of edentulism had no effect since chewing duration during the day is very little so it may not change the muscle size in dentate and edentulous sides.

The control group showed increase in the AMV of left side muscles of mastication, except for the right SLP and ILP which showed increase in its AMV. This finding can be referred to left side preference in selected control sample, where (18, 19) mentioned that 66% of chewing occurred on one side only, and the food sample was replaced on either occlusal table by a combination of alternate tongue- and cheek pushing movements during the unilateral chewing cycle while the difference in ILP and SLP AMV, can be attributed to prominent role of ILP muscle in contra-lateral chewing. This finding is in accordance to the findings of Yamaguchi et al., (20) demonstrating the importance of the ipsilateral medial pterygoid and contralateral lateral pterygoid muscles during unilateral mastication.

Conclusion

Long term unilateral chewing affects the approximate muscular volume (AMV) of muscles of

mastication bilaterally, decreasing the AMV of the nonfunctioning side in relation to the dentulous side of the jaw. Two years duration isn't sufficient to affect the muscular volume bilaterally due to strong adaptive capabilities of the stomatognathic system. The temporalis muscle is the first muscle to be affected by long term unilateral chewing, while the inferior lateral pterygoid muscle is the most resistant muscle and the last muscle to be affected. MRI is a reliable imaging method for measuring and comparing the AMV of the masticatory muscles for detection of the effect of long term functional disabilities.

Acknowledgment

We would like to thank all MRI technicians in the department of Radiology, Kasr Al Aini Hospital, Cairo University for their help during our research. There aren't any potential conflicts of interest or sources of financial support regarding this research.

Referências

1. Koca-Ceylan G, Taskaya-Yilmaz N, Guler AU, Incesu L. The effect of unilateral partial edentulism to muscle thickness. *Saudi Med J.* 2003;24(12):1352-59.
2. Na S, Kang D. Comparative electromyographic analysis of masticatory muscles between bilateral and unilateral masticators. *J Korean Acad Prosthodont.* 2002;40(6):577-89.
3. Kumai T. Difference in chewing patterns between involved and opposite sides in patients with unilateral temporomandibular joint and myofascial pain-dysfunction. *Arch Oral Biol.* 1993;38(6):467-78.
4. Raustia AM, Oikarinen KS, Pyhtinen J. Densities and sizes of main masticatory muscles in patients with internal derangements of temporomandibular joint obtained by computed tomography. *J Oral Rehabil.* 1998;25(1):59-63.
5. Acer N, Sahin B, Bas O, Ertekin T, Usanmaz M. Comparison of three methods for the estimation of total intracranial volume: stereologic, planimetric & anthropometric approaches. *Am. Plast Surg.* 2007;58(1):48-53.

6. Acer N, Uğurlu N, Uysal DD, Unur E, Turgut M, Camurdanoğlu M. Comparison of two volumetric techniques for estimating volume of intracerebral ventricles using magnetic resonance imaging stereological study. *Anat. Sci Int.* 2010;85(3):131-9.
7. Gundersen HJG. Some new, simple and efficient stereological methods and their use in pathological research diagnosis. *APMIS.* 1988;96(5):379-94.
8. Abekura H, Kotani H, Tokuyama H, Hamada T. Asymmetry of masticatory muscle activity during intercuspal maximal clenching in healthy subjects and subjects with stomatognathic dysfunction syndrome. *J Oral Rehabil.* 1995;22(9):699-704.
9. Soboļeva U, Lauriņa L, Slaidiņa A. The masticatory system – an overview. *Stomatologija.* 2005;7(3):77-80.
10. Ferrario VF, Sforza C, Serra G. The influence of crossbite on the coordinated electromyographic activity of human masticatory muscles during mastication. *J Oral Rehabil.* 1999;26(7):575-581.
11. Geers C, Nyssen-Behets C, Cosnard G and Lengelé B. The deep belly of the temporalis muscle : an anatomical, histological and MRI study. *Surg Radiol Anat.* 2005;27(3):184-91.
12. Burdette BH, Gale EN. Reliability of surface electromyography of the masseteric and anterior temporal areas. *Arch Oral Biol.* 1990;35(9):747-51.
13. Kerstein RB. Combining technologies: a computerized occlusal analysis system Synchronized with a computerized electromyography system. *Cranio.* 2004; 22(2):96-109.
14. Moreno I, Sanchez T, Ardizzone I, Aneiros F, Celemin A. Electromyographic comparisons between clenching, swallowing and chewing in jaw muscles with varying occlusal parameters. *Med Oral Patol Oral Cir Bucal.* 2008; 13(3):E207-13.
15. Throckmorton GS, Dean JS. The relationship between jaw-muscle mechanical advantage and activity levels during isometric bites in humans. *Arch Oral Biol.* 1994; 39(5):429-37.
16. Throckmorton GS, Groshan GJ, Boyd SB. Muscle activity patterns and control of temporomandibular joint loads. *J Prosthet Dent.* 1990;63(6):685-95.
17. Peretta R, Melison M, Meneghello R, Comelli D, Guarda L, Galzignato P, Concheri G, Galzignato PF, et al. Unilateral masseter muscle hypertrophy: morphofunctional analysis of the relapse after treatment with botulinum toxin. *Cranio.* 2009;27(3);200-10.
18. Mioche L, Hiiemae KM, Palmer JB. A postero-anterior videofluorographic study of the intra-oral management of food in man. *Arch Oral Biol.* 2002;47(4):267-80.
19. Shinagawa H, Ono T, Ishiwata Y, Honda E, Sasaki T, Taira M, et al. Hemispheric dominance of tongue control depends on the chewing-side preference. *J Dent. Res.* 2003;82(4):278-83.
20. Yamaguchi S, Itoh S, Watanabe Y, Tsuboi A, Watanabe M. Quantitative analysis of masticatory activity during unilateral mastication using muscle fMRI. *Oral Dis.* 2011;17(4):407-13.

Received: 05/17/2012

Recebido: 17/05/2012

Approved: 07/21/2012

Aprovado: 21/07/2012