



Steven Johnson Syndrome

Síndrome de Steven Johnson

Ramachandran Sudarshan^[a], Rajeshwari G. Annigeri^[b], G. Sree Vijayabala^[c]

^[a] Senior Lecturer, Department of Oral Medicine and Radiology, Sibar Institute of Dental Sciences, Guntur - India, e-mail: sudharshanram@yahoo.co.in

^[b] Professor and Head, Department of Oral Medicine and Radiology, College of Dental Sciences & Hospital, Davangere - India, e-mail: vijiganesan17@yahoo.in

^[c] Senior Lecturer, Department of Oral Medicine and Radiology, Thai Moogambikai Dental College and Hospital, Chennai, Tamil Nadu - India, e-mail: rajeshwariannigeri@rediffmail.com

Abstract

Ulcerative vesiculobullous disorders are common in Dermatology and Oral Medicine. Diagnosis of these conditions is pretty effortless if they give a classic appearance as described in the literature. Steven Johnson syndrome is one such condition which is a type of erythema multiforme. It is a disorder involving mucous membrane, skin and even the multiple organs in severe form. Multiple etiologies persist so be acquainted with the cause and prohibit the root is crucial. But still drugs are considered to be common cause. Early management is vital as complications are serious for this condition even leading to death. We hereby report a typical case with classic appearance of Steven Johnson syndrome.

Keywords: Steven Johnson syndrome (SJS). Vesiculobullous. Target lesions. Mucocutaneous disorder.

Resumo

Doenças ulcerativas vesicobolhosas são comuns em Dermatologia e Medicina Oral. O diagnóstico destas condições é bastante fácil se apresentar uma aparência clássica, tal como descrito na literatura. Steven Johnson é um tipo de eritema multiforme. É uma desordem envolvendo as mucosas, pele e até múltiplos órgãos de forma grave. Múltiplas etiologias são apontadas como causa. Mas ainda os medicamentos são considerados como causas comuns. O tratamento precoce é vital, pois complicações são graves para essa condição, podendo levar à morte. Vimos por meio deste relatar um caso típico, com aparência clássica de Síndrome de Steven Johnson.

Palavras-chave: Síndrome de Steven Johnson (SJS). Lesões vesicobolhosas. Lesões-alvo. Lesões mucocutâneas.

Introduction

Steven Johnson syndrome (SJS), otherwise known as erythema multiforme majus, is thought to represent a continuum of disease, the most benign type of which is erythema multiforme. The syndrome is generally described as vesiculobullous erythema multiforme of the skin, mouth, eyes, and genitals (1). The mortality rate of SJS is high even in moderately severe cases it could be up to 30%. For those who survive, there could be troublesome late complications (2).

Case report

A 35 years old male patient presented to our department with the chief complaint of burning sensation in the eyes, oral cavity. Patient gave a history of severe headache 6 days back for which he took analgesics which was unknown. The symptoms started 2 days after this self medication as fever, malaise, difficulty in mastication, deglutition and burning eyes. His medical and family history revealed no abnormality. On cutaneous examination there was multiple asymmetric, atypical target lesions dispersed on forearms, thighs which had a dark centre surrounded by a pale zone with peripheral rim of erythema (Figure 1A). Mucous membrane examination revealed erosion on the penile and oral mucosa (Figure 1B and 1C).

Oral mucosa revealed blood encrustations involving the upper lip. Intact vesicle was seen in the buccal mucosa, labial mucosa with multiple ruptured vesicles involving anterior two-third of tongue, ventral surface of tongue. Ulcers were with irregular shape, with approximately 2 × 2 mm diameter, borders are irregular surrounded by erythematous borders. Ulcers are tender on palpation and bleeds on touch with serous discharge. Management of the condition with systemic prednisolone, topical benzocaine and nutritional supplements. Patient was referred to ophthalmologist for the management of burning eyes. Patient was recalled after one week and lesions were reviewed (Figure 2).

Discussion

In 1922, Stevens and Johnson described 2 patients, boys aged 7 and 8 years, who had an

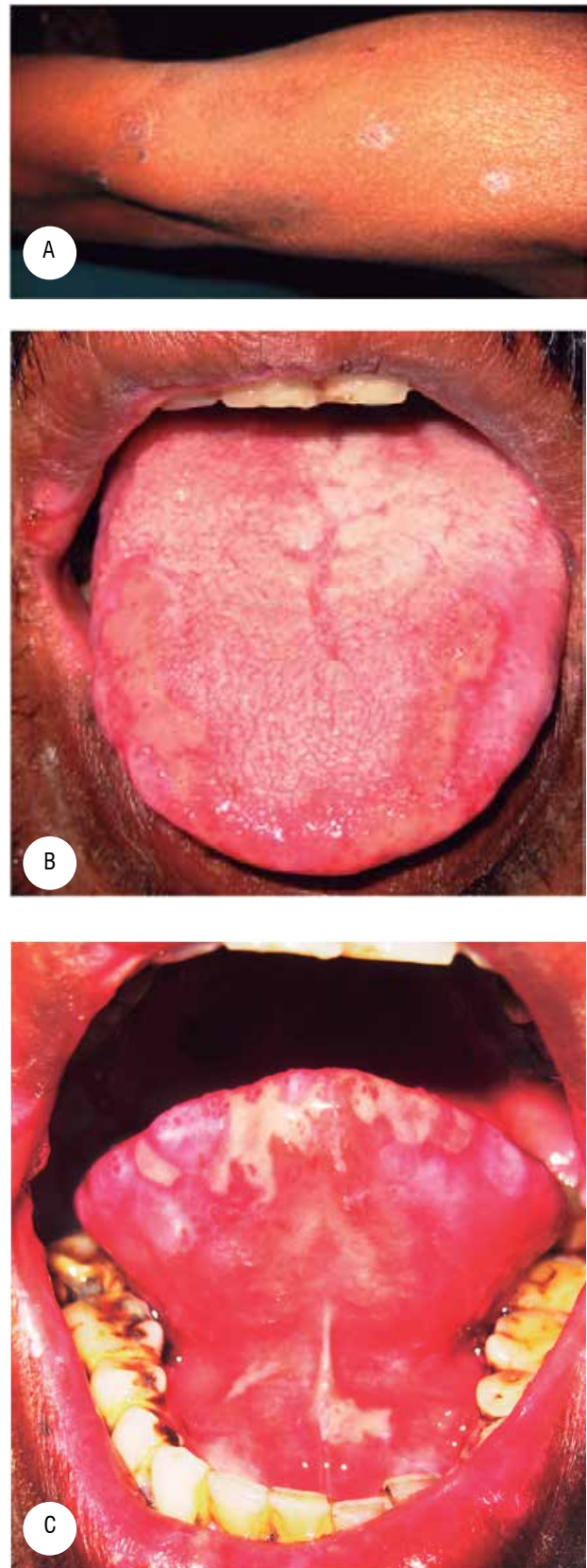


Figure 1 - (A) Target lesions on the skin; (B, C) Ruptured vesicle and bullae and ulcers

Source: Research data.

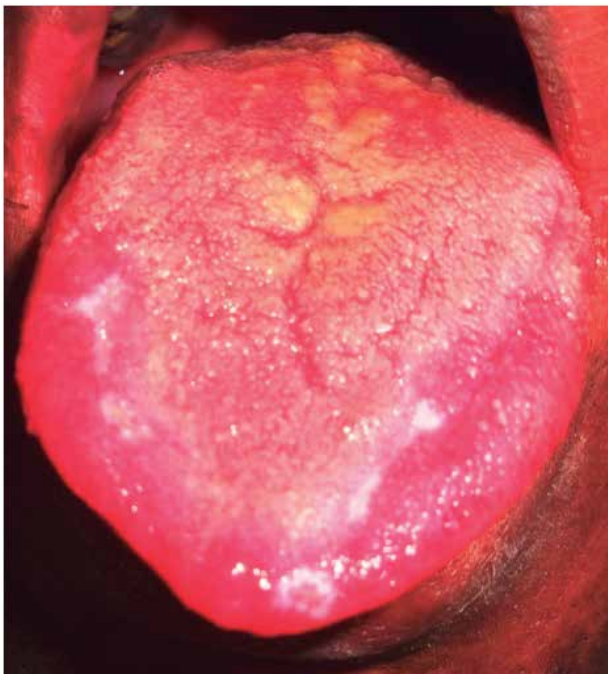
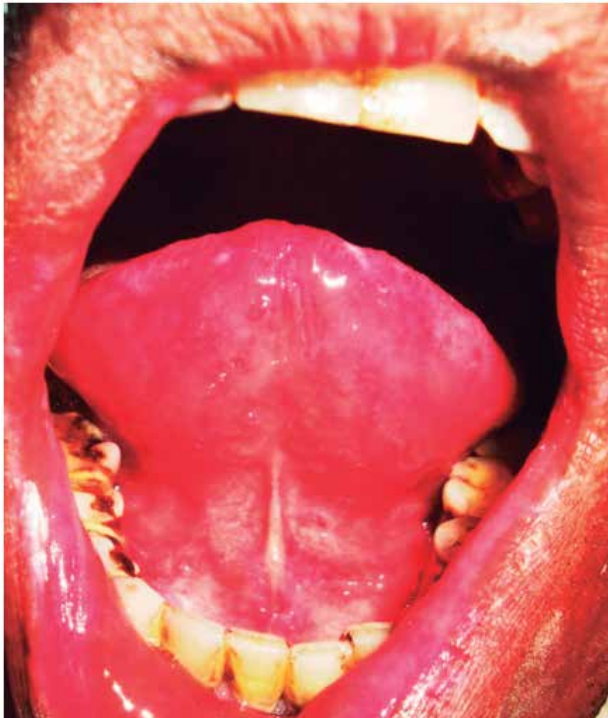
Figura 2 - Healed lesion after follow up
Source: Research data.

extraordinary, generalized eruption with continued fever and inflamed buccal mucosa. SJS had for years been considered an extreme variant of erythema multiforme (EM), with Toxic Epidermal Necrolysis (TEN) being a different entity (3).

The incidence of SJS is 1 -3 per million persons per year. Classification of SJS and TEN has been based on the degree of epidermal detachment. Epidermal detachment of less than 10% of the total body surface area is considered SJS, more than 30% as TEN, and between 10 and 30% as overlap SJS-TEN (4). So based on this classification our case falls under classification of SJS.

Many etiologic factors have been identified in the pathogenesis of Stevens-Johnson syndrome. It is usually categorized as iatrogenic, infectious, or idiopathic. Iatrogenic causes are usually drug related and include antibiotics and anticonvulsants, as well as a variety of anti-inflammatory agents. Determining the causative factor is often very difficult; and, occasionally, no known drugs have been ingested, making a definition of the etiology impossible. Idiopathic causes have been estimated to occur in approximately 18 to 22 percent of all cases. It is often difficult to determine whether a drug utilized in treatment of the infectious process is the culprit or whether an infectious microorganism has caused the disease (5). Similarly in our case determining the cause was complicated but history of an analgesic intake 5 days back could be the possible cause.

Stevens-Johnson syndrome is an immune-complex-mediated hypersensitivity disorder that may be caused by many drugs, viral infections, and malignancies. In up to half of cases, no specific etiology has been identified. Pathologically, cell death results causing separation of the epidermis from the dermis. The death receptor, Fas, and its ligand, FasL, have been linked to the process (6).

Sign and Symptoms of Stevens-Johnson syndrome includes rash, blisters, or red splotches on skin, persistent fever, blisters involving mucous membranes, swelling of eyelids, red eyes, conjunctivitis, flu-like symptoms, recent history of having taken a prescription or over-the-counter medication, target lesions are not always seen in SJS (6).

An early step in the management of the SJS is withdrawal of the offending drug to improve the outcome. Nutrition is an integral part of management as SJS/TEN is a hypermetabolic state and there are increased energy and protein dietary requirements which are proportional to the BSA affected (7). So the patient was advised to avoid self medication with higher intake of nutritional supplements.

The most common problem is conjunctiva involvement. General supportive care with 1-2-hourly

lubrication and early assessment by an ophthalmologist to prevent or manage these complications is indicated. Management should aim to keep these disabilities to a minimum (7).

Several agents have been tried for the management of this disorder. Systemic corticosteroids are used in the early stage of SJS and TEN. However, its use in SJS is still controversial but should not be recommended when extensive skin loss has already occurred. Thus, we prescribed corticosteroids (Betamethasone) to our patient as he was in the early stages of SJS. Chlorhexidine rinses help in maintaining good hygiene and white-soft paraffin on the lips relieves the pain (8).

Conclusion

Early diagnosis and management of Steven Johnson syndrome is well known and accepted reality as this condition may lead to multiple organ involvement and complications in the later stages. Multiple grounds have been revealed in the literature for this condition but drug was found to be a major cause. Similarly there was no other causes found to be related to our case except the medication this etiology can be considered in this case and proper counseling regarding the condition and avoidance of medication without proper consultation with a Physician was recommended.

References

1. Smelik M. Stevens-Johnson syndrome: a case study. *Permanente J.* 2002;6(1):29-31.
2. Ho H. Diagnosis and Management of Stevens-Johnson Syndrome and Toxic Epidermal Necrolysis. *Hong Kong Med J.* 2008;13(10):17-20.
3. Shetty SR, Chatra L, Shenai P, Rao PK. Stevens-Johnson syndrome: a case report. *J Oral Sci.* 2010;52(2):343-6.
4. Singalavanija S, Limpongsanurak W. Stevens-Johnson syndrome in Thai children: a 29-year study. *J Med Assoc Thai.* 2011;94(Suppl. 3):S85-90
5. Stitt VJ Jr. Stevens-Johnson syndrome: a review of the literature. *J Natl Med Assoc.* 1988;80(1):104-8.

6. Tyagi S, Kumar S, Kumar A, Singla M, Singh A. Stevens-Johnson syndrome – a life threatening skin disorder: a review. *J Chem Pharm Res.* 2010;2(2):618-26.
7. Lehloenya R. Management of Stevens-Johnson syndrome and toxic epidermal necrolysis. *Current Allergy Clin Immunol.* 2007;20(3):124-8.
8. Sudarshan R, Annigeri RG, Vijayabala GS. Steven Johnson Syndrome- a case report. *J Oral Health Res.* 2011;2(2):47-50.

Received: 06/20/2012

Recebido: 20/06/2012

Accepted: 08/14/2012

Aceito: 14/08/2012