



Radiographic assessment of the mandibular foramen in children: focus on anesthetic procedures

Avaliação radiográfica do forame mandibular em crianças: enfoque em procedimentos anestésicos

Patrícia do Nascimento Pereira^[a]; Ângela Fernandes^[b]; Renato Cordeiro Gugisch^[c]; Fabio Marzullo Zaroni^[d]; Ademir Franco^[e]; Nelson Luis Barbosa Rebellato^[f]

^[a] DDS, MSc, Stomatology, Federal University of Paraná, Brazil.

^[b] DDS, PhD, Stomatology, Federal University of Paraná, Brazil.

^[c] DDS, MSc, PhD, Paediatric Dentistry, Federal University of Paraná, Brazil.

^[d] DDS, Maxillofacial Surgery, Federal University of Paraná, Brazil.

^[e] DDS, MSc, PhD candidate, Forensic Odontology, Pontificia Universidade Católica do Paraná, Brazil and Katholieke Universiteit Leuven, Belgium.

^[f] DDS, MSc, PhD, Maxillofacial Surgery, Federal University of Paraná, Brazil

Abstract

Objective: The present study aims to evaluate the radiographic position of the mandibular foramen in children aged between 4 and 12 years. **Material and methods:** The sample consisted of 505 panoramic radiographs of male (n=242) and female (n=263) Brazilian children aged from 4 to 12 years. The panoramic radiographs were obtained for treatment purposes at the Pediatric Dental Clinics of the Federal University of Paraná, Brazil. Digital analysis was performed by an experienced radiologist using Radiocef Studio® 2 (Radiomemory®, Belo Horizonte, Brazil) software. The radiographic position of the mandibular foramen was assessed measuring the distance between an x-axis, parallel to the occlusal plan, and the center of the foramen. **Results:** The mandibular foramen was mostly detected below the x-axis in children younger than 7 years old and above the x-axis in older children. Spearman Correlation Coefficient revealed a significant association between the measured distance and the age of the studied children ($p < 0.001$). **Conclusion:** The radiographic position of the mandibular foramen varied according to age, indicating valuable applications in anesthetic pediatric dentistry.

Keywords: Mandibular nerve. Panoramic radiography. Pediatrics. Morphology. Anesthesia.

Resumo

Objetivo: O presente estudo objetivou a avaliação da posição do forame da mandíbula em crianças com idades entre 4 e 12 anos. **Material e métodos:** A amostra consistiu em 505 radiografias panorâmicas de crianças brasileiras do sexo masculino (n=242) e feminino (263) entre 4 e 12 anos de idade. As radiografias foram obtidas de pacientes em tratamento odontológico na clínica de Odontopediatria da Universidade Federal do Paraná, Brasil. A análise das imagens foi realizada por um radiologista experiente utilizando o software Radiocef Studio® 2 (Radiomemory®, Belo Horizonte, Brasil). A posição radiográfica do forame da mandíbula foi avaliada pela mensuração da distância entre um plano horizontal paralelo ao plano oclusal e o centro anatômico do forame da mandíbula. **Resultados:** O forame da mandíbula foi localizado abaixo do plano horizontal em crianças com idade igual ou inferior a 7 anos. Associação estatística significativa entre as variáveis "idade" e "distância mensurada" foi observada por meio do Coeficiente de Correlação de Spearman ($p < 0,001$). **Conclusão:** A posição radiográfica do forame da mandíbula variou significativamente de acordo com a idade dos pacientes estudados, indicando potencial aplicação para a anestesiologia pediátrica.

Palavras-chave: Nervo Alveolar Inferior. Radiografia panorâmica. Odontopediatria. Anatomia. Anestesia.

Introduction

The inferior alveolar nerve (IAN) is responsible for carrying sensitive activity to the mandibular dentition and adjacent periodontal tissues such as bone and gingiva (1). The IAN penetrates the mandible through the mandibular foramen, which is a bone opening located on the medial surface of the mandibular ramus (2). Therefore, the mandibular foramen plays a valuable clinical role as a radiographic landmark during anesthetic procedures (3). Most of the medical literature associates the importance of radiographically detecting the position of the mandibular foramen with surgical procedures in adults such as the sagittal split ramus osteotomy (4). On the other hand, studies aiming pediatric applications are scarce. The usefulness of locating the mandibular foramen in children consists of optimally planning anesthetic procedures for clinical interventions (5, 6) such as dental restorations and extractions; root canal treatments; oral biopsies; and management of mandible fractures (7). In this context, the present research aims to investigate the position of the mandibular foramen in panoramic radiographs of children aged between 4 and 12 years, consequently enhancing clinical performances and supporting the medical literature.

Material and methods

The present cross-sectional observational study was approved by the Research Ethics Committee,

Health Sciences Section, Federal University of Paraná, Brazil, under the registration code no. 1090.015.11.03. All the following procedures were in accordance with the ethical standards of the responsible committee on human experimentation and with the Helsinki Declaration of 1975, revised in 2000.

The sample consisted of 505 panoramic radiographs of male (n=242) and female (n=263) Brazilian children, aged between 4 and 12 years (Table 1). All the involved children were treated at the department of Pediatric Dentistry – Federal University of Paraná, Brazil, in the years between 2000 and 2010. The inclusion criteria consisted of selecting male and female patients aged from 4 to 12 years. The exclusion criteria consisted of not selecting patients with low quality panoramic radiographs, systemic pathologies, and local pathologies visible in panoramic radiographs. All the panoramic radiographs were obtained using an Orthopos® (Siemens AG®, Berlin, Germany) device, and digitalized using an HP Scanjet G4050® (Hewlett – Packard Co.®, Colorado, USA) in high resolution. The images were saved as TIFF files and analyzed using Radiocef Studio® 2 (Radiomemory®, Belo Horizonte, Brazil) software.

In order to standardize measurements and to calculate the radiographic position of the mandibular foramen, some morphologic references were considered such as: 1) a landmark named FM, placed in the center of the mandibular foramen; 2) an x-axis horizontal line (HL), extending from the mesial marginal ridge of the first

mandibular molar to the posterior border of the mandibular ramus, crossing the contact points of the posterior teeth; 3) a vertical line (VL), perpendicular to HL crossing FM, extending from the highest point of the mandible's coronoid process to the mandible angle (Figure 1). The distance between FM and the HL indicates the radiographic position of the mandibular foramen.

A single examiner analyzed the images. However, a second experienced radiologist was consulted for calibration purposes. Calibration tests were performed to assess the agreement between the examiners applying Weighted Kappa statistics and Interclass Correlation Coefficient. The examiners analyzed 20 panoramic radiographs twice within an interval of 15 days. An optimal level of calibration was achieved once the inter- and intra-agreement level reached 80% (0.80) or more. Moreover, the association between the position of the mandibular foramen and the respective age was calculated using Spearman Correlation Coefficient. The association between the position of the mandibular foramen and the patient's gender was investigated applying Mann-Whitney test. Results were considered statistically significant once p-values were below 5% (0.05). Statistics was performed using SPSS 15.0® (Statistical Package for the Social Sciences®, Illinois, USA).

HL: horizontal line (x-axis) from the mesial marginal ridge of the first mandibular molar to the posterior border of the mandibular ramus, crossing the marginal ridges of the posterior teeth; FM: central area of the mandibular foramen; VL: vertical line from the highest point of the coronoid process of the mandible to the mandibular angle crossing FM. The distance between HL and FM indicates the radiographic position of the mandibular foramen.

Results

Weighted Kappa statistics and Interclass Correlation Coefficient revealed optimal calibration (above 80% of agreement level). In 65% of the panoramic radiographs, the mandibular foramen was detected below the horizontal line (negative values). The median distance between FM and HL was -1.17mm, varying from -4.43 mm to 5.08 mm (Table 2). The association of the distance between FM and HL regarding age was statistically significant ($p < 0.001$). The association of the distance between FM and HL regarding the gender was not statistically significant ($p = 0.284$).

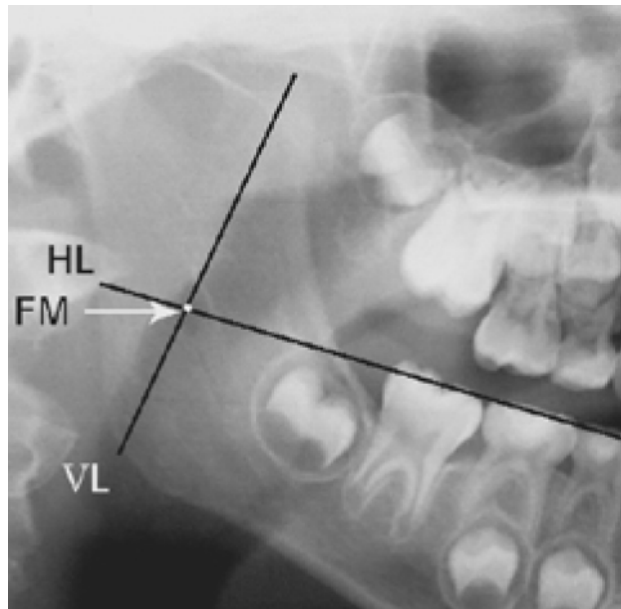


Figure 1 - Illustrative assesment of the radiographic position of the mandibular foramen

Table 1 - Sample distribution according to age and gender

Gender	Years of age									Total
	04	05	06	07	08	09	10	11	12	
Male	16	21	47	41	44	38	23	09	03	242
Female	20	32	39	50	47	45	23	04	03	263
Total	36	53	86	91	91	83	46	13	06	505

Table 2 - Distance between the mandibular foramen (FM), in relative to the horizontal line (HL) expressed in millimeters (mm)

	Age (years)								
	04	05	06	07	08	09	10	11	12
Mean	-2.31	-2.12	-1.52	-0.88	-0.61	0.19	0.78	1.23	1.10
SD*	0.82	0.75	1.06	1.15	1.15	1.37	1.55	1.28	1.83
Median	-2.34	-2.08	-1.56	-1.17	-0.78	0.00	1.11	1.17	1.62

*SD - Standard deviation.

Discussion

Pain management is the key when dealing with children in the routine of pediatric dentistry (8). In this context, correctly performing anesthetic techniques prior to surgical procedures becomes essential. An important clinical situation in pediatric dentistry involves the treatment of permanent mandibular first molars, which are the first permanent teeth to reach complete clinical eruption. Commonly, parents consider the permanent mandibular first molar as a deciduous tooth by mistake, providing less attention and care than necessary (9). Consequently, dental restorations, root canal treatments, and even dental extractions become necessary. Most of these clinical procedures are performed under anesthesia of the IAN. In order to perform adequate blocking of the IAN, the radiographic position of the mandibular foramen is assessed.

The position of the mandibular foramen highly varies in children due to the constant mandibular growth. Specifically, the present study investigated the position of the mandibular foramen regarding a horizontal line crossing the interdental contact points of the mandibular posterior teeth. The obtained results indicate that the position of the mandibular foramen trends to locate upwards in the mandibular ramus according to aging process. Similarly, Minarelli and Ramalho (10) used the contact points of mandibular molars to state that the mandibular foramen was located below the reference line in Brazilian children younger than 7 years old. Yet, Tsai (11) and Poonacha et al. (12) investigated the position of the mandibular foramen regarding the height of the alveolar bone crest. Despite the different methodology, similar outcomes were obtained. On the other hand, Kanno et al. (6) considered the molar cusps as a basis for a reference line. The authors observed a higher position of the mandibular

foramen if compared to the present study. More specific, the present study revealed a gradual decrease of 0.5mm for the age range between 4 and 8 years, in the distance between the mandibular foramen and the reference line, which is parallel to the occlusal plan. This finding suggests that dentists must approach the needle closer to the occlusal plan as the pediatric patient becomes older. The same was observed by Minarelli and Ramalho (10). In age ranges above 9 years, the distance between the mandibular foramen and the horizontal line gradually increased, as also observed by Kanno et al. (6). Apart from the surgical management of pediatric patients, these findings also encourage further forensic studies based on age estimation techniques, since age was strongly associated with the position of the mandibular foramen in children.

As described in the study of Tsai (11), statistical significance was not detected associating gender and the position of the mandibular foramen. However, Kanno et al. (6) observed a larger distance between the mandibular foramen and the reference line in males aged above 9 years. It may be justified due to the smaller sample and age range addressed, which consisted of 154 patients aged between 7 and 10 years.

Finally, the use of panoramic radiographs could represent a limitation within the presented methodology, once measurements are not as accurate as performed in computed tomography images. However, already in 1986, Larheim and Svanaes (13) validated the use of panoramic radiographs for metrical analysis, stating that despite transforming a 3D information into a 2D image, this imaging modality preserves acceptable levels of morphologic proportions. Additionally, the radiation dose of computed tomography exams is excessively higher compared to conventional radiographs (14), making the present study more compatible to the routine of pediatric imaging and dental treatments.

Conclusion

The present outcomes showed a statistically significant association between the position of the mandibular foramen and specific age ranges. Consequently, the present study scientifically supports anesthetic procedures prior to operative interventions in pediatric patients. In general, our findings suggested that the needle should be inserted downwards the occlusal plan in children younger than 8 years old during inferior alveolar nerve blocking. Moreover, in children older than 8 years old, the needle should be inserted upwards the occlusal plan.

References

1. Kuczynski A, Kucharski W, Franco A, Westphalen FH, Lima AAS, Fernandes A. Prevalence of bifid mandibular canals in panoramic radiographs: a maxillofacial surgical scope. *Surg Radiol Anat* 2014;36:847-50.
2. Lipski M, Tomaszewska IM, Lipska W, Lis GS, Tomaszewski KA. The mandible and its foramen: anatomy, anthropology, embryology and resulting clinical implications. *Folia Morphol* 2013;72:285-92.
3. Findik Y, Yildirim D, Baykul T. Three-dimensional anatomic analysis of the lingual and mandibular foramen: a cone beam computed tomography study. *J Craniofac Surg* 2014;25:607-10.
4. Alves N, Deana NF. Morphometric study of mandibular foramen in macerated skulls to contribute to the development of sagittal split ramus osteotomy (SSRO) technique. *Surg Radiol Anat* 2014;36:839-45.
5. Kang SH, Byun IY, Kim JH, Park HK, Kim MK. Three-dimensional anatomic analysis of mandibular foramen with mandibular anatomic landmarks for inferior alveolar nerve block anesthesia. *Oral Surg Oral Med Oral Pathol Oral Radiol* 2013;115:17-23.
6. Kanno CM, Oliveira JA, Cannon M, Carvalho AAF. The Mandibular Lingula's Position in Children as a Reference to Inferior Alveolar Nerve Block. *J Dent Child* 2005;72:56-60.
7. Yassen GH. Evaluation of mandibular infiltration versus mandibular block anesthesia in treating primary canines in children. *Int J Paediatr Dent* 2010;20:43-9.
8. Waits J, Cretton-Scott E, Childers NK, Sims PJ. Pediatric psychopharmacology and local anesthesia: potential adverse drug reactions with vasoconstrictor use in dental practice. *Pediatr Dent* 2014;36:18-23.
9. Pine CM, Pitts NB, Nugent ZJ. British association for the study of community dentistry (BASCD) guidance on sampling for surveys of child dental health. A BASCD coordinated dental epidemiology program quality standard. *Dent Health* 1997;14:10-7.
10. Minarelli AM, Ramalho LRT. The mandibular foramen position in function of growth: anthropometric study in radiographs of children. *Rev Bras Cien Morfol* 1989;6:100-4.
11. Tsai HH. Panoramic radiographic findings of the mandibular foramen from deciduous to early permanent dentition. *J Clin Pediatr Dent* 2004;28:215-9.
12. Poonacha KS, Shigli AL, Indushekar KR. Relative position of the mandibular foramen in different age groups of children: a radiographic study. *J Ind Soc Pedod Prev Dent* 2010;28:173-8.
13. Larheim TA, Svanaes DB. Reproducibility of rotational panoramic radiography: mandibular linear dimensions and angles. *Am J Orthod Dentofacial Orthop* 1986;90:45-51.
14. Miglioretti DL, Johnson E, Williams A, Greenlee RT, Weinmann S, Solberg LI, et al. The use of computed tomography in pediatrics and the associated radiation exposure and estimated cancer risk. *JAMA Pediatr* 2013;167:700-7.

Received:09/22/2014

Recebido:22/09/2014

Accepted:03/10/2015

Aceito: 10/03/2015