

# Breathing pattern, orthognathic surgery and head posture in dentofacial deformity

*Padrão respiratório, cirurgia ortognática e postura de cabeça na deformidade dentofacial*

Rogério Eduardo Santos Tiossi Castello Branco <sup>1</sup>

Letícia Korb <sup>2</sup>

Reinaldo Monteiro Marques <sup>1</sup>

Raquel Rodrigues Rosa <sup>3\*</sup>

Giédre Berretin-Felix <sup>3</sup>

<sup>1</sup> Faculdades Integradas de Bauru (FIB), Bauru, SP, Brazil

<sup>2</sup> Hospital Cristo Redentor, Marau, RS, Brazil

<sup>3</sup> Universidade de São Paulo (USP), Bauru, SP, Brazil

**Date of first submission:** March 1, 2021

**Last received:** November 25, 2021

**Accepted:** December 14, 2021

**Associate editor:** Janice Luisa Lukrafka Tartari

\* **Correspondence:** raquel-fono@usp.br

## Abstract

**Introduction:** Dentofacial deformity (DFD) and the breathing mode can change the head posture. However, head posture changes after orthognathic surgery are controversial, and no studies were found on the relationship between the head posture and breathing mode in adults with DFD. **Objective:** To identify the main head posture changes in young adults affected by DFD, to verify if orthognathic surgery modifies the breathing mode and head posture, and if the breathing mode is associated with the head posture. **Methods:** Twenty-five young adults were assessed and divided in dentofacial deformity group (DFD;  $n = 15$ ;  $\bar{x} = 28$  years) and control group with dentofacial harmony (CG;  $n = 10$ ; balanced by gender and age with the study group). Breathing mode was evaluated according to the orofacial myofunctional evaluation protocol, and biophotogrammetry was used in the head posture analyses. For the DFD group, the evaluations were performed pre and post the orthognathic surgery (pre- and post-DFD). **Results:** For the DFD group, the breathing mode modified after orthognathic surgery ( $p = 0.003$ ), but with difference from GC ( $p = 0.027$ ). No changes were found in head posture after orthognathic surgery, but significant difference was seen between post-DFD and GC for head inclination ( $p = 0.017$ ). No relationship was observed between breathing mode and head posture ( $p > 0.05$ ). **Conclusion:** After orthognathic surgery, a spontaneous improvement of breathing was seen in the sample. It was not possible to verify changes in head posture and association with breathing mode and head posture.

**Keywords:** Malocclusion. Mouth breathing. Orthognathic surgery. Posture.

## Resumo

**Introdução:** A deformidade dentofacial (DDF) e o modo respiratório podem alterar a postura de cabeça. Entretanto as modificações da postura de cabeça após a cirurgia ortognática são controversas e não foram encontrados estudos que apontassem relação entre a postura de cabeça e o modo respiratório em adultos com DDF. **Objetivo:** Identificar as principais alterações na postura de cabeça em adultos jovens com DDF, verificar se a cirurgia ortognática altera o modo respiratório e a postura de cabeça e se o modo respiratório está associado com a postura de cabeça. **Métodos:** Foram avaliados 25 jovens adultos, os quais foram divididos no grupo deformidade dentofacial (DDF;  $n = 15$ ;  $\bar{x} = 28$  anos) e grupo controle com harmonia dentofacial (GC;  $n = 10$ ; equilibrados por gênero e idade com o grupo de estudo). O modo respiratório foi analisado de acordo com o protocolo de avaliação miofuncional orofacial e a postura de cabeça foi avaliada por meio da biofotogrametria. Para o grupo DDF, as avaliações foram realizadas antes e após a cirurgia ortognática (pré e pós-DDF). **Resultados:** Para o grupo DDF, o modo respiratório se modificou após a cirurgia ortognática ( $p = 0,003$ ), porém com diferença em relação ao GC ( $p = 0,027$ ). Não houve modificação na postura de cabeça após a cirurgia ortognática, porém observou-se diferença significativa entre os grupos pós-DDF e GC para a inclinação de cabeça ( $p = 0,017$ ). Não observou-se relação entre o modo respiratório e a postura de cabeça ( $p > 0,05$ ). **Conclusão:** Após a cirurgia ortognática, notou-se melhora espontânea da respiração na amostra estudada. Não foi possível verificar modificações na postura de cabeça e associação entre modo respiratório e postura de cabeça.

**Palavras-chave:** Má oclusão. Respiração bucal. Cirurgia ortognática. Postura.

## Introduction

Body posture is related to the postural attitude, which is the general position of the joints in the body at one given time.<sup>1</sup> A proper posture contributes to an individual's well-being, a state of muscular and skeletal balance that protects the body structures, resulting in the alignment of all joints of the body.<sup>2</sup> However, dentoskeletal malocclusion, present in individuals with

dentofacial deformities (DFD), is described as a cause of postural changes<sup>3-5</sup> since the sensory information related to dental occlusion contribute to head orientation.<sup>6</sup>

Some authors state that patients with malocclusion present altered head posture (HP) characterized by extended head in the presence of class II,<sup>3,4</sup> and flexed head and tilted to the left in patients with class III malocclusion.<sup>4,5</sup> In addition, the oral breathing mode is often associated to DFD<sup>7</sup> due to the influence of breathing function on the craniofacial growth and development.<sup>8</sup> This breathing mode has also been linked to postural problems.<sup>9</sup>

DFD can be treated by orthognathic surgery aimed at repositioning the maxilla and/or mandible in the three planes of space.<sup>6</sup> One study showed that the orthognathic surgery does not result in significant change in HP;<sup>10</sup> however, others found improvement of the tilted natural HP,<sup>11</sup> increase of craniomandibular angle,<sup>12</sup> and posterior displacement of the head with correction of cervical lordosis.<sup>13</sup>

Few studies link changes in body posture with individuals presenting with DFD and oral breathing, and to our knowledge studies relating body posture to the breathing pattern in patients with DFD were not found either. Thus, the present study hypothesized that young adults with DFD and indication for orthognathic surgery show changes in the cervical region influenced by their respiratory pattern, that such postural deviations are not corrected by surgery, and that they are not similar to the control group.

This study aimed to identify the main postural changes in young adults with DFD, indicated for orthognathic surgery, assessing whether there is relationship between the breathing mode and body posture in these individuals. And also, to verify if the orthognathic surgery for DFD correction modifies the breathing mode and the body posture of these subjects.

## Methods

This is a non-randomized clinical trial. From the intervention (orthognathic surgery), a comparative analysis of the experimental group with a control group (CG) was performed.

The project was approved by the local Institutional Review Board, under resolution no. 648.778/2014.

## Sample

The experimental group consisted of 15 young adults with DFD, of both genders, in the age range 18 - 38 years ( $\bar{x}$  = 28 years), being ten with skeletal class II malocclusion and five with class III malocclusion, in orthodontic preparation for orthognathic surgery. The assessments were performed pre (one or two weeks prior to surgery) and post the orthognathic surgery (three to six months following surgery). The skeletal malocclusion was defined by the dentist based on facial morphologic analysis, with facial and oral photography, plaster model and radiographies, including the cephalometric landmarks (to visualize skeletal patterns examples, see Gunarathne et al.'s article<sup>14</sup>).

The CG included 10 young adults, matched by gender and age with the study group, with nasal breathing and dentofacial harmony (good relationship between dental arches with vertical and horizontal overlap between 1 and 4 mm, natural teeth, at least up to the second premolar and medium facial type). Both groups included individuals with good general and oral health, whose information was obtained in the interview, surveying the speech therapy history, as well as in the orofacial myofunctional assessment.

## Procedures

Data of the interview (clinical history) and orofacial myofunctional assessment protocol MBGR,<sup>15</sup> adapted for this research, were collected by a speech therapist of the research group. Specifically in terms of breathing, individuals who remained with the jaw elevated, the lips closed and/or the tongue in contact with a region of the hard palate, at rest, were classified as nasal breathers

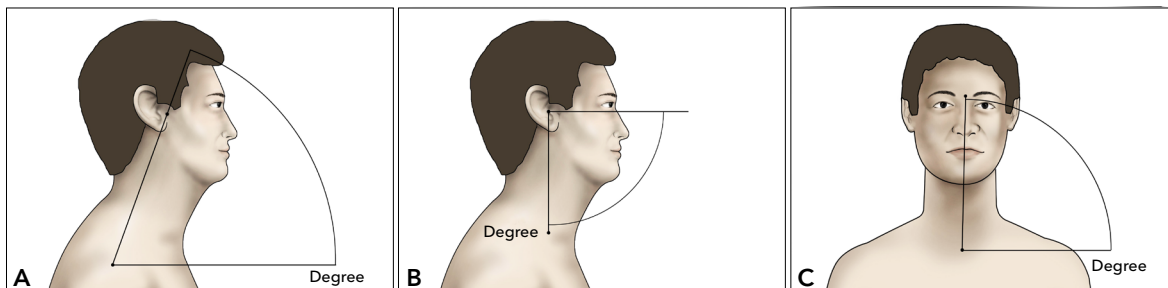
(score 0). The presence of a lowered jaw, parted lips and an unsystematic sealing of the oral cavity, at rest, was rated as oronasal breathing (score 1). Individuals with parted lips at rest, lowered jaw and low tongue in the oral cavity floor were classified as oral breathers (score 2).

For photographic documentation, they remained in the standing position, in habitual posture, keeping their feet aligned and guiding weight distribution across the plantar area, as they were photographed in frontal and profile positions.

Head posture was analyzed by digital photographic assessment (biophotogrammetry), using a Sony Cyber Shot DSC H9 digital camera (Sony Electronics Inc.; San Diego, CA, USA), on a tripod. Coronal (frontal view) and sagittal (right profile) planes were considered. Female subjects were photographed with top or sleeveless blouse, and males were photographed shirtless.

All photographs were analyzed by consensus between a physical education teacher and a physiotherapist. All subjects underwent the same type of evaluation, whose photos were analyzed using CorelDRAW X4 software (Corel Corporation; Ottawa, ON, Canada). The anatomical points used to the postural assessment were: acromion (ACR),<sup>5</sup> condyle of the temporomandibular joint (TMJ), external auditory canal (EAC), lower limit of the eye socket in the sagittal plane (LES), jugular vein incision of the manubrium of sternum (MS), and glabella (G) in the coronal plane.<sup>16,17</sup> Adaptations related to the anatomical points were made by the researchers, due to the need to evaluate only the HP of individuals.

To evaluate forward or backward head posture, a line was drawn between ACR and TMJ, and another one parallel to the ground (horizontal); an angle smaller than 87° meant the head was forward, and greater than 93° indicated that it was backwards (Figure 1a).



**Figure 1** - Analysis of head posture in sagittal plane (A = forward/backward, B = flexion and extension), and coronal plane (C = lateral inclination).

For the analysis of head flexion and extension, the head-neck angle was analyzed by the Frankfurt plane (formed by the line from the EAC to the LES) and the line perpendicular to the ground (vertical), the angle greater than 93° showing head extension, and smaller than 87° head flexion (Figure 1b). To check for lateral head inclination, in frontal view (coronal plane), two lines were drawn: one between the points in the MS and G, and one parallel to the ground (horizontal) (Figure 1c) - inclination to the left being considered when the formed angle between two straight lines was smaller than 87°, and inclination to the right when the formed angle was larger than 93° (reference values 90° ± 3° were determined as described by Döhnert and Tomasi<sup>18</sup>).

### Statistical analysis

The results were recorded in a specific protocol, transcribed into Excel (Microsoft Corporation; Redmond, WA, USA) database and statistically analyzed using the software Statistica 10.0 (Informer Technologies, Inc.; Roseau Valley, DM), at a significance level of  $p < 0.05$ . The Wilcoxon test was used to compare the pre and post-DFD, and the Mann-Whitney test to compare the post-DFD with the CG for the breathing mode.

Concerning head posture, only the angle value with better statistical representation was selected. The paired

t-test was used to compare the pre- and post-DFD, and the Mann-Whitney and t-test were used to compare the post-DFD and CG. The correlation between breathing mode and head posture was tested by the Spearman Correlation test.

### Results

Table 1 shows the breathing mode score of DFD individuals pre and post the orthognathic surgery and the CG assessed by orofacial myofunctional clinical examination. When comparing the results, improvement was found in the breathing mode after orthognathic surgery, but the DFD group remained different from the CG.

In the comparative analyses of head posture, it was not possible to verify difference in the pre-DFD group when comparing class II and III for forward/backward ( $p = 0.939$ ), flexion/extension ( $p = 0.106$ ) and inclination ( $p = 0.540$ ), and in pre- and post-DFD considering the whole group (class II + class III). However, significant difference was found between values for individuals with post-DFD and the CG for head inclination (Table 2).

Table 3 shows the correlation data between breathing mode and head posture in individuals with DFD pre and post the orthognathic surgery. It was not possible to note relationship in any analyzed aspect.

**Table 1** - Breathing mode score by orofacial myofunctional clinical assessment protocol to the dentofacial deformity group (pre- and post-DFD) and the control group (CG)

Breathing mode score	Pre-DFD	Post-DFD	CG	p-value (Pre x Post)	p-value (Post x CG)
Median	1	0	0		
25%	1	0	0	0.003*	0.027**
75%	2	1	0		

Note: Score: 0 = nasal breathing; 1 = oronasal breathing; 2 = oral breathing. \*Difference of breathing mode in the DFD group after orthognathic surgery ( $p < 0.05$ , Wilcoxon test). \*\*Difference between post-DFD and CG ( $p < 0.05$ , Mann-Whitney test).

**Table 2** - Head posture analysis for individuals with dentofacial deformity (DFD) pre and post the orthognathic surgery and the control group (CG)

Head posture parameters	Pre-DFD	Post-DFD	CG	p-value (Pre x Post)	p-value (Post x CG)
Forward/Backward (°)	79.60 ± 6.77	80.80 ± 6.14	82.60 ± 8.32	0.503	0.539
Flexion/Extension(°)	92.73 ± 6.64	92.07 ± 4.91	91.90 ± 5.34	0.686	0.937
Inclination (°)	89.73 ± 2.84	90.07 ± 2.43	92.40 ± 2.37	0.062	0.017*

Note: \*Difference between post-DFD and CG ( $p < 0.05$ ; Mann-Whitney test).

**Table 3** - Correlation between breathing mode and head posture for individuals with dentofacial deformity (DFD) pre and post the orthognathic surgery

Breathing x Head posture	Pre-DFD		Post-DFD	
	Head posture	p	r	p
Forward/Backward	-0.298	0.282	-0.362	0.185
Flexion/Extension	-0.062	0.828	-0.327	0.234
Inclination	-0.368	0.177	-0.255	0.360

## Discussion

This study aimed at verifying the main postural changes of the craniocervical region in young adults with DFD, before and after orthognathic surgery, and if the breathing mode is associated with possible postural changes. Before orthognathic surgery, most individuals with DFD presented oronasal or oral breathing, in accordance with the literature that associated oral breathing to dentoskeletal malocclusion.<sup>7</sup> This result was expected, since the breathing function influences the pattern of craniofacial growth, leading to malocclusion.<sup>8,19</sup> After surgery, significant improvement was observed in the breathing mode. These findings are consistent with a study<sup>20</sup> in which, following surgery by maxillary advancement, 87.8% of patients reported improvement in breathing. This result was related to an increased nasal cavity.

A spontaneous improvement of breathing was seen postoperatively; however, the DFD group maintained the difference to the CG. It is important to highlight that all CG individuals were nasal breathers, and the literature has pointed that surgical procedure influences the pharyngeal airway space.<sup>10</sup> Although this study did not investigate the nasopharyngeal airway space, probably this space did not change in those individuals who did not improve breathing after surgery.

Head posture was studied in relation to lateral inclination, forward and backward head posture, flexion and extension, by photogrammetry. Among the different parameters assessed, the values were similar between patients with skeletal class II and III malocclusions, different from findings in the literature that reported extended head posture in class II,<sup>3,4</sup> and flexed and tilted to the left in patients with class III malocclusion.<sup>4,5</sup> Such discrepancies in the results may derive from methodological differences between studies, because only one used photogrammetry,<sup>5</sup> but with other anatomical points.

After orthognathic surgery, the head posture characteristics of individuals were not modified, confirming the results of authors who found no change in the posture of patients submitted to this surgery,<sup>10</sup> and disagreeing with other studies that found differences.<sup>11-13</sup> It is known that the balance between dental occlusion, myofascial structures and craniocervical bones holds the head posture,<sup>21</sup> and the individuals in this study received correction of dental occlusion and were not submitted to postural treatment. This may justify the lack of difference pre and post orthognathic surgery.

When comparing the results of head posture evaluation for individuals in DFD and CG, significant difference was found only for head inclination, in accordance with a study that found tendency to lateral deviation in class III patients.<sup>5</sup> This maintenance of head position might be related with vestibular disorders to prevent stimulating the proprioceptors in this region.<sup>5</sup> However, the present study did not investigate disorders of the vestibular system to prove it.

Finally, it was not possible to note correlation between breathing mode and head posture. Although oral breathing has been linked to postural problems,<sup>9</sup> some studies did not find difference in head posture between oral and nasal breathers.<sup>22,23</sup> The cited studies were performed on children and adolescents and, to our knowledge, no studies were found with DFD patients for comparison.

This study had limitations. The final sample was limited for both groups. However, it is important to highlight that the study was conducted on a convenience sample composed by the greatest number of individuals who volunteered and accepted to participate in the study. Also, some individuals in the experimental group did not return for evaluations after orthognathic surgery and could not be included in the study, which impaired the inclusion of a greater number of individual.

The sample power was low and may have impaired the possibility to find greater significant samples between groups. However, it was difficult to achieve a large sample and no studies were found that related the body posture to the breathing pattern in patients with DFD. Therefore, the data achieved could aid future studies on larger samples, such as a systematic review.

Another limitation was the impossibility of a global postural evaluation, since according to some studies cited in the literature review, cases with DFD or oral/oronasal breathing mode present postural changes in other segments of the body, such as anterior displacement of the center of gravity,<sup>5</sup> change in positioning of the knee and body balance.<sup>9</sup> Also, the compensatory action of the muscular function for forward head positioning can lead to fatigue and discomfort to the neck region,<sup>1</sup> especially for adults and older adults.<sup>24</sup> Thus, further research to complement the findings of this work is necessary.

Despite the aforementioned limitations, this study evidenced the relationships between DFD, breathing mode and body posture, specifically with regard to HP, by a method not yet applied to such population. The anatomical points were selected for HP assessment, using standards cited by Sanchez et al.,<sup>16</sup> and Carneiro et al.,<sup>17</sup> adapted to the reality of this study.

Hence, it is expected that the findings of this research can direct multidisciplinary teams of dentists, speech therapists, physiotherapists, physical educators, among others, in the processes of diagnosis and intervention of postural and orofacial myofunctional alterations related to DFD, in different stages of surgical-orthodontic treatment.

## Concluion

According to the findings obtained in this study, it was found that spontaneous improvement was observed in the breathing mode after orthognathic surgery, however with no change in head posture of DFD individuals. In head posture evaluation after orthognathic surgery, the angulations were different between subjects with DFD and CG only for head inclination; and it was not possible to verify relationship between breathing mode and head posture.

## Authors' contributions

GBF was responsible for the study conception and orientation, while RESTCB and RMM for the study design. RESTCB, RMM, LK and RRR were responsible for analysis and interpretation of data. RESTCB wrote the manuscript and the others revised it. All authors approved the final version.

## References

1. Fernández RF, Carter P, Muñoz S, Silva H, Venegas GHO, Cantin M, et al. Evaluation of validity and reliability of a methodology for measuring human postural attitude and its relation to temporomandibular joint disorders. *Singapore Med J.* 2016;57(4):204-8. DOI
2. Kendall FP, McCreary EK, Provance PG, Rodgers MM, Romani WA. *Muscles testing and function with posture and pain.* Baltimore: Lippincott Williams & Wilkins; 2005. 480 p.
3. Sandoval C, Díaz A, Manríquez G. Relationship between craniocervical posture and skeletal class: A statistical multivariate approach for studying Class II and Class III malocclusions. *Cranio.* 2021;39(2):133-40. DOI
4. Liu Y, Sun X, Chen Y, Hu M, Hou X, Liu C. Relationships of sagittal skeletal discrepancy, natural head position, and craniocervical posture in young Chinese children. *Cranio.* 2016;34(3):155-62. DOI
5. Kulczynski FZ, Andriola FO, Deon PH, Melo DADS, Pagnoncelli RM. Postural assessment in class III patients before orthognathic surgery. *J Oral Maxillofac Surg.* 2018;76(2):426-35. DOI
6. Paya-Argoud M, Tardieu C, Cheynet F, Raskin A, Borel L. Impact of orthognathic surgery on the body posture. *Gait Posture.* 2019;67:25-30. DOI
7. Zicari AM, Albani F, Ntrekou P, Rugiano A, Duse M, Mattei A, et al. Oral breathing and dental malocclusions. *Eur J Paediatr Dent.* 2009;10(2):59-64. PubMed
8. Zheng W, Zhang X, Dong J, He J. Facial morphological characteristics of mouth breathers vs. nasal breathers: A systematic review and meta-analysis of lateral cephalometric data. *Exp Ther Med.* 2020;19(6):3738-50. DOI

9. Roggia B, Santos Filha VAV, Correa B, Rossi AG. Posture and body balance of schoolchildren aged 8 to 12 years with and without oral breathing. *Codas*. 2016;28(4):395-402. [DOI](#)
10. Aydemir H, Memikoglu U, Karasu H. Pharyngeal airway space, hyoid bone position and head posture after orthognathic surgery in class III patients. *Angle Orthod*. 2012;82(6):993-1000. [DOI](#)
11. Kim JY, Kang MH, You JY, Jee HG, Yi JW, Kim BH. Natural head postures of patients with facial asymmetry in frontal view are corrected after orthognathic surgeries. *J Oral Maxillofac Surg*. 2016;74(2):392-8. [DOI](#)
12. Lin X, Edwards SP. Changes in natural head position in response to mandibular advancement. *Br J Oral Maxillofac Surg*. 2017;55(5):471-5. [DOI](#)
13. Kulczynski FZ, Andriola FO, Deon PH, Melo DAS, Pagnoncelli RM. Postural assessment in class III patients before and after orthognathic surgery. *Oral Maxillofac Surg*. 2018;22(2):143-50. [DOI](#)
14. Gunarathne GWDA, Nawarathna LS, Nawarathna RD, Vithanaarachchi VSN. Prediction of the skeletal pattern of orthodontic patients. *Commun Stat Case Stud Data Anal Appl*. 2020;6(3):314-29. [DOI](#)
15. Marchesan IQ, Berretin-Félix G, Genaro KF. MBGR protocol of orofacial myofunctional evaluation with scores. *Int J Orofacial Myology*. 2012;38:38-77. [Full text link](#)
16. Sanchez HM, Barreto RR, Baraúna MA, Canto RST, Morais EG. Avaliação postural de indivíduos portadores de deficiência visual através da biofotogrametria computadorizada. *Fisioter Mov*. 2008;21(2):11-20. [Full text link](#)
17. Carneiro PR, Teles LCS, Cunha CM, Cardoso BS. Intra- and inter-examiner reliability of the head postural assessment by computerized photogrammetry. *Fisioter Pesqui*. 2014;21(3):217-22. [DOI](#)
18. Döhnert MB, Tomasi E. Validity of computed photogrammetry for detecting idiopathic scoliosis in adolescents. *Rev Bras Fisioter*. 2008;12(4):290-7. [DOI](#)
19. Grippaudo C, Paolantonio EG, Antonini G, Saule R, La Torre G, Deli R. Association between oral habits, mouth breathing and malocclusion. *Acta Otorhinolaryngol Ital*. 2016;36(5):386-94. [DOI](#)
20. Dantas JFC, Neto JNN, Carvalho SHG, Martins IMCLB, Souza RF, Sarmento VA. Satisfaction of skeletal class III patients treated with different types of orthognathic surgery. *Int J Oral Maxillofac Surg*. 2015;44(2):195-202. [DOI](#)
21. Thanathornwong B, Jalayondeja W. Vibrotactile - Feedback device for postural balance among malocclusion patients. *IEEE J Transl Eng Health Med*. 2020;8:2100406. [DOI](#)
22. Chambi-Rocha A, Cabrera-Domínguez ME, Domínguez-Reyes A. Breathing mode influence on craniofacial development and head posture. *J Pediatr (Rio J)*. 2018;94(2):123-30. [DOI](#)
23. Neiva PD, Kirkwood RN, Mendes PL, Zabjek K, Becker HG, Mathur S. Postural disorders in mouth breathing children: a systematic review. *Braz J Phys Ther*. 2018;22(1):7-19. [DOI](#)
24. Mahmoud NF, Hassan KA, Abdelmajeed SF, Moustafa IM, Silva AG. The relationship between forward head posture and neck pain: a systematic review and meta-analysis. *Curr Rev Musculoskelet Med*. 2019;12(4):562-77. [DOI](#)