



# Mechanisms of equine recurrent airway obstruction: changes in understanding and management

*Mecanismos da obstrução recorrente das vias aéreas dos equinos: mudanças no entendimento e na abordagem*

Fernanda Zettel Bastos, Fernanda Cristina Mendes Barussi, Cláudia Turra Pimpão, Pedro Vicente Michelotto Jr.\*

Department of Animal Science, Pontifícia Universidade Católica do Paraná (PUCPR), Curitiba, PR, Brasil

\*Autor correspondente  
E-mail: p.michelotto@pucpr.br

## Abstract

Recurrent airway obstruction (RAO) is an inflammatory and obstructive disease that is more prevalent in horses stabled for long periods. The most common clinical signs include cough, exercise intolerance, dyspnea, nasal secretion and absence of fever. The pathophysiological effects of RAO in the lungs include goblet cell metaplasia, alveolar fibrosis, neovascularization, airway wall thickening affecting all tissue layers, and bronchial smooth muscle hypertrophy. The alveolar macrophage is the main effector of particle elimination in the inflammatory process of RAO, with the ability to increase or suppress inflammatory responses. Activation of macrophages increases the release of cytokines that enhance the inflammatory reaction, such as interleukin-1, tumor necrosis factor alpha, and interleukin-8, resulting in the attraction of neutrophils to the alveolar environment, which becomes the predominant cell type during periods of crisis. Although the clinical signs of RAO are well-defined, the underlying immunologic mechanisms are still being investigated. This review provides information about this disease, the understanding of which has changed over time.

**Keywords:** Chemical Mediators. Equine Asthma. Inflammatory Response. Lungs.

## Resumo

*A Obstrução Recorrente das Vias Aéreas (ORVA) é uma doença inflamatória e obstrutiva, mais prevalente em cavalos estabulados por longos períodos. Os sinais clínicos mais comuns incluem tosse, intolerância ao exercício, dispnéia, secreção nasal e ausência de febre. A patofisiologia da doença nos pulmões inclui metaplasia de células caliciformes, fibrose alveolar, neovascularização, espessamento da parede das vias aéreas afetando todas as camadas de tecido e hipertrofia do músculo liso brônquico. O macrófago alveolar é o principal efetor*

*na eliminação de partículas no processo inflamatório de cavalos com ORVA, com a habilidade de aumentar ou suprimir a resposta inflamatória. A ativação dos macrófagos aumenta a secreção de citocinas que perpetuam a reação inflamatória, como a interleucina-1, fator de necrose tumoral alfa e interleucina-8, resultando na atração de neutrófilos ao ambiente alveolar, o que os torna o tipo celular predominante durante períodos de crise. Embora os sinais clínicos da ORVA sejam bem definidos, os mecanismos imunológicos envolvidos ainda estão sendo investigados. A presente revisão fornece informações sobre a ORVA, cuja compreensão mudou ao longo do tempo.*

**Palavras-chave:** *Asma Equina. Mediadores Químicos. Resposta Inflamatória. Pulmão.*

## Introduction

Recurrent airway obstruction (RAO) is an inflammatory and obstructive disease that is more prevalent in mature or older horses (7 years or older) (Couëtil et al., 2007; Aharonson-Raz et al., 2012), as well as athletes and horses stabled for long periods (Robinson et al., 2002; Marinkovic et al., 2007). Another RAO variant is found among horses at pasture during the summer months in subtropical regions (Venugopal et al., 2013). RAO is one of the most common conditions diagnosed in equine lungs (Bowles et al., 2002).

Chronic pulmonary inflammation starts with inhalation of organic dust containing endotoxins,  $\beta$ -D-glucan from molds, microorganisms, fungi spores, inorganic dust, or toxic gases present in the stable environment (Robinson, 2001; Couëtil et al., 2007). Feeding practices, specifically with hay, are the most important risk factor for RAO development and exacerbation, due to the presence of dust, toxins, and spores in the feed (Pirie et al., 2003; Bosshard and Gerber, 2014).

Airway injury in RAO is clinically characterized by a slight to intense cough, dyspnea at rest, decreased exercise tolerance, heave line formation due to the exaggerated use of the abdominal oblique muscle for exhalation, bilateral mucopurulent discharge, and bronchoconstriction (Robinson et al., 2002; Couëtil et al., 2007). Fever is absent, and during auscultation, prominent respiratory sounds are heard because of airway obstruction and breathing efforts, including crepitation and whistle sounds at many time points during the examination (Kutasi et al., 2011; Aharonson-Raz et al., 2012; Tilley et al., 2012).

Although many mechanisms of RAO remain

unknown, new research has shed light on our understanding of the effects of physical, chemical, and structural changes in the microenvironment of affected horses. Thus, this review discusses the recent changes in our understanding of RAO.

## Pathophysiology

The anatomical configuration of the airborne system has a singular role in preventing and reducing the invasion of noxious inhalable material into the lungs. The coiled arrangements of the nasal conchae create enormous turbulence, generating centrifugal forces upon larger particles. Airway embranchment also generates centrifugal forces that are less powerful in small bronchi and bronchioles (Carlton and McGavin, 1998). However, the recurrent exposure of the airways to viruses, bacteria, and other harmful particles may lead to lesions of the airway epithelium, loss of cilia, and desquamation of epithelial cells in bronchioles and bronchi. This exposure allows the antigen to establish direct contact with immunologically active tissue, and as a result, the respiratory tissues become sensitized. This response, in a horse predisposed to RAO, may have a hypersensitive, hyperreactive or hyperresponsive profile (McPherson and Lawson, 1974; Moore et al., 2004).

## Hyperresponsiveness

Hyperresponsiveness is a characteristic of RAO manifested via bronchoconstriction in response to nonspecific stimuli, such as cold air inhalation,

noxious gases, dust particles, and environmental management (Westergrenn, 2013). Therefore, in response to minimum levels of stimuli, a susceptible horse develops bronchospasms, whereas a normal horse would not (Robinson, 2001). Among older horses with chronic RAO, structural airway modifications may occur, leading to an increase in respiratory dysfunction, peribronchial muscle hypertrophy, and irreversible bronchiectasis (Lavoie et al., 2004). The causes of hyperresponsiveness include airway wall thickening, smooth muscle hypertrophy, suppression of inhibitory mechanisms that limit smooth muscle contraction (Nelson et al., 2003; Herszberg et al., 2006), and the action of inflammatory mediators on cholinergic nerves and muscles, which contributes to muscle contraction (Olszewski et al., 1999). With this hyperresponsive profile, it is normal for RAO to recur, leading to changes in the lower respiratory system.

## Remodeling

When analyzing the lungs of horses with chronic RAO, it is possible to find evidence of increased mucus production, goblet cell metaplasia, alveolar fibrosis, epithelial damage, plugging of the airway lumen with mucous material and epithelial debris, infiltration of inflammatory cells in the airway, neovascularization, airway wall thickening affecting all tissue layers, and bronchial smooth muscle hypertrophy (Raulo et al., 2000; Leclere et al., 2001; Davies et al., 2003; Léguillette, 2003; Herszberg et al., 2006). The growth of the airway smooth muscle (ASM) in RAO is associated with myocyte hyperplasia and an increase in apoptosis of myocytes as a compensatory mechanism to avoid the increase in ASM mass (Herszberg et al., 2006).

These morphological modifications affect the physical properties of the lungs, damaging the full opening of the bronchioles and altering the elastic properties of the parenchyma, which is why the respiratory functionality of some horses does not return to its normal state after treatment (Léguillette, 2003; Miskovik et al., 2007).

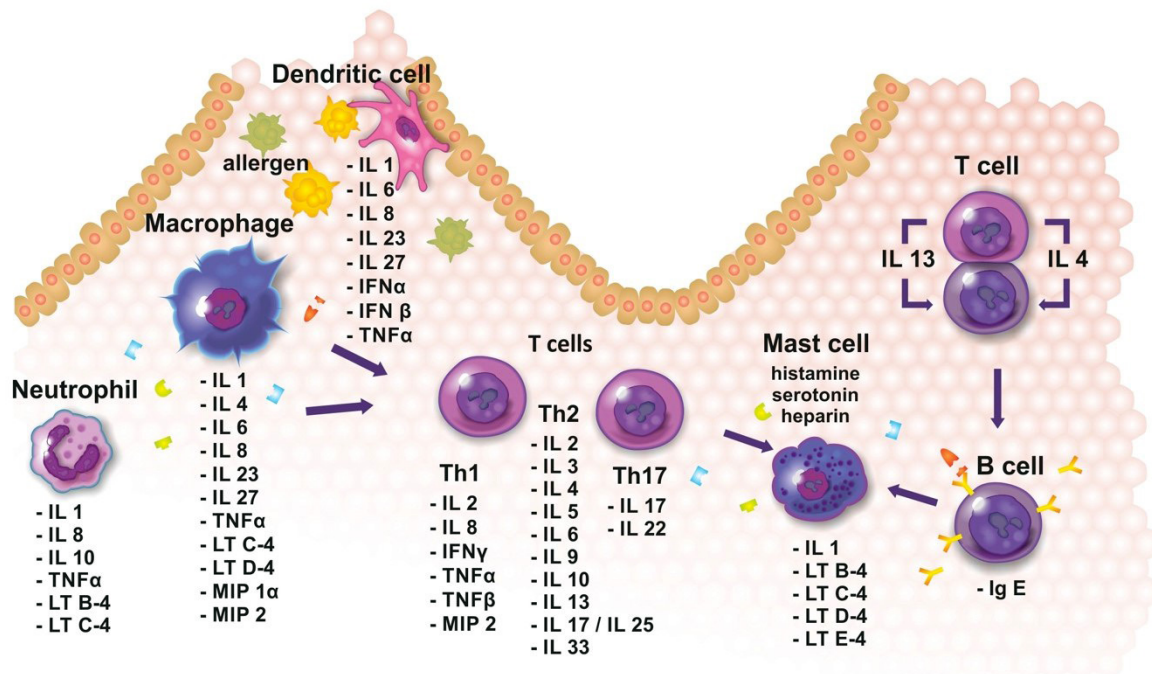
The remodeling only occurs with the perpetuation of the inflammatory process, which leads to an alteration in the cellular profile and

consequent release of chemical mediators, and may cause temporary or permanent changes in the pulmonary epithelium.

## Cells involved in the inflammatory process

Horses have a large bronchoalveolar area - approximately 2000m<sup>2</sup> - that represents not only the major interface between the outside and inside environment but also a large gateway for invaders. Therefore, it requires a large number of cells specialized in phagocytosis and elimination of inhalable particles. Due to their location and particular phenotype, alveolar macrophages (AMs) are the main orchestrators and effectors of particle elimination from the main airways, and their activity is controlled in accordance with airborne particle (Geiser, 2010). AMs play an important role in the inflammatory process of RAO, as they belong to a macrophage phenotype with distinct biological functions and an important pathophysiological role, with the ability to increase or suppress inflammatory responses (Wu et al., 2005). The continuous phagocytosis of inhaled particles activates macrophages and increases the mRNA expression of cytokines that enhance the inflammatory reaction, such as interleukin-1 (IL-1), tumor necrosis factor alpha (TNF- $\alpha$ ), and IL-8 (Figure 1), resulting in the recruitment of neutrophils to the alveolar environment (Franchini et al., 1998; Chung and Barnes, 1999; Laan et al., 2006). Thus, the most consistent cytological finding in the bronchoalveolar lavage fluid (BALF) in horses with RAO is neutrophilia, with neutrophils representing 50%-70% of the total cells present (Rush et al., 1998). This rise in neutrophil number is an indicator of the disease (McGorum and Dixon, 1994). However, this situation occurs predominantly during the clinical exacerbation phase of RAO, while during clinical remission, there is a predominance of lymphocytes (Derksen et al., 1985).

An important new finding is a higher percentage of viable neutrophils in RAO-affected horses compared with healthy horses, suggesting that the neutrophil survival rate is higher at the site of inflammation, as well as an increase in the early and late rate of apoptosis in macrophages, decreasing the number of these cells in the BALF (Niedzwiedz et al., 2014).



**Figure 1** - Cells and chemical mediators present in lung of RAO affected horses, consequently can be present in BALF.

Once in the lungs, neutrophils contribute to bronchoconstriction, mucus hypersecretion, and pulmonary remodeling by the release of proinflammatory mediators such as TNF- $\alpha$ , matrix metalloproteinases, elastase, and reactive oxygen and nitrogen species, which can cause RAO exacerbation due to tissue damage and glandular hypersecretion (Weiss, 1989; Linden et al., 2000). In horses, a potential mechanism involved in this disease could be a disruption of the balance between apoptosis and necrosis of macrophages and neutrophils, as some cytokine can influence macrophage apoptosis, such as increased levels of interferon gamma (IFN- $\gamma$ ) and reduced levels of IL-4, IL-10, and transforming growth factor beta (TGF- $\beta$ ) (Niedzwiedz et al., 2014).

### Chemical mediators

As previously mentioned, RAO is characteristic of adult or elderly horses. Functional changes in T lymphocytes reduce their productivity and activity during the natural aging process. Defects

in proliferative or responsive capacity, cytokine production, receptor expression, and cytotoxicity, as well as problems regarding immunosenescence, limit their functionality and compromise the immune system (Baus et al., 1996; Horohov et al., 2002).

Regarding the immune system, T memory cells can be activated by macrophages and B cells, as well as by dendritic cells, and these cells secrete various cytokines that can influence the type of T helper (Th) cells that are generated, as well as their migratory site after the stimulus (Alberts et al., 2010). When a naive T helper cell is activated, it becomes an effector cell with the potential to differentiate into a Th1, Th2, or, as recently identified, Th17 cell, all of which are capable of assisting in the activation of other cells (Table 1). This is done via cytokine secretion and the expression of costimulatory proteins on their surface (Alberts et al., 2010).

Th17 cells develop when a few cells are activated by the antigen in the presence of TGF- $\beta$  and IL-6 (Alberts et al., 2010). It is believed that IL-17 is one of the first factors to control cytokines in pulmonary diseases. IL-17 induces the release of

other chemical mediators by bronchial epithelial cells, macrophages, and fibroblasts, and increases elastase and myeloperoxidase activity, thus aggravating inflammation (Hoshino et al., 2000; Molet et al., 2001; Debrue et al., 2005). Moreover, this interleukin promotes the maturation, chemotaxis, and activation of neutrophils (Debrue et al., 2005). In mouse models, IL-17 has been shown to induce bronchial hyperreactivity and airway remodeling (Schuijs et al., 2013).

A predominantly Th2 response has been associated with an increase in IL-4, IL-5, and IL-13 and a decrease in IFN- $\gamma$  and IL-2 expression in the BALF of RAO horses (Lavoie et al., 2001; Bowles et al., 2002). However, with the chronicity of inflammatory response in the airways of affected horses, the inversion of the response to Th1 has also been observed (Ainsworth et al. 2003). This discrepancy can be attributed to differences in the clinical stage of the disease or the sampling time.

**Table 1** - Interleukins involved in the inflammatory process in equine recurrent airway obstruction, responsible for a Th1 or Th2 profile, and secreted by cells that participate on the pathophysiology of the disease

Interleukins	Secreted by	Activity	References
IL-1	macrophages, mast cells, endothelial cells, neutrophils	proinflammatory activity; endothelial cell activation; secreted during the acute phase; reduced social behavior; hunger suppression	Alberts et al., 2010; Schuijs et al., 2013
IL-2	Th1, Th2	intracellular signaling; activation of genes that encourage the proliferation and differentiation of effector T cells	Tizard, 1992; Alberts et al., 2010
IL-4	Th2, macrophages	Th2 cell development and maturation; IgE antibody switching; inhibition of IL-1, IL-6, and TNF- $\alpha$ secretion, and Th1 cell development; macrophage deactivation	Tizard, 1992; Lavoie et al., 2001; Bowles, 2002; Jackson et al., 2004; Schuijs et al., 2013
IL-5	Th2	eosinophil tissue migration; stimulation of histamine production by basophils; induction of oxidation	Lavoie et al., 2001; Bowles, 2002; Schuijs et al., 2013
IL-6	macrophages, endothelial cells	anti-inflammatory mechanism; secreted in the acute phase	Laan et al., 2006; Damera et al., 2009
IL-8	Th1, neutrophils, alveolar macrophages	neutrophils and eosinophils attraction ; stimulates respiratory burst and leukotriene secretion	Brooks et al., 2011; Joubert et al., 2011
IL-9	Th2, Th9	found in the BALF; responsible for goblet cell metaplasia and airway hyperresponsiveness	Schuijs et al., 2013
IL-10	Th2, neutrophils	B cell stimulus for antibody production; inhibits Th1 development; macrophage deactivation	Jackson et al., 2004
IL-12	dendritic cells, macrophages	induces Th1 development and macrophage and natural killer cell activation	Tizard, 1992; Alberts et al., 2010
IL-13	Th2	proinflammatory interleukin; immunoglobulin E response; may induce an anaphylactic state; macrophage deactivation	Bowles et al., 2002; Jackson et al., 2004; Schuijs et al., 2013
IL-17	Th17	found in the BALF; first cell involved in neutrophil activation; induces the release of other chemical mediators of lung epithelial cells, bronchial fibroblasts, and macrophages; contributes to the secretion of mucus by stimulating the expression of the mucin gene; controls bronchial hyperreactivity and airway remodeling	Debrue et al., 2005; Schuijs et al., 2013
IL-22	Th17 and a separate Th22 population	Promotes epithelial repair and suppresses the production of pro-inflammatory cytokines	Schuijs et al., 2013
IL-25	Th2	cells; induces the production of IL-9 by Th9	Schuijs et al., 2013
IL-33	Th2	found in lung tissue; induces apoptosis in lung epithelial cells	Schuijs et al., 2013



In their study, Cordeau et al. (2004) assessed the Th1 and Th2 profiles in the BALF of horses with RAO. The results showed that, during the crisis, the Th2 profile is predominant in response to inhaled allergens associated with worsening of airway obstruction. After prolonged exposure to allergens, this response enters a chronic phase characterized by increased IL-8 and IFN- $\gamma$  expression, which is characteristic of the Th1 profile (Horohov et al., 2002).

Other important mediators in equine pulmonary inflammation are the cysteinyl leukotrienes and classes of selectins. Cysteinyl leukotrienes (Table

2) are responsible for inducing a rise in vascular permeability resulting in edema, together with an increase in mucus production and cellular infiltrates within smooth muscle tissue (Menard and Bissonette, 2000). Selectins L, P, and E participate in the endothelial leukocyte activation process and facilitate leukocyte overflow toward the blood vessels. Selectin L is expressed by monocytes, neutrophils, and T and B cells (Kansas, 1996), selectin P is expressed by activated platelets and endothelial cells, and selectin E is also expressed in activated endothelial cells (Hedges et al., 2001).

**Table 2** - Cysteinyl leukotrienes and other chemical mediators secreted by cells that participate on the pathophysiology of the disease, and their role in the inflammatory process of equine recurrent airway obstruction.

Interleukins	Secreted by	Activity	References
IFN- $\gamma$	Th1cells	macrophage and cytotoxic T cell activation; inhibition of Th2 development	Lavoie et al., 2001
LTB-4	Th1cells, mast cells, neutrophils	neutrophil activation; randomic motility	Brooks et al., 2011
LTC-4	mast cell, neutrophil, alveolar macrophages	rise in vascular permeability; bronchoconstriction	Ménard and Bissonet, 2000
LTD-4	mast cells, alveolar macrophages	rise in vascular permeability; bronchoconstriction	Ménard and Bissonet, 2000
LTE-4	mast cells	rise in vascular permeability; smooth muscle contraction	Tizard, 1992
MIP-1 $\alpha$	alveolar macrophages	eosinophils attraction and activation, contributes to the inflammatory process	Ménard and Bissonet, 2000
MIP-2	Th1 cells, alveolar macrophages	neutrophils attraction and activation	Joubert et al., 2011
TNF- $\alpha$	Th1 cells, neutrophils	macrophages, cytotoxic T cells, endothelial cells, and natural killer cells activation	Jackson et al., 2004

## Diagnosis and treatment

Clinical signs in addition to the results of BALF analysis are most commonly used to diagnose the disease (Leclere et al., 2011). BALF analysis is usually carried after endoscopic evaluation, and it enables a differential cell count (Hoffman 2008). An increase in the number of neutrophils is the main diagnostic criterion for RAO in affected animals (Kutasi et al., 2011). Although disorders of the lower airways cannot be differentiated by endoscopy, this diagnostic method is essential, because it enables the evaluation of the trachea and mucus, which may

indicate inflammation of the lower airways (Jackson et al., 2000).

New diagnostic modalities are emerging and changing our understanding of RAO, including the evaluation of BALF cytokine profiles (Figure 1), especially in cases of young animals or those exhibiting the disease for the first time (Miskovic et al., 2007).

Regarding treatment, the use of anti-inflammatory drugs is fundamental. The most commonly applied anti-inflammatory drugs are systemic or inhaled corticosteroids. Inhaled treatments are commonly prescribed for animals with RAO and

include fluticasone and beclomethasone. The most common systemic drugs include dexamethasone and prednisolone (DeLuca et al., 2008; Couëtil et al., 2007). Systemic treatment works faster to control RAO, but the adverse effects associated with its use are higher and include adrenocortical suppression, laminitis, liver disease, muscle loss, change in bone metabolism, and increased susceptibility to infection (Dauvillier et al., 2011). Mucolytic agents and bronchodilators are usually associated with primary treatment (Couëtil et al., 2007).

RAO can be triggered by the inhalation of dust and other airborne particles in the pasture or stable environment (Robinson, 2001; Couëtil et al., 2007). Often, hay is responsible for the appearance of clinical signs of RAO (Bosshard and Gerber, 2014) and together with the bedding, is the main focus of care in the maintenance of a susceptible animal (Jackson et al., 2000; Pirie et al., 2003).

Changes in the environment are essential for RAO control, as they allow for the reduction of allergens and dust and increase ventilation (Jackson et al., 2000). Commonly, hay is removed from the animal's diet and replaced by fresh grass (Jackson et al. 2000), but this is not always possible for various reasons. Therefore, other measures may be taken, such as wetting the hay immediately before serving to prevent inhalable particles (Marinkovic et al., 2007; DeLuca et al., 2008). Even so, animals kept in an environment with low levels of dust can exhibit decreased lung function for 1 to 3 years after therapeutic environmental changes have been applied, so early diagnosis is fundamental to recover respiratory function without persistence of the frame avoiding that there is a pulmonary remodeling process (Miskovic et al., 2007).

## Conclusion

RAO is an inflammatory condition and should be perceived and treated as such. As discussed here, there are many factors involved in the pathogenesis of RAO, and there is a constant flow of information regarding the mechanisms involved as well as the diagnosis and treatment, which has generated an increasing amount of knowledge of this common disease of horses. The release of new information

is of great importance to the field as well as the professionals involved.

## References

- Aharonson-Raz K, Lohmann KL, Townsend HG, Marques F, Singh B. Pulmonary intravascular macrophages as proinflammatory cells in heaves, an asthma-like equine disease. *Am J Physiol Lung Cell Mol Physiol.* 2012;303(3):L189-98.
- Ainsworth DM, Grünig G, Matychak MB, Young J, Wagner B, Erb HN, et al. Recurrent airway obstruction (RAO) in horses is characterized by IFN- $\gamma$  and IL-8 production in bronchoalveolar lavage cells. *Vet Immunol Immunopathol.* 2003;96(1-2):83-91.
- Alberts B, Johnson A, Lewis J, Raff M, Roberts K, Walter P. *Molecular and Cellular Biology.* 5th ed. Porto Alegre: Artmed; 2010.
- Baus E, Andris F, Dubois PM, Urbain J, Leo O. Dexamethasone inhibits the early steps of antigen receptor signaling in activated T lymphocytes. *J Immunol.* 1996;156(12):4555-61.
- Bosshard S, Gerber V. Evaluation of coughing and nasal discharge as early indicators for an increased risk to develop equine recurrent airway obstruction (RAO). *J Vet Intern Med.* 2014;28(2):618-23.
- Bowles KS, Beadle RE, Mouch S, Pourciau SS, Littlefield-Chabaud MA, Le Blanc C, et al. A novel model for equine recurrent airway obstruction. *Vet Immunol Immunopathol.* 2002;87(3-4):385-9.
- Brooks AC, Rickards KJ, Cunningham FM. CXCL8 attenuates chemoattractant-induced equine neutrophil migration. *Vet Immunol Immunopathol.* 2011;139(2-4):141-7.
- Carlton WW, McGavin MD. *Patologia Veterinária Especial de Thomson.* 2nd ed. Porto Alegre: Artmed; 1998.
- Chung KF, Barnes PJ. Cytokines in asthma. *Thorax.* 1999;54(9):825-57.
- Cordeau ME, Joubert P, Dewachi O, Hamid Q, Lavoie JP.

- IL-4, IL-5 and IFN- $\gamma$  mRNA expression in pulmonary lymphocytes in equine heaves. *Vet Immunol Immunopathol.* 2004;97(1-2):87-96.
- Couëtil LL, Hoffman AM, Hodgson J, Buechner-Maxwell V, Viel L, Wood JL, et al. Inflammatory airway disease of horses. *ACVIM Consensus Statement. J Vet Intern Med.* 2007;21:356-61.
- Damera G, Tliba O, Panettieri Jr RA. Airway smooth muscle as an immunomodulatory cell. *Pulm Pharmacol Ther.* 2009;22(5):353-9.
- Debrue M, Hamilton E, Joubert P, Lajoie-Kadoch S, Lavoie JP. Chronic exacerbation of equine heaves is associated with an increased expression of interleukin-17 mRNA in bronchoalveolar lavage cells. *Vet Immunol Immunopathol.* 2005;105(1-2):25-31.
- DeLuca L, Erb HN, Young JC, Perkins GA, Ainsworth DM. The effect of adding oral dexamethasone to feed alterations on the airway cell inflammatory gene expression in stable horses affected with recurrent airway obstruction. *J Vet Intern Med.* 2008;22(2):427-35.
- Derksen FJ, Scott JS, Miller DC, Slocombe RF, Robinson NE. Bronchoalveolar lavage in ponies with recurrent airway obstruction (Heaves). *Am Rev Respir Dis.* 1985;132(5):1066-70.
- Franchini M, Gilli U, Akens MK, Fellenberg RV, Bracher V. The role of neutrophil chemotactic cytokines in the pathogenesis of equine chronic obstructive pulmonary disease (COPD). *Vet Immunol Immunopathol.* 1998;66(1):53-65.
- Geiser M. Update on macrophage clearance of inhaled micro- and nanoparticles. *J Aerosol Med Pulm Drug Deliv.* 2010;23(4):207-17.
- Hedges JF, Demaula CD, Moore BD, Mclaughlin BE, Simon SI, Maclachlan NJ. Characterization of equine E-selectin. *Immunology.* 2001;103(4):498-504.
- Herszberg B, Ramos-Barbón D, Tamaoka M, Martin JG, Lavoie JP. Heaves, an asthma-like equine disease, involves airway smooth muscle remodeling. *J Allergy Clin Immunol.* 2006;118(2):382-8
- Horohov DW, Kydd JH, Hannant D. The effect of aging on T cell responses in the horse. *Dev Comp Immunol.* 2002;26(1):121-8.
- Hoshino H, Laan M, Sjostrand M, Lötvall J, Skoogh BE, Lindén A. Increased elastase and myeloperoxidase activity associated with neutrophil recruitment by IL-17 in airways in vivo. *J Allergy Clin Immunol.* 2000;105(1 Pt 1):143-9.
- Jackson CA, Berney C, Jefcoat AM, Robinson NE. Environment and prednisone interactions in the treatment of recurrent airway obstruction (heaves). *Equine Vet J.* 2000;32(5):432-8.
- Jackson KA, Stott JL, Horohov DW, Watson JL. IL-4 induced CD23 (Fc $\epsilon$ R2) up-regulation in equine peripheral blood mononuclear cells and pulmonary alveolar macrophages. *Vet Immunol Immunopathol.* 2004;101(3-4):243-50.
- Joubert P, Cordeau ME, Lavoie JP. Cytokine mRNA expression of pulmonary macrophages varies with challenge but not with disease state in horses with heaves or in controls. *Vet Immunol Immunopathol.* 2011;142(3-4):236-42.
- Kansas GF. Selectins and their ligands: current concepts and controversies. *Blood.* 1996;88(9):3259-87.
- Kutasi O, Balogh N, Lajos Z, Nagy K, Szenci O. Diagnostic approaches for the assessment of equine chronic pulmonary disorders. *J Equine Vet Sci.* 2011; 31(7):400-10.
- Laan TJM, Bull S, Pirie R, Fink-Gremmels J. The role of alveolar macrophages in the pathogenesis of recurrent airway obstruction in horses. *J Vet Intern Med.* 2006;20(1):167-74.
- Lavoie JP, Maghni K, Desnoyers M, Taha R, Martin JG, Hamid QA. Neutrophilic airway inflammation in horses with heaves is characterized by a Th2-type cytokine profile. *Am J Respir Crit Care Med.* 2001;164(8 Pt 1):1410-3.
- Lavoie JP, Dalle S, Breton L, Hélie P. Bronchiectasis in three adult horses with heaves. *J Vet Intern Med.* 2004;18(5):757-60.
- Leclere M, Lavoie A, Gélinas E, David F, Martin JG, Lavoie JP. Effect of antigenic exposure on airway smooth muscle



- remodeling in an equine model of chronic asthma. *Am J Respir Cell Mol Biol.* 2011;45(1):181-7.
- Leclere M, Lavoie-Lamoureux A, Lavoie JP. Heaves, an asthma-like disease of horses. *Respirology.* 2011;16(7):1027-46.
- Léguillette R. Recurrent airway obstruction: heaves. *Vet Clin North Am Equine Pract.* 2003;19(1):63-86.
- Lindén A, Hoshino H, Lann M. Airway neutrophils and interleukin-17. *Eur Respir J.* 2000;15(5):973-7.
- Marinkovic D, Aleksic-Kovacevic S, Plamenac P. Cellular basis of chronic obstructive pulmonary disease in horses. *Int Rev Cytol.* 2007;257:213-47.
- McGorum BC, Dixon PM. The analysis and interpretation of equine bronchoalveolar lavage fluid (BALF) cytology. *Equine Vet Educ.* 1994;6(4):203-9.
- McPherson EA, Lawson GHK. Some aspects of chronic pulmonary diseases of horses and methods used in their investigation. *Equine Vet J.* 1974;6(1):1-6.
- Ménard G, Bissonnette EY. Priming of alveolar macrophages by leukotriene D<sub>4</sub>: potentiation of inflammation. *Am J Respir Cell Mol Biol.* 2000;23(4):572-7.
- Miskovic M, Couëtill LL, Thompson CA. Lung function and airway cytologic profiles in horses with recurrent airway obstruction maintained in low-dust environments. *J Vet Intern Med.* 2007;21(5):1060-6.
- Molet S, Hamid Q, Davoineb F, Nutku E, Tahaa R, Pagé N, et al. IL-17 is increased in asthmatic airways and induces human bronchial fibroblasts to produce cytokines. *J Allergy Clin Immunol.* 2001;108(3):430-8.
- Moore JE, Matsuda M, Yamamoto S, Yamamoto S, Buckley T, Millar BC. Hypersensitivity pneumonitis in the horse: an underdiagnosed condition? *J Equine Vet Sci.* 2004;24(12):510-1.
- Nelson HS, Davies DE, Wicks J, Powell RM, Puddicombe SM, Holgate ST. Airway remodeling in asthma: new insights. *J Allergy Clin Immunol.* 2003;111(2):215-25.
- Niedzwiedz A, Jaworski Z, Tykalowski B, Smialek M. Neutrophil and macrophage apoptosis in bronchoalveolar lavage fluid from healthy horses and horses with recurrent airway obstruction (RAO). *BMC Vet Res.* 2014;10:29.
- Olszewski MA, Robinson NE, Zhu FX, Zhang XY, Tithof PK. Mediators of anaphylaxis but not activated neutrophils augment cholinergic responses of equine small airways. *Am J Physiol.* 1999; 276(3 Pt 1):L522-9.
- Pirie RS, Collie DD, Dixon PM, McGorum BC. Inhaled endotoxin and organic dust particulates have synergistic proinflammatory effects in equine heaves (organic dust-induced asthma). *Clin Exp Allergy.* 2003;33(5):676-83.
- Raulo SM, Sorsa TA, Maisi PS. Concentrations of elastolytic metalloproteinases in respiratory tract secretions of healthy horses and horses with chronic obstructive pulmonary disease. *Am J Vet Res.* 2000;61(9):1067-73.
- Robinson NE. Recurrent airway obstruction (heaves). In: Lekeux P (Ed). *Equine Respiratory Diseases*. Ithaca, NY: International Veterinary Information Service; 2001.
- Robinson NE, Jackson C, Jefcoat A, Berney C, Peroni D, Derksen FJ. Efficacy of three corticosteroids for the treatment of heaves. *Equine Vet J.* 2002;34(1):17-22.
- Rush BR, Flaminio MJ, Matson CJ, Hakala JE, Shuman W. Cytologic evaluation of bronchoalveolar lavage fluid from horses with recurrent airway obstruction after aerosol and parenteral administration of beclomethasone dipropionate and dexamethasone, respectively. *Am J Vet Res.* 1998;59(8):1033-8.
- Schuijs MJ, Willart MA, Hammad H, Lambrecht BN. Cytokine targets in airway inflammation. *Curr Opin Pharmacol.* 2013;13(3):351-61.
- Seahorn TL, Beadle RE. Summer pasture-associated obstructive pulmonary disease in horses: 21 cases (1983-1991). *J Am Vet Med Assoc.* 1993;202(5):779-82.
- Tizard IR. *Veterinary immunology: an introduction*. 4th ed. Philadelphia: W.B. Saunders; 1992.
- Tilley P, Luis JPS, Ferreira MB. Correlation and discriminant analysis between clinical, endoscopic, thoracic X-ray and

bronchoalveolar lavage fluid cytology scores, for staging horses with recurrent airway obstruction (RAO). *Res Vet Sci.* 2012;93(2):1006-14.

Venugopal C, Mariappan N, Holmes E, Kearney M, Beadle R. Effect of potential therapeutic agents in reducing oxidative stress in pulmonary tissues of recurrent airway obstruction-affected and clinically healthy horses. *Equine Vet J.* 2013;45(1):80-4.

Weiss SJ. Tissue destruction by neutrophils. *N Engl J Med.* 1989;320(6):365-76.

Westergren EV, Franklin SH, Bayly AM. Respiratory diseases and their effects on respiratory function and exercise capacity. *Equine Vet J.* 2013;45(3):376-87.

Wu HM, Jin M, Marsh CB. Toward functional proteomics of alveolar macrophages. *Am J Physiol Lung Cell Mol Physiol.* 2005;288(4):L585-95.

Received in: 12/09/2016

*Recebido em: 09/12/2016*

Approved in: 05/11/2017

*Aprovado em: 11/05/2017*