

# Radiographic assessment of proximal sesamoid bones in suckling and yearling Thoroughbred horses and its correlation to racing performance

*Avaliação radiográfica de ossos sesamoides proximais de cavalos de corrida Puro-Sangue Inglês nas fases lactante e sobreano e sua correlação com o desempenho desportivo*

Amarildo Dubiella <sup>1\*</sup>

Luis Fernando Coelho Bastos <sup>2</sup>

Fabiane Cassou<sup>3</sup>

Pollyanna Romeiro <sup>4</sup>

Pedro Vicente Michelotto Jr <sup>5</sup>

are to radiographically assess proximal sesamoid bones in Thoroughbred horses at suckling and yearling stages, in Curitiba, Paraná, Brazil, as well as to investigate the influence of radiographic changes in these bones on animals' sporting performance. In total, 86 animals were investigated at suckling and yearling stages, in 2012, based on the following radiographic projections: back 15° proximal-palmarodistal oblique, lateromedial, back 30° medial-palmaro/plantarolateral oblique and back 30° lateral-palmarolateral/plantarolateral oblique. Radiographic changes observed in animals' sesamoid bones were scored from 0 to 4. The number of races and horses' performance were classified based on a previously proposed score, by taking into consideration the official results of races held at hippodromes, which were obtained at the end of the study. Healthy horses without bone-related changes were attributed scores 0 and 1, whereas horses presenting bone-related changes were attributed scores 2, 3 and 4. Statistical analysis was based on Wilcoxon and Mann-Whitney tests, at 5% significance level ( $p < 0.05$ ). Radiographic changes were identified in 3.6% of 688 sesamoid bones analyzed at suckling stage and in 3.7% of bones analyzed at yearling stage. There was significant increase in the number of lateral sesamoid bones with abnormalities in animals' thoracic and pelvic limbs, from the suckling to the yearling stage. The current findings have evidenced that radiographic changes in proximal sesamoid bones of Thoroughbred racehorses take place at suckling stage and that changes observed at yearling stage did not affect the number of races or animals' performance.

**Keywords:** Diagnostic imaging. Horses. Musculoskeletal system. Radiography.

<sup>1</sup> Faculdade Evangélica do Paraná Curitiba, PR, Brazil

<sup>2</sup> Universidade Federal do Rio Grande do Sul (UFRGS), Porto Alegre, RS, Brazil

<sup>3</sup> Universidade Federal do Paraná (UFPR), Curitiba, PR, Brazil

<sup>4</sup> Universidade Tuiuti do Paraná (UTP) Curitiba, PR, Brazil

<sup>5</sup> Pontifícia Universidade Católica do Paraná (PUCPR) Curitiba, PR, Brazil

**\*Correspondence:** dubiellasaudeanimal@gmail.com

**Received:** 2023 Dec 14 | **Accepted:** 2024 Jun 15

DOI: <http://dx.doi.org/10.7213/acad.2024.22005>

Rev. Acad. Ciênc. Anim. 2024;22:e22005

## Abstract

Radiographic abnormalities are often observed in athletic horses and they can interfere with the performance of racehorses. The origin of changes in sesamoid bones, as well as their evolution or involution during animal growth, remain unknown. The aims of the present study

## Resumo

*Alterações radiográficas são frequentes em cavalos atletas, podendo interferir no rendimento de cavalos de corrida. Não se sabe a origem das alterações dos ossos sesamoides e a evolução ou involução das mesmas durante o crescimento. O presente estudo teve como objetivo investigar a correlação entre o desempenho atlético e as alterações radiográficas nos ossos sesamoides proximais de cavalos Puro-Sangue Inglês com um ano de idade e lactantes. Oitenta e seis animais foram investigados na cidade de Curitiba, Paraná, Brasil, em 2012. Radiografias dos ossos sesamoides proximais dos membros torácicos e posteriores foram realizadas com base na técnica padrão. Os achados radiográficos foram pontuados de 0 a 4; as notas 0 e 1 corresponderam aos animais sem alterações ósseas, enquanto as notas 2, 3 e 4 corresponderam aos animais com alterações ósseas. O número de corridas e o desempenho nas corridas foram baseados em pontuações previamente estabelecidas que, por sua vez, foram baseadas em resultados oficiais registrados em corridas realizadas no Jockey Club - resultados considerados ao final do presente estudo. A análise estatística foi realizada com base nos testes de Wilcoxon e Mann-Whitney; o nível de significância foi fixado em  $p < 0,05$ . Alterações radiográficas foram observadas em 3,6% dos equinos lactentes e em 3,7% dos equinos com um ano de idade - foram investigados 688 ossos sesamoides, no total. Houve aumento significativo no número de ossos sesamoides laterais alterados nos membros torácicos e pélvicos dos animais, desde a fase de lactação até o ano de sobreano ( $p < 0,05$ ). Alterações radiográficas foram observadas nos ossos sesamoides proximais de cavalos Puro-Sangue Inglês com um ano de idade, embora tenham começado na fase de amamentação; além disso, essas mudanças não afetaram o número de corridas em que os cavalos participaram ou seu desempenho nas corridas.*

**Palavras-chave:** *Diagnóstico por imagem. Cavalos. Sistema musculoesquelético. Radiografia.*

## Introduction

Changes in proximal sesamoid bones, which are often observed in racehorses, were first described by Brauell, in 1845 (Cornelissen et al., 2002).

They are often referred to as sesamoiditis, which is a degenerative process affecting proximal sesamoid bones and their surrounding areas. This process can be associated with injuries in the suspensory ligament branch. Plevin et al. (2016) have found association between changes in proximal sesamoid bones, as well as inflammation followed by fibrous tissue formation in suspensory ligaments.

According to a study carried out in Japan, in 2016, the prevalence of changes observed in proximal sesamoid bones reached 5.4% in thoracic limbs and 3.3% in pelvic limbs (Miyakoshi et al., 2016). Menarim et al. (2012) stated that 70% of animals analyzed in their study have shown radiographic signs of proximal sesamoiditis.

The metacarpophalangeal joint (MCP) is the main region affected by changes in racehorses. In total, 34% of causes for animals' lower performance and irreversible injuries are associated with proximal sesamoid bones and fetlock suspensory ligament (Peloso et al., 2015).

In addition, changes in proximal sesamoid bones may lead to fractures often associated with MCP and metatarsophalangeal (MTP) joint impacts and hyperextension during races (Wang et al., 2012; Hill et al., 2016), a fact that result in irreparable damages (Gaschen and Burba, 2012). Proximal sesamoid bone fractures are the main cause of accidents during races. They mostly affect animals' thoracic limbs (Johnson et al., 1994; Hill et al., 2016) and are the major cause of injuries associated with racing accidents in California (Stover, 2003; Anthenill et al., 2006), Kentucky (Peloso et al., 1994), Florida (Hernandez et al., 2001) and Hong Kong (Hernandez et al., 2001).

Increased vascular channels, and variations in their size, shape and contour observed in X-ray are changes pointing towards the risk of injury in racehorses (Butler et al., 2008). Irregular vascular channels wider than 2 mm cause lower racing performance, as observed in the studies by Spike-Pierce and Bramlage (2003) and Plevin et al. (2016).

Horse races generate millions of dollars worldwide. More than R\$140 million were moved in horse bets in Brazil, in 2007, alone (approximately 42 million dollars). The aliquot of 1.5% of this total went to the government (Lima et al., 2006).

The economic impact of musculoskeletal diseases and the small number of specific studies conducted in Brazil highlight the relevance of the present

study, whose aim was to evaluate the incidence of radiographic changes in proximal sesamoid bones of suckling and yearling Thoroughbred racehorses in Curitiba City, Paraná State, Brazil. The current hypothesis advocates that radiographic changes in proximal sesamoid bones take place at both stages and that they can affect animals' athletic performance.

## Material and methods

### Study type

Observational and prospective study correlating proximal sesamoid radiographic findings observed in suckling and yearling Thoroughbred horses and their influence on animals' athletic performance.

### Animals

Eighty-six Thoroughbred horses - 40 males (46.5%) and 46 females (53.5%), at suckling (from 4 to 6 months old) and yearling (from 15 to 18 months old) stages, from four different properties in the metropolitan region of Curitiba City, were assessed in the current study. Suckling animals were assessed from October to December 2012 and reassessed at the yearling stage, from October to December 2013. The investigated animals represented 13.8% of Thoroughbred racehorses born in Paraná State, in 2012. All of them were born in the properties they came from.

All analyzed properties adopted similar quality of nutritional and health program management procedures. Suckling animals remained in pickets with mares. They fed on two feed types comprising

concentrated food, tifton and alfalfa. All animals had access to water *ad libitum*. Yearling animals were similarly managed, although mares were not in their pickets.

All animals were subjected to physical examination. Static examination was performed to identify any change in the fetlock region (swelling, pain, heat), whereas dynamic examination (hard floor) was performed to assess lameness. Both exams were performed by two expert veterinarians.

The current study was approved by the Ethics Committee of Pontifical Catholic University of Paraná (PUCPR), under protocol n. 0766-2015.

### Radiographic assessment

Radiographic images of MCP and MTP joints were taken in Eklín digital x-ray equipment (Mark III model, Carlsbad, California, USA). The used software (E film) was associated with a Minxray x-ray emitter, model TR90 (Illinois, USA).

Weight was applied to the animals' assessed limb. They were physically restrained with the aid of a halter. Full radiographic examination of each joint comprised five projections: lateromedial, 15° proximal-palmarodistal oblique, 30° dorsomedial-palmaro/plantarolateral oblique, and 30° dorsolateral-palmaro/plantarolateraloblique (Furniss et al., 2011).

Expert veterinarians assessed the radiographic images based on scores set by Spike-Pierce and Bramlage (2003), with modifications (Table 1). Animals who did not show changes in proximal sesamoid bones recorded scored 0 and 1, whereas animals presenting these changes scored 2, 3 and 4. From now on, these animals will be referred to as without, or with, changes.

**Table 1** - Score of changes observed in horses' proximal sesamoid bones

Score	Description
0	No defects, or up to three linear defects, in the vascular canals (< 2mm in width)
1	One or two linear defects in the vascular canals (> 2mm in width)
2	More than three linear defects (> 2mm in width) or irregular linear defects (> than 2mm in width)
3	Presence of irregular radiolucent image at the bone's abaxial border
4	Contour irregularities due to bone proliferation

Note: Adapted from Spike-Pierce and Bramlage (2003).

### Athletic performance evaluation

The number of races the animals participated in and their athletic performance were herein assessed. Animals had already finished the training time and they were considered 3-year-old racehorses. Data were collected at the official website of the Brazilian Association of Racehorse Breeders and Owners (ABCPCC, 2016).

Animals who had participated in races until the end of the present study were assessed, whereas animals lacking race information at the same time

period were excluded from it. Scores were given to each placement at different racing graduations, according to different racetracks. Thus, a scoring aimed at leveling performance based on the world classification was adopted. In descending order of importance, one has races ran by groups I, II and III, Listed Race, Classic/Grand Prix/Special Weights and Common Race. The positions recorded for the horses was scored according to the score used in world F1 championships. It was adjusted to the different horse race degrees, according to Michelotto Jr et al. (2012), as shown in Table 2.

**Table 2** - Scores given to animals' rank in different races, as well as to animals' performance level in races held in different racecourses, according to Michelotto Jr et al. (2012)

Position	Group I	Group II	Group III	LC	CCSW	Common race
1st	10	8	6	5	4	3
2nd	8	6	5	4	3	2
3rd	6	5	4	3	2	1
4th	5	4	2	1	0	0
5th	4	3	2	1	0	0

Note: LC = listed competition; CCSW = classic competition and special weight.

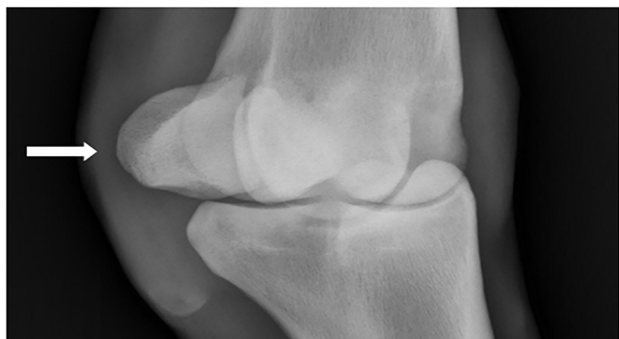### Statistical analysis

Descriptive analysis applied to changes observed in sesamoid bones was performed at two investigated stages (suckling and yearling). Quantitative analysis was based on the D'Agostino and Pearson test. The number of affected sesamoid bones and that of races horses have participated in were considered non-parametric data. Comparisons between the number of affected sesamoid bones and animals' sex; the number of affected sesamoid bones in animals' forelimbs or hindlimbs; and the number of races and athletic performance between animals with, and without, changes were performed through Mann-Whitney test. Wilcoxon test was used to compare the presence or absence of radiographic changes in the sesamoid bones of suckling and yearling horses. All analyses were performed in GraphPad Prism software, version 5.0 for Windows (San Diego, CA, USA); significant values were set at  $p < 0.05$ .

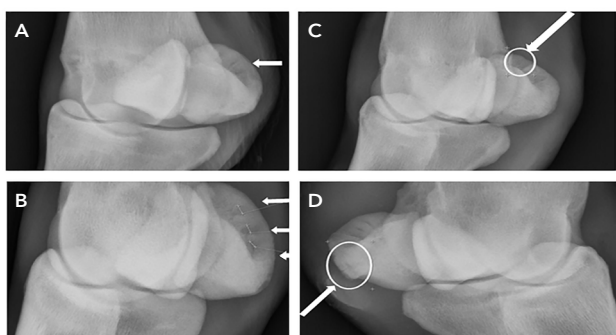
### Results

The investigated animals did not show lameness or increased fetlock. Regarding the radiographic assessment, 688 sesamoid bone images were assessed in the current study: 172 lateral (LS) and 172 medial sesamoid bones (MS) from animals' thoracic (TL) and pelvic limbs (PL), at each assessed stage. Animals scoring 0 and 1 points were considered to do not have changes in proximal sesamoid bones, whereas animals scoring 2, 3 and 4 points were classified as having these changes, as presented in Figures 1 and 2.

In addition, 36 (53.7%) female and 31 (46.3%) male horses at the suckling stage did not present radiographic changes. They accounted for 77.9% ( $n = 67$ ) of all assessed animals. However, 19 (22.1%) animals - 10 (52.6%) females and 9 (47.4%) males - presented changes in at least one of the proximal sesamoid bones.



**Figure 1** - Radiographic image of a Thoroughbred racehorse's fetlock joint without changes in the lateral sesamoid bone (arrow) (score 0).



**Figure 2** - Radiographic image of Thoroughbred racehorse's fetlock joint.

Note: (A) Two linear defects in vascular channels up to 2-mm in width (arrow) - score 1. (B) Three linear defects wider than 2 mm in vascular channels (arrows) - score 2. (C) Radiolucent area on the abaxial border of the sesamoid bone (circle) - score 3. (D) Irregular sesamoid bone edge due to bone proliferation (circle) - score 4.

Twenty-four (24) of the 688 assessed proximal sesamoid bones presented radiographic changes at suckling stage. Fifteen (8.7%) sesamoid bones presented changes in the forelimb: 7, in the right forelimb; 7, in the medial sesamoid bone; and 1, in the lateral sesamoid bone. Changes were observed in 8 (9.3%) left forelimbs, 6 MS and 2 LS. They were also observed in 9 (5.2%) sesamoid bones in the pelvic limb; 6 (7.0%) of them in the right PL (3 in LS bones and 3 in MS bones). Radiographic changes identified in the left PL were observed in SL (n = 2) and MS (n = 1) bones.

Sixty-four (74.0%) yearling animals - 37 (57.8%) females and 27 (42.2%) males - did not show changes in sesamoid bones. Nevertheless, 26 (3.7%) of the 688 sesamoid bones assessed in the current study presented radiographic changes. Twenty-two animals - nine (40.9%) females and thirteen (59.1%) males - pre-sented changes in at least one sesamoid bone.

Sixteen (9.3%) animals have shown changes in the forelimb; ten (5.8%), in the right TL (three in LS and eight in MS); and six (3.5%), in the left TL (four in LS and two in MS). Radiographic changes in hindlimbs were found in nine (5.2%) animals; five (2.9%) of them in the right PL (four in LS and one in MS). Three (1.7%) left PL bones presented radiographic changes (three in LS and none in MS).

There was significant increase in the number of lateral sesamoid bones with abnormalities in MT ( $p = 0.009$ ) and MP ( $p = 0.019$ ) in yearling animals in comparison to that of suckling animals, as presented in Table 3.

**Table 3** - Proximal sesamoid bones presenting, or not, changes in evaluations performed in suckling and yearling Thoroughbred horses

	Thoracic limb				Pelvic limb			
	LS suckling	LS yearling	MS suckling	MS yearling	LS suckling	LS yearling	MS suckling	MS yearling
NR	169 (98.3)	165 (95.9)	159 (92.4)	162 (94.2)	167 (97.1)	165 (95.9)	168 (97.7)	170 (98.8)
AR	3 (1.7)	7 (4.1)*	13 (7.6)	10 (5.8)	5 (2.9)	7 (4.1)**	4 (2.3)	2 (1.2)

Note: Data presented as number (percentage). LS = lateral sesamoid (n = 172); MS = medial sesamoid (n = 172); NR = normal radiography; AR = abnormal radiography. \* $p = 0.009$ ; \*\* $p = 0.019$ .

## Athletic performance

Radiographic changes observed at the yearling stage were taken into consideration at the time to assess the influence of changes in sesamoid bones on animals' performance.

Sixty of the 86 assessed animals - 29 (48.3%) females and 31 (51.7%) males - participated in races

in Brazilian racetracks. Results recorded for number of races and the score are described in Table 4. The number of races and scores did not show significant difference between sexes, and between the presence or absence of radiographic changes. Four of the 26 horses who did not participate in races presented changes in sesamoid bones, whereas 22 did not.

**Table 4** - Median, minimum, maximum, first and third quartiles recorded for the number of (No.) races horses have participated in and scores attributed to Thoroughbred horses with, and without, changes in proximal sesamoid bones

	Female				Male			
	NR (n = 22)		AR (n = 7)		NR (n = 21)		AR (n = 10)	
	No. races	Score	No. races	Score	No. races	Score	No. races	Score
Median	5.50	3.00	5.00	4.00	5.00	5.00	3.50	3.00
Minimum	1.00	0.00	2.00	0.00	2.00	0.00	1.00	0.00
Maximum	16.00	35.00	14.00	13.00	10.00	20.00	10.00	37.00
1st quartile	2.00	0.00	3.00	3.00	4.00	0.00	2.00	4.00
3rd quartile	7.75	12.00	8.00	9.00	7.50	9.00	6.50	7.50

Note: NR = normal radiography; AR = abnormal radiography.

## Discussion

The number of changes in sesamoid bones observed at each stage (suckling and yearling) did not influence animals' athletic performance in races. However, changes in vascular canals of proximal sesamoid bones are radiographic findings often observed in Thoroughbred horses (Spike-Pierce and Bramlage, 2003).

The current study has assessed changes in proximal sesamoid bones of suckling horses. However, it was not possible comparing the current findings to other studies available in the literature due to lack of investigations about changes taking place at this specific life stage. The literature in this field only presents reports about findings in sesamoid bones of young horses at the beginning of the training time (Kane et al., 2003; Spike-Pierce and Bramlage, 2003; Meagher et al., 2013; Miyakoshi et al., 2016; Plevin et al., 2016).

Radiographic studies focused on assessing proximal sesamoid bones in suckling animals are rare. However, it was interesting observing the incidence of these changes in such young foals (suckling

stage). In addition, the risk factors for the herein observed changes were not investigated in the current research. Thus, further studies focused on investigating these factors should be conducted to help better understanding their incidence, as well as to confirm whether radiographic examinations of proximal sesamoid bones in suckling horses can help improving the care provided to these animals based on the early identification of changes in the herein assessed bones.

Data about yearling horses in the current study differed from those in most reports, since the aim of the present study was to investigate the total population of animals born in 2012, whereas studies available in the literature often report radiographic changes in animals selected for sale, at major auctions in the USA (Kane et al., 2003; Spike-Pierce and Bramlage, 2003; Meagher et al., 2013; Miyakoshi et al., 2016; Plevin et al., 2016). Therefore, the current study presents results recorded for an entire population, whereas other studies often present results recorded for previously selected populations.

The herein recorded rate of affected animals (26%) was higher than the one recorded Spike-Pierce

and Bramlage (2003), who assessed radiographic images of 487 young Thoroughbred horses selected for auctions in the USA. They only found changes in 17.7% of the assessed horses.

Results in studies focused on investigating young horses at the training stage differed from each other. Meagher et al. (2013) have assessed 853 animals at the training stage and they found that 35% of them were affected by bone changes. Miyakoshi et al. (2016) have found 5.4% changes in thoracic limbs and 3.3% in pelvic limbs of 850 Thoroughbred horses at the beginning of their training stage, in Japan. Plevin et al. (2016) have assessed animals at the first training stage in a horse-training center in Florida (USA). In addition, they found that 66% of them presented radiographic changes. Thus, radiographic changes may be associated with the assessed population or region. However, the influence of training on these changes remains unknown.

Radiographic changes in proximal sesamoid bones are often referred to as sesamoiditis. According to Plevin et al. (2016), sesamoiditis is a common radiological finding observed in young Thoroughbred horses and it can reduce their athletic performance. Nevertheless, most radiographic findings observed in Thoroughbred horses at the beginning of the training stage (two-to-three-year-old animals) did not affect their athletic performance (Miyakoshi et al., 2016). According to Peloso et al. (2015), increase in sesamoid bones (in the apical, abaxial or basilar regions) was the only variable correlated to lower animal performance in races. This change type was not herein observed.

Although the term "sesamoiditis" refers to an inflammatory process, its pathological features remain poorly understood (Richardson and Dyson, 2011). Consequently, the aforementioned term should be used with caution when animals do not show clinical manifestations of it (Richardson and Dyson, 2011). Horses' clinical assessment should include digital pressure on the abaxial region of sesamoid bones or fetlock flexion (Richardson and Dyson, 2011).

Other differences among studies lies on image interpretation form, on changes in and identification of vascular size, as well as on radiolucency findings leading to inconsistent analyses among observers, as previously reported by Jackson et al. (2014). Although different software types were used to assess the digital images, some of the herein observed changes were at borderline situations between assessment

scores. Kane et al. (2003) have assessed radiographs of Thoroughbred horses selected for auctions in USA and they found irregular vascular canals in sesamoid bones in 79% of them. However, it is worth mentioning that they used conventional radiography, which provides lesser digital examination possibilities and resources.

The hypothesis of the current study was partly confirmed, since the observed changes did not affect animals' athletic performance. Although significant changes can reduce the likelihood of having two-year-old horses participating in races (Spike-Pierce and Bramlage, 2003; Meagher et al., 2013; Miyakoshi et al., 2016), it was not possible having this information in the current study because the 26 horses presenting radiographic changes did not participate in the aforementioned races. In addition, few horses among the ones who did not run presented radiographic changes. The small number of assessed animals can be a limitation of this observation type. According to Preston et al. (2012), 48% of the 192 assessed horses ran at least once at the age of 2 years. Nevertheless, the presence of osteophytes or enthesophytes in sesamoid bones, which corresponded to score 4 in the present study, represented 1.78 times more likelihood of not having the horses racing in comparison to animals who did not present these findings.

In addition, Plevin and McLellan (2014) and Plevin et al. (2016) have found association between sesamoiditis and previously identified suspensory ligament branch disorder, which was not assessed in the present study. However, they should be investigated whenever major changes in sesamoid bones are observed.

## Conclusion

Finally, radiographic changes in proximal sesamoid bones were observed in suckling and yearling Thoroughbred racehorses, although with no evidence of their interference on animals' athletic performance.

## Acknowledgement

The authors are grateful to PUCPR and to Coordination for the Improvement of Higher Education Personnel (CAPES), Brazil.

## References

- ABCPC - Associação Brasileira de Criadores e Proprietários do Cavalo de Corrida. Estatística Nacional. 2016 [cited 2024 Jun 17]. Available from: <http://www.abcpc.com.br>
- Anthenill LA, Stover SM, Gardner IA, Hill AE, Lee CM, Anderson ML, et al. Association between findings on palmarodorsal radiographic images and detection of a fracture in the proximal sesamoid bones of forelimbs obtained from cadavers of racing Thoroughbreds. *Am J Vet Res.* 2006;67(5):858-68.
- Butler JA, Colles CM, Dyson SJ, Kold SE, Poulos PW. *Clinical Radiology of the Horse.* Oxford: Wiley-Blackwell; 2007.
- Cornelissen BP, Rijkenhuizen AB, Buma P, Barneveld A. A study on the pathogenesis of equine sesamoiditis: the effects of experimental occlusion of the sesamoid artery. *J Vet Med A Physiol Pathol Clin Med.* 2002;49(5):244-50.
- Furniss C, Carstens A, van den Berg SS. Radiographic changes in Thoroughbred yearlings in South Africa. *J S Afr Vet Assoc.* 2011;82(4):194-204.
- Gaschen L, Burba DJ. Musculoskeletal injury in thoroughbred racehorses: correlation of findings using multiple imaging modalities. *Vet Clin North Am Equine Pract.* 2012;28(3):539-61.
- Hernandez J, Hawkins DL, Scollay MC. Race-start characteristics and risk of catastrophic musculoskeletal injury in Thoroughbred racehorses. *J Am Vet Med Assoc.* 2001;218(1):83-6.
- Hill AE, Gardner IA, Carpenter TE, Lee CM, Hitchens PL, Stover SM. Prevalence, location and symmetry of noncatastrophic ligamentous suspensory apparatus lesions in California Thoroughbred racehorses, and association of these lesions with catastrophic injuries. *Equine Vet J.* 2016;48(1):27-32.
- Jackson MA, Vizard AL, Anderson GA, Mattoon JS, Lavelle RB, Smithenson BT, et al. An assessment of intra- and interobserver agreement of reporting orthopaedic findings on presale radiographs of Thoroughbred yearlings. *Equine Vet J.* 2014;46(5):567-74.
- Johnson BJ, Stover SM, Daft BM, Kinde H, Read DH, Barr BC, et al. Causes of death in racehorses over a 2 year period. *Equine Vet J.* 1994;26(4):327-30.
- Lima RAS, Shiota R, Barros GSC. Estudo do complexo do agronegócio cavalo. Piracicaba: CEPEA/ESALQ/USP; 2006. 251 p.
- Kane AJ, Park RD, McIlwraith CW, Rantanen NW, Morehead JP, Bramlage LR. Radiographic changes in Thoroughbred yearlings. Part 1: Prevalence at the time of the yearling sales. *Equine Vet J.* 2003;35(4):354-65.
- Meagher DM, Bromberek JL, Meagher DT, Gardner IA, Puchalski SM, Stover SM. Prevalence of abnormal radiographic findings in 2-year-old Thoroughbreds at in-training sales and associations with racing performance. *J Am Vet Med Assoc.* 2013;242(7):969-76.
- Menarim BC, Machado VMV, Alvarez LEC, Carneiro R, Busch L, Vulcano LC. Radiographic abnormalities in barrel racing horses with lameness referable to the metacarpophalangeal joint. *J Equine Vet Sci.* 2012;32(4):216-21.
- Michelotto Jr PV, Ramos CMG, Leite SC, Ribas NJBN, Lunelli D, Prado AMB. Avaliação do desempenho de cavalos Puro Sangue Inglês de corrida após cirurgia artroscópica de articulações carpianas. *Rev Acad Cienc Agrar Ambient.* 2012;10(1):57-64.
- Miyakoshi D, Senba H, Shikichi M, Maeda M, Shibata R, Misumi K. A retrospective study of radiographic abnormalities in the repositories of 2-year-old Thoroughbred in-training sales in Japan. *J Equine Sci.* 2016;27(2):67-76.
- Peloso JG, Mundy GD, Cohen ND. Prevalence of, and factors associated with, musculoskeletal racing injuries of Thoroughbreds. *J Am Vet Med Assoc.* 1994;204(4):620-6.
- Peloso JG, Vogler JB 3rd, Cohen ND, Marquis P, Hilt L. Association of catastrophic biaxial fracture of the proximal sesamoid bones with bony changes of the metacarpophalangeal joint identified by standing magnetic resonance imaging in cadaveric forelimbs of Thoroughbred racehorses. *J Am Vet Med Assoc.* 2015;246(6):661-73.
- Plevin S, McLellan J. The effect of insertional suspensory branch desmitis on racing performance in juvenile Thoroughbred racehorses. *Equine Vet J.* 2014;46(4):451-7.



Plevin S, McLellan J, O'Keeffe T. Association between sesamoiditis, subclinical ultrasonographic suspensory ligament branch change and subsequent clinical injury in yearling Thoroughbreds. *Equine Vet J.* 2016;48(5):543-7.

Preston SA, Brown MP, Trumble TN, Chmielewski TL, Zimmer DN, Hernandez JA. Effects of various presale radiographic findings for yearling Thoroughbreds on 2-year-old racing performance. *J Am Vet Med Assoc.* 2012;241(11):1505-13.

Richardson DW, Dyson SJ. The metacarpophalangeal joint. In: Ross MW, Dyson SJ, editors. *Diagnosis and Management of Lameness in the Horse.* 2nd ed. Saint Louis: W.B. Saunders; 2011. p. 394-410.

Spike-Pierce DL, Bramlage LR. Correlation of racing performance with radiographic changes in the proximal sesamoid bones of 487 Thoroughbred yearlings. *Equine Vet J.* 2003; 35(4):350-3.

Stover SM. The epidemiology of Thoroughbred racehorse injuries. *Clin Tech Equine Pract.* 2003;2(4):312-22.

Wang, D, Shi L, Griffith JF, Qin L, Yew DTW, Riggs CM. Comprehensive surface-based morphometry reveals the association of fracture risk and bone geometry. *J Orthop Res.* 2012;30(8):1277-84.