



The use of a hydrocolloid dressing in the facial wound healing process of a horse - case report

Uso de curativo hidrocolóide (Curatec®) no processo cicatricial de equinos - relato de caso

Vanessa Barroco^[a], Hanna Caroline Prochno^[a], Tânia Mara Becher Ribas^[a], Giuliana Gelbcke Kasecker Botelho^[b], Liane Ziliotto^[b], André Escobar^[b], Karen Regina Lemos^[b]

^[a] Veterinary Medicine students, Universidade Estadual do Centro Oeste do Paraná (UNICENTRO), Guarapuava, PR, Brazil, e-mails: barrocov@gmail.com, hannaprochno@yahoo.com.br, taniamarabecherribas@hotmail.com

^[b] Veterinary professors, Universidade Estadual do Centro Oeste do Paraná (UNICENTRO), Guarapuava, PR, Brazil, e-mails: giuliana@unicentro.br, lianeziliotto@yahoo.com.br, aescobarvet@yahoo.com.br, klemos@unicentro.br

Abstract

Hydrocolloid dressing is a bioactive product used to improve the healing process of large open wounds. In March 2011, a horse was evaluated at the Veterinary Medical Teaching Hospital- UNICENTRO, Guarapuava, Brazil. The animal presented with epistaxis and inspiratory dyspnoea associated with fracture of the orbital part of the frontal bone with a comminuted fracture of the zygomatic process and bone loss of the articular tubercle of the temporal bone reaching the zygomatic process, tooth fracture and a partial laceration of the left cheek with avulsion of the eyeball. After the reconstructive facial surgery and enucleation, we used a hydrocolloid dressing for the repair phase. The dressing helped re-establish the epithelial layer, avoid excessive granulation tissue formation and decrease the healing time. Seven days after surgery and the application of biological membrane, we verified the production of intense and controlled granulation tissue. We concluded that the hydrocolloid was a viable and cost effective alternative.

Keywords: Wound Healing. Curative. Equine.

Resumo

Curativos hidrocolóides são produtos bioativos utilizados para melhorar o processo de cicatrização de grandes feridas abertas. Em março de 2011, um cavalo foi atendido na Clínica Escola Veterinária da UNICENTRO. O animal apresentou epistaxe e dispnéia inspiratória, associado à fratura da parte orbital do osso frontal e fratura cominutiva do processo e osso zigomático, perda do tubérculo articular do osso temporal, fratura de dentes e laceração parcial da face esquerda com avulsão do globo ocular. Após a cirurgia de reconstrução facial e enucleação, foi utilizado o curativo hidrocolóide durante a fase de reparação. A membrana auxiliou no restabelecimento da camada epitelial, evitando a formação de tecido de granulação excessivo e diminuindo o

tempo de cicatrização. Sete dias após a cirurgia e com o uso da membrana biológica, verificou-se a produção de tecido de granulação intenso e controlado. A membrana foi uma alternativa viável e de custo moderado.

Palavras-chave: Cicatrização. Curativo. Equinos.

Introduction

The purpose of the wound healing process is to re-establish the epithelial layer and tissue integrity with strength and functionality (Theoret, 2008). This process in horses is often hampered by excessive granulation tissue formation during the proliferative phase (Krorshid, 2005). The epithelial layer provides the tissue with primary defenses and maintenance of homeostasis, thus limiting the loss of fluids and electrolytes through the skin (Theoret, 2008). In horses, many wounds progress to second intention healing due to massive tissue loss, contamination and an excess of skin contraction resulting in an unacceptable scar appearance (Theoret, 2004). Instability between synthesis and degradation of collagen during the remodeling phase may be correlated with the development of excessive granulation tissue in equine limb wounds (Schwartz et al., 2002).

Adherent and non-adherent wound dressings that contribute to the wound healing process are widely commercialised, although one single product hardly produces the ideal microenvironment for all stages of wound recovery. It is therefore important to know the healing phases as well as conditions, location and depth of the wound (Stashak, 2008). Silicone gel patches have been tested, and it is known that they help control excessive granulation tissue formation in equine limbs and hypertrophic wounds in humans, improving the quality of the healing process when compared to conventional methods. Biological curatives were tested and did not demonstrate any advantage over non-adherent synthetic pads, with no positive effects on healing time, infection control and inflammatory response, and there was also the need for daily changes (Gomez et al., 2004). Equine pericardial tissue tends to favour granulation but a single application for long periods is not recommended in exuding wounds

(Bellenzani et al., 1994). Hydrocolloid dressings (Elasto-gel®) are used to minimise the need for debridement and maximise tissue strength in addition to facilitating the management of treatment with less interventions and curatives (Mulder and Lee, 2009). However, hydrocolloid dressings should only be used on clean wounds and at the initial inflammatory phase to promote granulation tissue formation on injured bones and tendons (Stashak, 2008). Hydrocolloid dressings are considered hydroactive since they are able to absorb large quantities of fluids (Shaw and Longhofer, 1999). Duoderm® is a traditional hydrocolloid dressing on the market and is supposed to promote a high index of epithelialisation and collagen synthesis while decreasing the pH of wound exudate which leads to a reduction in the bacterial count (Stashak, 2008).

The aim of this study was to analyse the efficacy of the hydrocolloid dressing in the process of facial wound repair and found it to be helpful in achieving cosmetic results in wounds healing by second intention.

Material and methods

In March 2011, a mixed-breed female horse was evaluated at the Veterinary Medical Teaching Hospital - UNICENTRO, Guarapuava, Brazil. It was about eight months old and had a history of collision with a truck on a road near the city. The clinical examination demonstrated that its wounds were mostly restricted to the face, and there was a discrete swelling on the left forelimb with a light lameness but no serious bone or muscle damage. The animal presented with epistaxis, severe facial edema and inspiratory dyspnea associated with fractures of several face bones. There was a fracture of the orbital part of the frontal bone associated with a comminuted fracture of the zygomatic

process and bone loss of the articular tubercle of the temporal bone reaching the zygomatic process. Radiographic analysis with an X-ray PXP 40 HF unit (Poskom) in lateral and rostro-caudal projections of the facial areas identified a complete simple fracture of the base of the temporal process of the zygomatic arch with loss of this bone tissue along with the articular tubercle of the temporal bone (nasal bones, supraorbital process, zygomatic bone, orbit), tooth fracture and a partial laceration of the left cheek with avulsion of the eyeball (Figure 1). Sedation was not needed. Six 10x10 cm hydrocolloid dressings were used, with a total cost of US\$ 26.00 and the hospital charges were US\$ 200.00. Image J™ software was used to assess the evolution of healing process.

Results and discussion

Preliminary examination suggested the need for reconstructive facial surgery and enucleation. Upon further physical examination and complete blood count and chemistry analysis, we elected not to perform general anesthesia as the animal was anemic and lateral recumbency was used to prevent respiratory tract edema. After administration of ketoprofen (2.2 mg/kg IV) the lesions were evaluated, the wound was cleaned with 0.9% saline solution and a solution of calendula (*Calendula officinalis*), and visible bone fragments were removed.

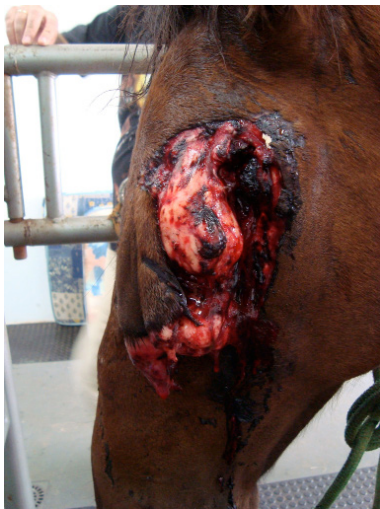

Figure 1 - Horse showing severe facial edema and a partial laceration of the left cheek with eyeball contour.

We administered a combination of detomidine (20 µg/kg) and butorphanol (0.03 mg/kg) intravenously. Five minutes after administration, local anesthesia was performed with lidocaine 2% without a vasoconstrictor on subcutaneous and muscular tissues on the left side of the face and at the retrobulbar nerve area. Additional doses of detomidine (10 µg/kg) were administered as needed for physical restraint and analgesia. The supraorbital portion was stabilised with sutures, various bone fragments were removed, but due to a significant loss of tissue, complete primary closure was not possible (Figure 2), and auxiliary procedures were required for second intention healing of the wound, which had a size of approximately 33cm. In the postoperative period, a calendula-based cleaning solution and hydrocolloid dressings (Curatec® - LMFarma, São José dos Campos, Brazil) (Figure 3) were used.

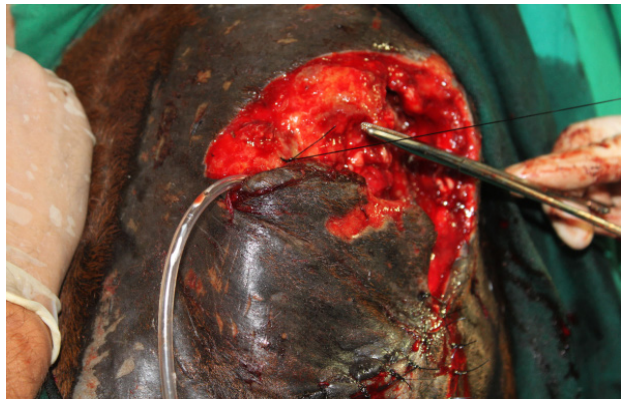


Figure 2 - The significant loss of tissue prevented a complete primary closure. A surgical drain allowed the fluids to flow out.

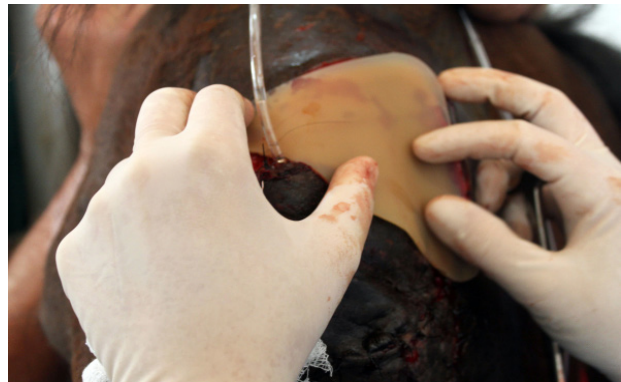

Figure 3 - Hydrocolloid dressing (Curatec™) use after cleaning. Perimeter of the surgical wound was 33 cm.

A significant healing response was noted, as the wound perimeter was reduced from 33 cm to 29 cm after seven-days of membrane use (Figure 4). Thirteen days after the surgery, bony microfragments were still present and were removed from the wound bed (Figure 5). After 51 days of postoperative care and hydrocolloid membrane use, the wound had a normal epithelial covering and was completely healed (Figure 6).

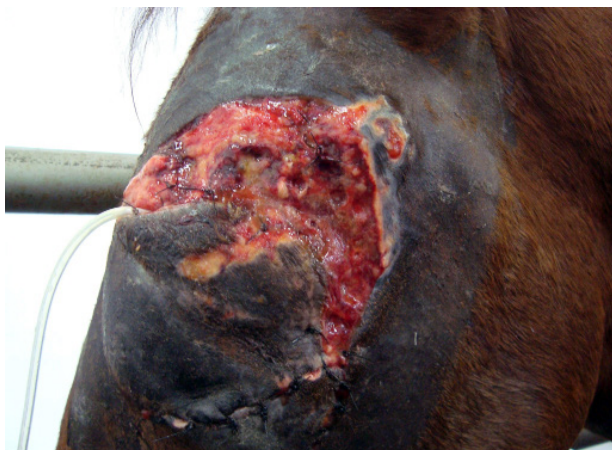

Figure 4 - Significant healing response after seven days of membrane use. Formation of granulation tissue without significant reduction of wound bed is observed. The perimeter wound site was 29 cm.

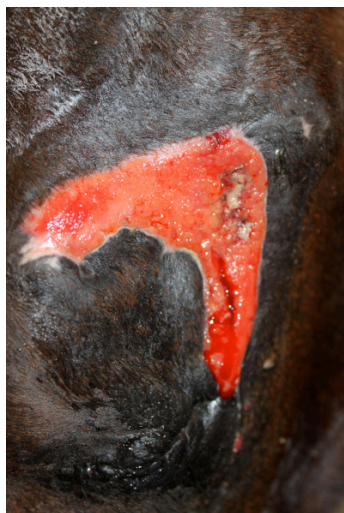

Figure 5 - Thirteen-days after the surgery. Perimeter of the surgical wound was 18 cm and a significant reduction of the wound site.

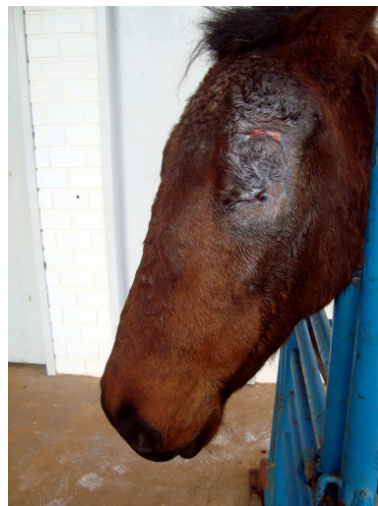

Figure 6 - Fifty-one days of postoperative and hydrocolloid membrane use. Normal epithelial cover and nearly complete wound healing and a wound perimeter of 1cm were observed.

The wound was not infected during the entire acute inflammation and cellular proliferation phase. However, 41 days after surgery the wound had a minor fluid secretion. We proceeded to clean the wound with a 1:1000 calendula solution and applied a new hydrocolloid dressing on the 42nd day. The inability to stabilise the frontal and maxillary sinuses bones in addition to the loss of the lacrimal duct induced a sinusitis in the horse, which we believe led to the local infection.

The horse was able to adapt to partial blindness with no anxiety crisis nor aggressiveness towards the nursing staff, which performed their activities calmly and talked to the patient to let it know where they were standing.

Facial bone fractures frequently occur in horses and are a clinical challenge due to the anatomical structure of the region. The most commonly fractured bones are the nasal, maxillary, frontal and zygomatic bones because these structures are relatively thin and only partially covered by muscles (Barber and Stashak, 2008). In addition, maxillofacial fractures predominate in rodeos, compared with fractures of the medial portion of the face (Mulder and Lee, 2009). Given these facts, the facial damage sustained by the horse of this report was less extensive than expected given the severity of accident, since nerve structures such as

the facial nerve were not affected and there was no facial paralysis.

Reconstructive surgery was needed, due to the extent wound. It was not possible to keep the eyeball, neither the facial contour. However, as the animal was a workhorse did not participate in fairs or competitions the aesthetic appearance had not an essential consideration.

Radiographs were an important part of fracture evaluation, but the full extent of the head fractures were difficult to visualise due to the complexity of the bone structures of the head (Barber and Stashak, 2008). In this case, various fractures and bone fragments were found during surgery.

The hydrocolloid dressings are considered costly, which restricts their use. However, when one considers the costs associated with hospital staff, veterinarians and time spent on dressings, they become a viable alternative. In the present case, the overall treatment amounted to US\$ 356.00, which can be considered reasonable.

Hydrocolloid dressings are indicated for use in the inflammatory phase and on clean wounds (Stashak, 2008), so our patient fits into the recommended profile, despite the intense regional trauma and bone loss, especially on the zygomatic bone.

Wound infections in equines are polymicrobial, and such pathogens are more prevalent in chronic wounds (Westgate et al., 2010). In this case, the wound was not contaminated, consistent with the lower prevalence of contamination in acute wounds. We believe that the use of the calendula cleaning solution in the treatment of our patient was important in the healing process by preventing infection. Studies demonstrate the antimicrobial activity of this plant extract, particularly against gram positive bacteria (Volpato, 2005), and it has been routinely used in horses at the Veterinary Medical Teaching Hospital - UNICENTRO.

Hydrocolloid dressings externally used permeable polyurethane membranes with a thin adhesive and absorbent interface of hydrocolloid. They create a desirable environment between the membrane and the surface of the wound that promotes the development of moist conditions, which in turn optimise the healing process and facilitates the dressing replacement without

damaging the newly formed tissue. The membrane allowed intense but controlled granulation tissue production, little contraction though. The evaluation of different dressings for equine wounds showed that only the semi-occlusive dressing Telfa® had an average healing time similar to the equine of this case (53 to 77 days) (Stashak et al., 2004).

Conclusion

Bioactive healing products, adherent or non-adherent, are commercially available and widely used. They act at different stages of the healing process and contain antimicrobials or antiseptics, which suppress bacterial growth. The development of new products that promote successful therapeutic treatment of equine wounds are extremely welcome, since the management of acute wounds and an immediate and effective intervention can be critical for horses. Our use of a biological membrane contributed to the production of intense and controlled granulation tissue, showing that the hydrocolloid dressing under study is a viable and cost effective alternative for the treatment of a facial wound.

References

- Barber S, Stashak TS. Management of Wounds of the Head. In: Stashak TS, Theoret CL. Equine wound management. 2nd ed. Iowa: Wiley-Blackwell; 2008. p. 273-332.
- Bellenzani MCR, Matera JM, Giacóia MR. Homologous pericardium as a biological dressing for treatment of distal limb wounds in horses - an experimental study. *Acta Cir Bras.* 1994;13(4):237-41.
- Gomez JH, Schumacher J, Lauten SD, Sartin EA, Hathcock TL, Swaim SF. Effects of 3 biological dressings on healing of cutaneous wounds on the limbs of horses. *Can J Vet Res.* 2004;68(1):49-55.
- Krorshid FA. Comparative study of keloid formation in humans and laboratory animals. *Med Sci Monit.* 2005;11(7):BR212-9.

Mulder G, Lee DK. Use of equine derived pericardium as a biological cover to promote closure of a complicated wound with associated scleroderma and Raynaud's disease. *Wounds*. 2009;21(11):297-301.

Schwartz AJ, Wilson DA, Keegan KG, Ganjam VK, Sun Y, Weber KT, et al. Factors regulating collagen synthesis and degradation during second-intention healing of wounds in the thoracic region and the distal aspect of the forelimb of horses. *Am J Vet Res*. 2002;63(11):1564-70.

Shaw M, Longhofer K. The use of elasto-gel TM on equine wounds. *J Equine Vet Sci*. 1999;19(6):374-81,408.

Stashak TS, Farstvedt E, Othic A. Update on wound dressings: Indications and best use. *Clin Tech Equine Pract*. 2004;3(2):148-63.

Stashak TS. Management Practices That Influence Wound Infection and Healing. In: Stashak TS, Theoret CL. *Equine Wound Management*. 2nd ed. Iowa: Wiley-Blackwell; 2008. p. 85-106.

Theoret CL. Update on Wound Repair. *Clin Tech Equine Pract*. 2004;3(2):110-22.

Theoret CL. Physiology of Wound Healing. In: Stashak TS, Theoret CL. *Equine Wound Management*. 2nd ed. Iowa: Wiley-Blackwell; 2008. p. 3-68.

Volpato AMM. Avaliação do potencial antibacteriano da *Calendula officinalis* (Asteracea) para seu emprego como fitoterápico [dissertation]. Curitiba: Universidade Federal do Paraná; 2005.

Westgate SJ, Percival SL, Knottenbelt DC, Clegg PD, Cochrane CA. Chronic equine wounds: what's the role of infection and biofilms? *Wounds*. 2010;22(6):138-45.

Received in: 09/29/2016

Recebido em: 29/09/2016

Approved in: 11/30/2016

Aprovado em: 30/11/2016